

A drug-induced microscopic colitis in an older woman: a case report

Irene Mattioli¹, Francesca Remelli¹, Mattia Brunori², Chiara Delli Gatti², Amedeo Zurlo^{1,2}, Stefano Volpato^{1,2}

¹ Department of Medical Science, University of Ferrara, Ferrara, Italy; ² Geriatrics and Orthogeriatrics Unit, Azienda Ospedaliero-Universitaria of Ferrara, Italy

We presented a case of a 87-year-old woman hospitalized for chronic watery diarrhea, affected by multimorbidities. After excluding other causes of diarrhea by biohumoral and microbiological tests, endoscopy was performed without revealing any macroscopic abnormalities, but, at histological examination of random biopsies, the characteristic features of collagenous colitis were found. Lansoprazolo and sertraline, chronically taken by the patient, was discontinued, and budesonide was started with prompt clinical improvement.

Collagenous colitis is a rare cause of chronic diarrhea in advanced age, but it should be suspected in patients with polypharmacotherapy, after an accurate differential diagnosis.

Key words: chronic diarrhea, polypharmacy, elderly

INTRODUCTION

Collagenous colitis, a subtype of microscopic colitis, is a relatively rare chronic disease of the colon. Its estimated incidence is 2.0 per 100,000 per year¹ and affects predominantly women (about 52-86% of cases). Pathogenesis is not completely clear and it is likely multifactorial. It is characterized by normal macroscopic picture during endoscopy, so colic biopsy is essential to make a definite diagnosis².

We here report the case of an 87-year-old woman admitted to the hospital for persisting watery diarrhea. The pathological examination was apparent normal, but the colic biopsy revealed the diagnosis.

CASE REPORT

An 87-year-old woman was admitted to Geriatrics Unit with watery diarrhea (over ten episodes per day) lasting about a month without abdominal pain, vomiting or fever. She started to take some symptomatic drugs at home with poor benefit. The patient did not smoke; she did not recently travel to other countries or reported any changes of her eating habits, neither introduced new medications. The patient was chronically affected by major cognitive disorder, depression, hypertensive heart disease, moderate aortic stenosis, paroxysmal atrial fibrillation, HCV-related liver disease, chronic renal failure (stage III), erosive gastritis secondary to Non-Steroidal Anti-Inflammatory Drugs (NSAIDs) chronic use. After her last hospitalization for acute gastritis, she started Proton Pump Inhibitors (PPIs) therapy with lansoprazole. She was also chronically

Received: July 16, 2022
Published: September 30, 2022

Correspondence

Francesca Remelli

Department of Medical Science, University of Ferrara, via A. Moro 8, 44124, Ferrara, Italy. Tel.: +39 0532 239572. E-mail: rmlfnc1@unife.it

How to cite this article: Mattioli I, Remelli F, Brunori M, et al. A drug-induced microscopic colitis in an older woman: a case report. *Journal of Gerontology and Geriatrics* 2022;70:300-305. <https://doi.org/10.36150/2499-6564-N564>

© Copyright by Società Italiana di Gerontologia e Geriatria (SIGG)



OPEN ACCESS

This is an open access article distributed in accordance with the CC-BY-NC-ND (Creative Commons Attribution-NonCommercial-NoDerivatives 4.0 International) license. The article can be used by giving appropriate credit and mentioning the license, but only for non-commercial purposes and only in the original version. For further information: <https://creativecommons.org/licenses/by-nc-nd/4.0/deed.en>

taking sertraline for depression. The patient lived with her daughter and was partially dependent in basic and instrumental activities of daily living.

On admission, at clinical examination she appeared alert, partially oriented, in stable hemodynamic compensation. The patient reported abdominal distension without any signs of peritonitis. The skin and oral mucous were hypohydrated. The vital signs were normal.

On blood tests, a modest increase in serum creatinine values (1.3 mg/dl) was observed; hemoglobin, inflammatory markers (white blood cells and C-Reactive protein) and serum electrolytes were normal. Abdominal X-Ray revealed a diffuse and modest distension of intestinal loops, mainly colon and tenuous, with diffuse air fluid levels (Fig. 1a). Intravenous rehydration therapy was timely started.

During the hospitalization, the patient continued to present multiple episodes of diarrhea daily, so further diagnostic investigations were conducted. The chemical and physical examinations of the stool were normal, as well as the serum levels of lipase, liver enzymes, total proteins and thyroid hormones. Microbiological tests (*Yersinia*, *Salmonella*, *Shigella*, *Campylobacter*, *Clostridium difficile*, parasitological, *Widal-Wright reaction*) were negative. Celiac disease screening was also negative. Blood levels of faecal calprotectin were markedly elevated.

Abdominal Computer Tomography (CT) confirmed the presence of colic distension with minimal parietal

hyperemia (Fig. 1b). In the hypothesis of chronic colic inflammation, empiric therapy with mesalazine associated with lactic ferments and rifaximin was started, with only modest clinical improvement. A colonoscopy was performed, without revealing any macroscopic abnormalities (Fig. 1c); nevertheless, random biopsies were performed in the ascending colon, sigma and rectum. Histological examination revealed the presence of focal de-epithelialized colic mucosa with hyperplastic crypts, moderate lymphoplasmacellular infiltrate of the lamina propria with eosinophilic component in the ascending colon and in the sigma extended to the *muscularis mucosae*, and a moderate increase in the subepithelial collagen band. This finding was compatible with collagenic colitis.

Therefore, oral steroid therapy with budesonide was undertaken, replacing mesalazine, at a dosage of 9 mg per day for 6 weeks, followed by progressive recovery of the patient in 10 days. Moreover, the therapy with PPIs and Selective Serotonin Reuptake Inhibitors (SSRIs) was gradually discontinued.

The patient was discharged at home after three weeks months.

DISCUSSION

We reported a clinical case of an older woman with

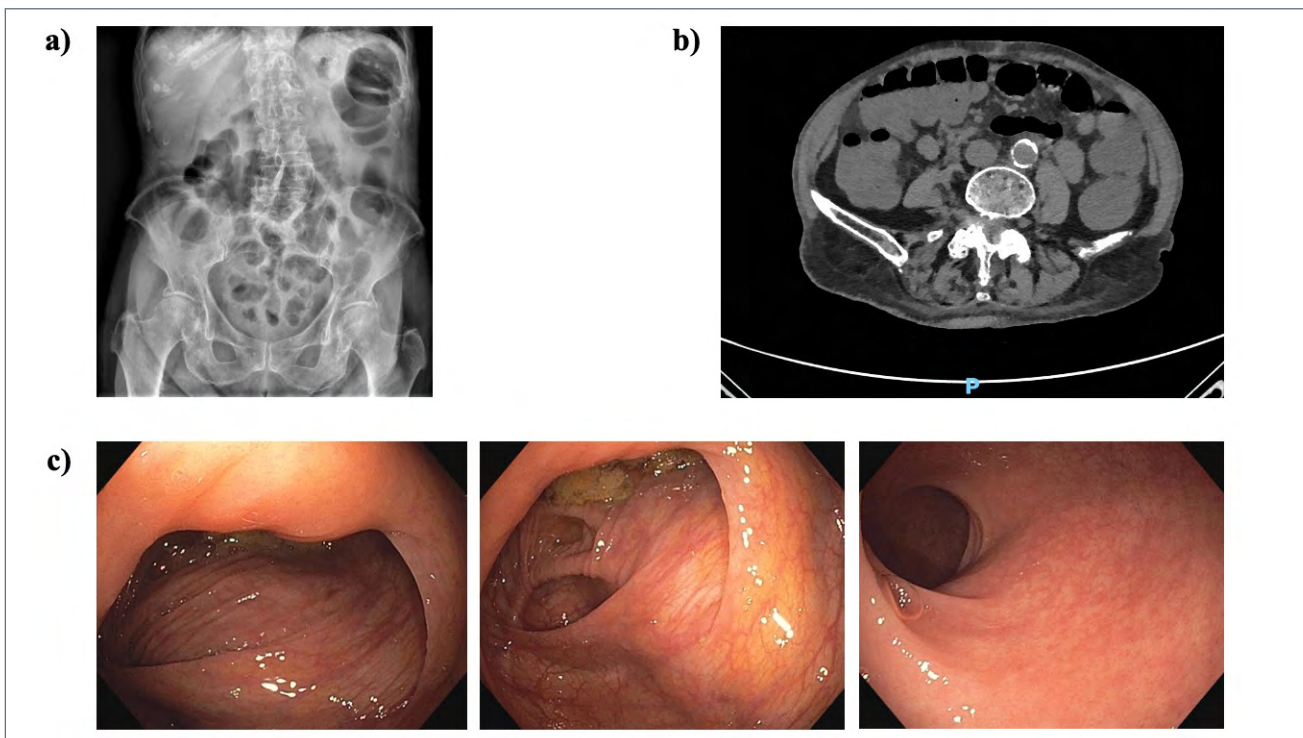


Figure 1. Abdominal X-Ray (A), CT scan (B) and colonoscopy (C).

collagenous colitis, presenting with chronic watery diarrhea. The diagnosis was extremely challenging, because of the advanced age of the patient, not typical for collagenous colitis' onset, and the lack of other major risk factors besides PPIs and SSRIs use. Indeed, she did not report either any autoimmune diseases nor smoking habit.

Collagenous colitis is a subtype of microscopic colitis. It is a relatively rare chronic colic disease with an estimated incidence of 2.0 per 100,000 per year¹. Unlike our case, it is typically diagnosed in middle-aged patients with a preponderance of female sex (about 52-86% of cases). The pathogenesis is still unclear, but it is likely multifactorial and involves mucosal immune response to luminal factors in genetically predisposed individuals. Indeed, diarrhea is likely caused by mucosal inflammation and its severity correlates with colic inflammation rather than with collagen band thickening.

Several autoimmune diseases have been associated with microscopic colitis, such as autoimmune thyroiditis, type 1 diabetes mellitus, and oligoarticular arthritis and an abnormal collagen metabolism seems to be responsible for the collagen deposition³.

Some medications have been also implicated as being causative flares, particularly PPIs, specifically lansoprazole, SSRIs and statins (the first two both taken by our patient)⁴. Even smoke seems to play a role in collagenous colitis' pathogenesis, but it was not present in the present case.

Our patient reported the classical clinical presentation of the microscopic colitis. Indeed, it is characterized by chronic, non-bloody, watery diarrhea with usually an insidious onset. Patients have from four to nine watery stools per day, fecal urgency (70% of cases), incontinence (40%), abdominal pain (50%)¹. Differential diagnosis includes celiac disease, inflammatory bowel disease, and irritable bowel syndrome. Laboratory findings are generally nonspecific, like in our patient, and fecal calprotectin seems not be a specific marker of active microscopic colitis¹. Moreover, tests should exclude *Clostridium difficile*, *Salmonella spp*, *Shigella spp*, *Campylobacter spp*, *Yersinia spp*, and parasites (as *Giardia lamblia*) infections, executed also in the present clinical case and resulted negative. Like in our patient, the endoscopic macroscopic aspect of the colon is typically normal (Fig. 1c), while microscopically it is characterized by a subepithelial collagen band, more evident between the crypts.

Treatments include antidiarrheal agents and budesonide, a local active corticosteroid, for at least 6-8 weeks even if symptomatic improvement could be seen in few days⁵; budesonide was also performed in our patient with the completed resolution of the diarrhea. Other options are cholestyramine, bismuth subsalicylate, biologic agents

and immunomodulators. As observed, aminosalicylates, such as mesalazine, appear not to be effective⁵. Patients should avoid, if possible, every medications associated with microscopic colitis. In our case, given the resolution of gastritis, after a period of lansoprazole, and the improvement of depressive symptoms, both PPIs and SSRIs were gradually interrupted.

Patients with an inadequate response to the pharmacological treatment (or the discontinuation of high-risk medications) should be re-evaluated for other causes of diarrhea (i.e. celiac disease, hyperthyroidism, carcinoid syndrome, VIPoma).

Comparing our clinical case to others similar available in literature, we identified 10 case reports⁶⁻¹⁵, presented in Table I. Unlike most examined clinical cases, that described the onset of microscopic colitis in adulthood^{7-11,15} or in younger elderly^{6,12-14}, our patient presented an atypical age of disease's onset (late onset). Moreover, our case has the peculiarity that the disease was caused by the contemporary taken of two high-risk medications (e.g. lansoprazole and sertraline), without any other known risk factors, such as the presence of smoking habit or autoimmune diseases^{6,7,13}. In addition, based on the identified case reports' examination⁶⁻¹⁵, the symptoms of microscopic colitis arose after a few weeks after the beginning of the new therapy, in particular with antidepressants (i.e. duloxetine and sertraline), or PPIs (i.e. lansoprazole), or NSAIDs. Similarly, in our clinical case, the characteristic watery diarrhea started a few weeks after the introduction of lansoprazole, while the symptom resolution was observed only following the contemporary discontinuation of both PPIs and sertraline, chronically taken by the patient, in addition to the administration of budesonide.

Finally, according to the literature⁴, our case supports the close association between microscopic colitis and specific medications (e.g. lansoprazole and sertraline) and, unlike the other case reports already described, the disease's onset in the *oldest-old age* is peculiar of our patient. However, the problem of polypharmacy (that often including the PPIs and SSRIs use) is extremely widespread in older population, exposing this class of patients to a consequent higher risk of microscopic colitis, which might be underdiagnosed.

In conclusions, we reported a case of an older woman with collagenous colitis, who presented only medications intake (PPIs and SSRIs) as disease known risk factors.

Microscopic colitis should be suspected in a patient with chronic watery diarrhea, particularly in middle-aged women, but also in older women presenting multiple high-risk factors (i.e. smoking habit, medications, autoimmune diseases), after an accurate differential diagnosis. Indeed, a careful evaluation of pharmacological

Table I. Comparison of identified case reports of collagenous colitis.

Author, year	Clinical presentation	Age, gender	Main comorbidities
Konijeti et al., 2013 ⁶	Watery brown diarrhea, dehydration	80 y, male	Henoch-Schonlein Purpura requiring partial jejunal resection, coronary artery disease, CKD, gout, GERD, prior cholecystectomy
Salter et al., 2017 ⁷	Watery diarrhea, weight loss, abdominal pain and bloating, nausea	50 y, female	Smoking habit, major depression
Menon et al., 2015 ⁸	Watery diarrhea, weight loss	63 y, male	Major depression
Rammer et al., 2005 ⁹	Watery diarrhea	57 y, male	Erosive gastritis HP+
Pelizza et al., 2007 ¹⁰	Watery diarrhea, weight loss, abdominal pain, fecal incontinence, fever	37 y, male	Paranoid schizophrenia
Hawe et al., 2008 ¹¹	Watery diarrhea, dehydration	62 y, female	Bipolar disorder
Chande et al., 2007 ¹²	Watery diarrhea, weight loss	78 y, female	GERD
	Watery diarrhea	65 y, female	NSAIDs-related gastritis
Bahin et al., 2013 ¹³	Watery diarrhea, weight loss	75 y, female	GERD, IBD, arterial hypertension, hypercholesterolemia
Arora et al., 1999 ¹⁴	Abdominal pain, dyspepsia, rectorrhagia	79 y, male	Duodenal ulcer, ischemic stroke, aortic stenosis, arterial hypertension, glaucoma, prostate cancer
Castellano et al., 1999 ¹⁵	Watery diarrhea weight loss, anorexia	57 y, female	Non-specific articular pains

Note. CKD: Chronic Kidney Disease; GERD: Gastroesophageal Reflux Disease; CT: Computed Tomography; HP+: *Helicobacter pylori* positive; IBD: Inflammatory Bowel Disease; NSAIDs: Non-Steroidal Anti-Inflammatory Drugs

history can increase the clinical suspicion of the disease, especially in elderly patient who is frequently subjected to polypharmacotherapy, of which should always be considered the potential adverse effects. A close collaboration among geriatrician, endoscopist and pathologist is required to obtain a correct diagnosis and consequent timely treatment of this disease.

ACKNOWLEDGEMENTS

Open access funding provided by Università degli Studi di Ferrara within the CRUI-CARE Agreement.

CONFLICT OF INTEREST

The Authors declare no conflict of interest.

FUNDING

This research did not receive any specific grant from funding agencies in the public, commercial, or not-for-profit sectors.

AUTHOR CONTRIBUTIONS

M, FR, MB, CDG, AZ, SV: conceptualization; IM, FR, MB, CDG: writing-original draft preparation; AZ, SV: writing-review and editing.

ETHICAL CONSIDERATION

Written consent was obtained from the participant. The data used in this study were anonymized before its use.

	Imaging	Histological examination	High-risk medications	Treatment	Outcome
	Abdominal CT scan, gastroscopy, colonoscopy	Collagenous colitis (thickened subepithelial collagen layer); lymphocytic colitis (sloughing of the surface epithelium and intraepithelial lymphocytes)	Lansoprazole	Balsalazide + prednisone	Resolution in 6 weeks
	Colonoscopy	Lymphocytic colitis	Duloxetine	Budesonide + duloxetine discontinuation	Resolution in 8 months
	Abdomen CT scan, colonoscopy	Lymphocytic colitis (increased intraepithelial lymphocytes)	Sertraline	Sertraline discontinuation	Resolution in 2 weeks
	Colonoscopy	Collagenous colitis (intraepithelial lymphocytes and thickening of the subepithelial collagen)	Lansoprazole	Lansoprazole discontinuation	Resolution in 4 days
	Abdominal X-Ray, colonoscopy	Lymphocytic colitis (intraepithelial lymphocytosis, mixed inflammatory infiltrate in the lamina propria, focal surface epithelial damage)	Clozapine	Clozapine discontinuation	Resolution in few days
	Abdominal X-Ray and CT scan, colonoscopy	Moderate mixed inflammatory cell infiltrate in the lamina propria, cryptitis and crypt abscesses	Clozapine	Clozapine discontinuation	Resolution in 8 days
	Colonoscopy	Collagenous colitis (increased number of plasma cells in the mucosa, a thickened subepithelial collagen band and degenerate surface epithelium)	Lansoprazole	Lansoprazole discontinuation	Resolution in 2 weeks
	Colonoscopy	Collagenous colitis	Lansoprazole	Lansoprazole discontinuation	Resolution in 4 weeks
	Colonoscopy	Mixed pattern of collagenous colitis and lymphocytic colitis (subepithelial collagen plate prominent, epithelium degeneration, intraepithelial lymphocytes and other inflammatory cells, in the mucosa and in lamina propria, especially plasma cells)	Duloxetine	Duloxetine discontinuation	Resolution in 2 weeks
	Mesenteric angiography, subtotal colectomy	Lymphocytic colitis (Intraepithelial lymphocytes and thickening of the subepithelial collagen band) Lymphocytic venulitis (perivenular inflammatory cell infiltrate composed of a monomorphic population of small lymphocytes)	No	Colectomy to stop bleeding	Death
	Gastroscopy, colonoscopy	Collagenous colitis and gastrobulbitis (thickened subepithelial collagenous band in the mucosa of the upper digestive tract)	NSAIDs	Prednisone	Resolution

References

- Bohr J, Tysk C, Eriksson S, et al. Collagenous colitis: a retrospective study of clinical presentation and treatment in 163 patients. *Gut* 1996;39:846. <https://doi.org/10.1136/gut.39.6.846>
- Lazenby AJ, Yardley JH, Giardiello FM, et al. Lymphocytic ("microscopic") colitis: a comparative histopathologic study with particular reference to collagenous colitis. *Hum Pathol* 1989;20:18. [https://doi.org/10.1016/0046-8177\(89\)90198-6](https://doi.org/10.1016/0046-8177(89)90198-6)
- Koskela RM, Niemelä SE, Karttunen TJ, et al. Clinical characteristics of collagenous and lymphocytic colitis. *Scand J Gastroenterol* 2004;39:837. <https://doi.org/10.1080/00365520410006468>
- Bonderup OK, Nielsen GL, Dall M, et al. Significant association between the use of different proton pump inhibitors and microscopic colitis: a nationwide Danish case-control study. *Aliment Pharmacol Ther* 2018;48:618. <https://doi.org/10.1111/apt.14916>
- Kafil TS, Nguyen TM, Patton PH, et al. Interventions for treating collagenous colitis. *Cochrane Database Syst Rev* 2017;11:CD003575. <https://doi.org/10.1002/14651858.CD003575.pub6>
- Konijeti GG. An unusual case of chronic diarrhea. *Gastroenterology* 2013;144:696. <https://doi.org/10.1053/j.gastro.2012.11.002>
- Salter TG, Williams MD. Antidepressant-associated microscopic colitis: a case report and literature review. *Psychosomatics* 2017;58:307-312. <https://doi.org/10.1016/j.psych.2017.01.005>

- ⁸ Menon R, Chee Ng. Sertraline-induced microscopic colitis. *Psychosomatics* 2015;56:316-317. <https://doi.org/10.1016/j.psym.2014.03.008>
- ⁹ Rammer M, Kirchgatterer A, Höbling W, et al. Lansoprazole-associated collagenous colitis: a case report. *Z Gastroenterol* 2005;43:657-660. <https://doi.org/10.1055/s-2005-85815>
- ¹⁰ Pelizza L, Melegari M. Clozapine-induced microscopic colitis: a case report and review of the literature. *J Clin Psychopharmacol* 2007;27:571-574. <https://doi.org/10.1097/jcp.0b013e31815a257f>
- ¹¹ Hawe R, Bolton JM. Response to clozapine-induced microscopic colitis: a case report and review of the literature. *J Clin Psychopharmacol* 2008;28:454-455. <https://doi.org/10.1097/JCP.0b013e31817d8725>
- ¹² Chande N, Driman DK. Microscopic colitis associated with lansoprazole report of two cases and a review of the literature. *Scand J Gastroenterol* 2007;42:530-533. <https://doi.org/10.1080/00365520600997296>
- ¹³ Bahin FF, Chu G, Rhodes G. Development of microscopic colitis secondary to duloxetine. *J Clin Gastroenterol* 2013;47:89-90. <https://doi.org/10.1097/MCG.0b013e318266fe92>
- ¹⁴ Arora DS, Mahmood T, Wyatt JL. Lymphocytic venulitis: an unusual association with microscopic colitis. *J Clin Pathol* 1999;52:303. <https://doi.org/10.1136/jcp.52.4.303>
- ¹⁵ Castellano VM, Muñoz MT, Colina F, et al. Collagenous gastrobulbitis and collagenous colitis. Case report and review of the literature. *Scand J Gastroenterol* 1999;34:632-638. <https://doi.org/10.1080/003655299750026128>