



Early class III treatment with hybrid rapid palatal expander combined with facemask

Luca Lombardo, Paolo Albertini, Francesca Cervinara, Luca Brucculeri, Giuseppe Siciliani

Available online: 10 June 2020

University of Ferrara, Postgraduate School of Orthodontics, Ferrara, Italy

Correspondence:

Luca Lombardo, University of Ferrara, via Borsari, 46, 44121 Ferrara, Italy.
dott.lulombardo@gmail.com

Keywords

Class III treatment
Anchorage
Face mask
Orthodontic mini-implant
Hybrid rapid palatal expansion

Summary

Background > Class III patients are characterized by a deficiency of the maxilla and/or a prognathism of the mandible and require early treatment.

Diagnosis > This case report describes the treatment of a 5-year-old patient with a skeletal class III relationship, a significant mandibular symphysis deviation towards the right side and a different height of the mandibular angles.

Management and outcome > The patient was treated with rapid maxillary expander combined with miniscrew, facemask and aligners. A functional and aesthetic occlusion in an improved facial profile was established at the end of the orthodontic treatment. Pre-treatment, post-treatment and one year retention records for the patient are presented.

Discussion > Class III patients require early treatment in order to optimize the traditional expander effects; subsequently hybrid anchorage allowed to maximize skeletal advancement. In addition, loss of space for the erupting teeth and dento-alveolar tipping were avoided. The good results of the phase I treatment and of the active retainer meant that a complex case would become relatively simple at the phase II treatment.

Introduction

Class III patients are characterized by a deficiency of the maxilla and/or a prognathism of the mandible and require early treatment. Facemask therapy was first illustrated in 1885 [1] and from the 1960s, it has become more and more established, ending up to be one of the elective therapies for the correction of class III malocclusions [2-9]. Class III patients frequently present a maxillary skeletal retrusion, a mandibular skeletal protrusion, or a combination of the two positions. These

conditions also often associated with maxillary constriction that is manifested as an anterior or posterior crossbite [6]. Moreover, facemask treatment is often supplemented with maxillary expansion. Orthopaedic expansion was recommended for use in conjunction with protraction of the maxillary because it supposedly disrupts the circummaxillary sutural systems and presumably facilitates the orthopaedic effects of the facemask therapy [10-12]. The advent of innovative techniques through the use of mini-screw in the palate made it possible to solve

even the most complex cases [13]. The aim of this case report was to present the treatment of a class III malocclusion in primary dentition by means of rapid maxillary expander with hybrid anchorage combined with facemask.

Diagnosis and aetiology

The patient presented at 5 years of age with the concern of the parents for the prominent chin. The face, from a frontal view, appeared well-proportioned in the three-thirds; a significant mandibular symphysis deviation towards the right side was highlighted, combined with a different height of the mandibular angles. From a lateral view, the profile appeared flat, a slightly

open nose-labial angle, a marked labiomental sulcus and a protruded mandibular position (*figure 1*).

The orthopantomography pointed out the presence of all the elements. From the latero-lateral telerradiography, a skeletal class III with maxilla in slightly retruded position and mandible in protruded position could be detected. The skeletal pattern resulted hypodivergent (MP-SN: 22.9°). The upper and lower incisors appeared retroclined (U1-PP: 96.3°; IMPA: 70.8°). At frontal intraoral vision the midlines did not appear coincident (slight deviation of the lower towards right), diffused diastemas were noticeable, a crossbite involving all elements (with the exception of 5.4 and 6.4). The lateral photographs showed molar and canine class III.

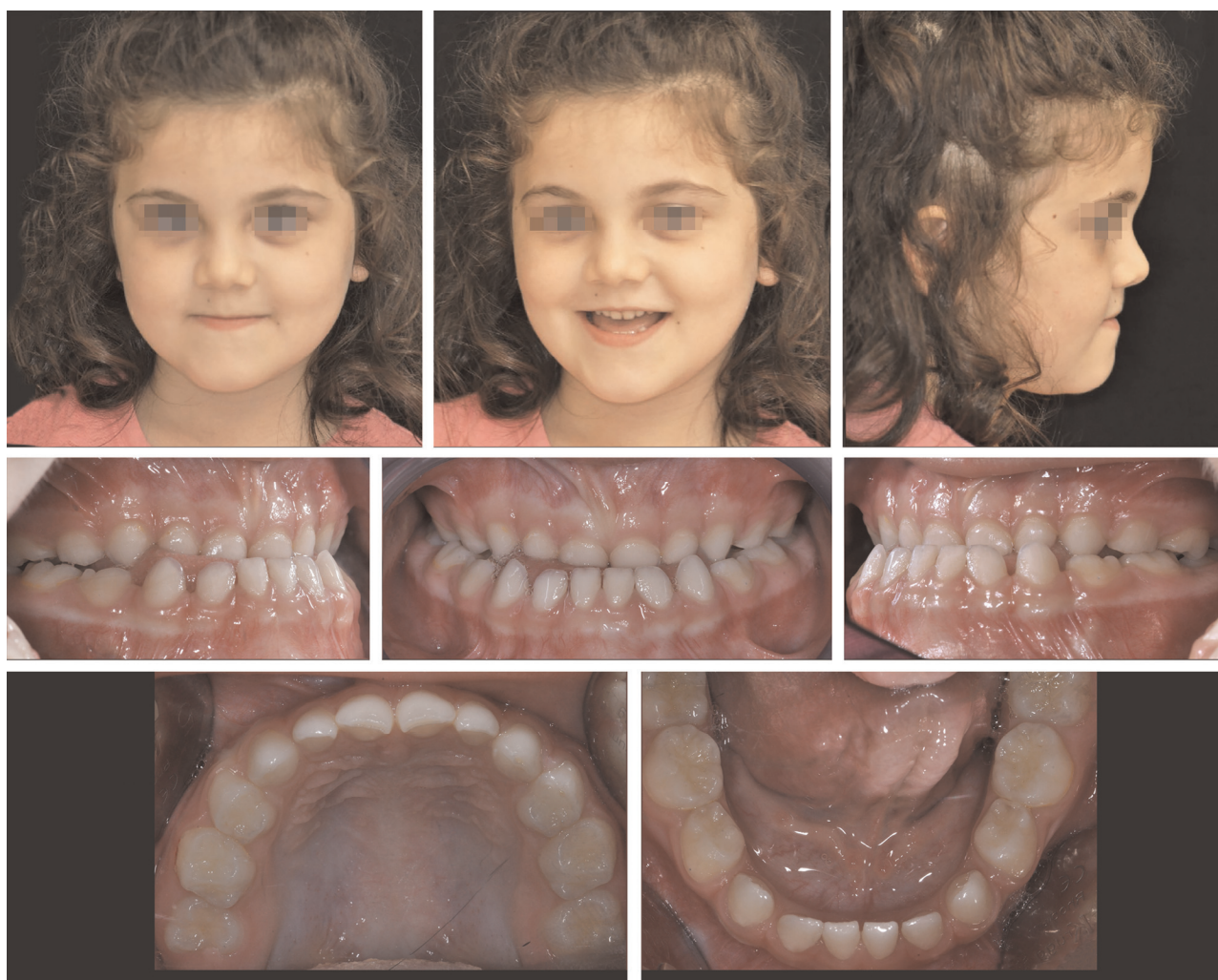

FIGURE 1
5-year-old female patient with skeletal class III relationship before treatment

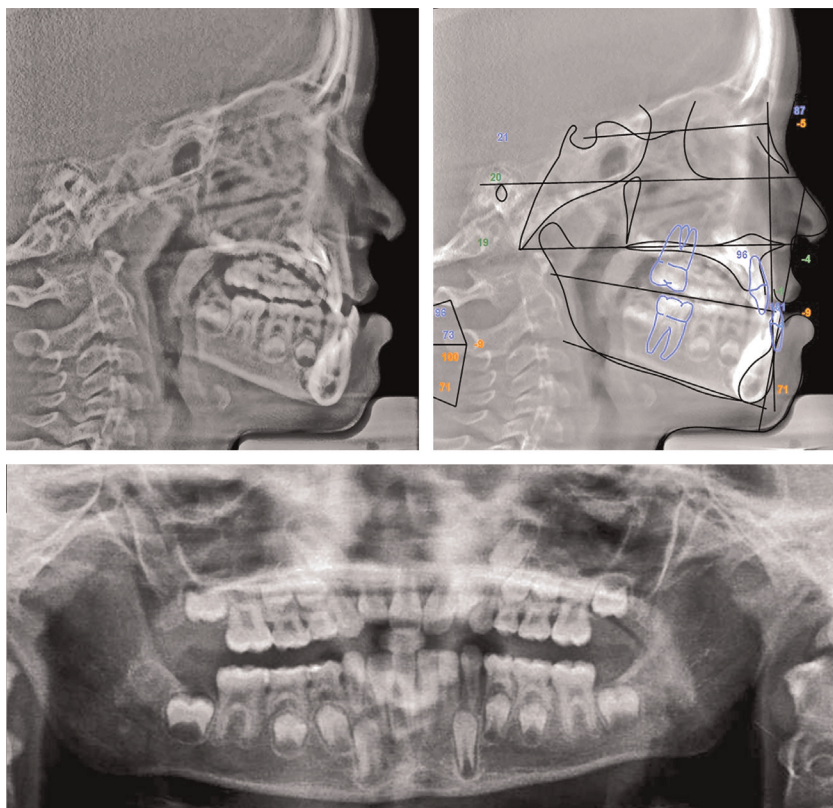


FIGURE 2
X-rays documents before treatment

The occlusal photographs highlighted the absence of crowding, which represents a normal condition in primary dentition. The periodontal biotype turned out to be thick (*figure 2*).

Treatment objectives

Since the sagittal discrepancy was determined not only by a prominent mandible, but also by a retruded maxilla in an hypodivergent facial type, an early phase I treatment was selected in order to allow an improvement of the transverse and sagittal skeletal relationships, slowing down progressively the residual component of the mandibular growth. Although it was not possible to guarantee the complete resolution of the skeletal discrepancy, this treatment plan was followed. Class III malocclusion therapy expected rapid maxillary expander combined with facemask, and given the good therapeutic response in primary dentition, with a good skeletal component [14], it was decided to use this type of expander in the first instance. Facial asymmetry skeletal correction was not foreseen with this treatment plan, which aimed at the midlines centring through dental compensation. Should facial asymmetry worsen during growth, parents were warned about a surgical correction.

Treatment alternatives

Since the complexity of the sagittal skeletal discrepancy, the first option could be to wait until the end of the growth for an ortho-surgical correction. This option was illustrated to the parents, which appeared concerned for the invasiveness. Moreover, this solution would not have allowed to resolve or reduce the transversal deficit, even in anticipation of a future surgical correction. Another treatment option was represented by miniplates anchorage with bone anchored maxillary protraction (BAMP); however, even if miniplates have greater stability than miniscrews and microscrews, an expansion would not have been performed at the same time [15]. The miniplates would have been efficient at a later stage, but still require a quite invasive surgical approach from the parent's point of view.

Treatment progress

The expander was placed on a 5-year-old patient and it was activated 35 times. A month later, the facial mask was added, asking the patient to wear it with 12 oz elastic bands for 14 hours a day.

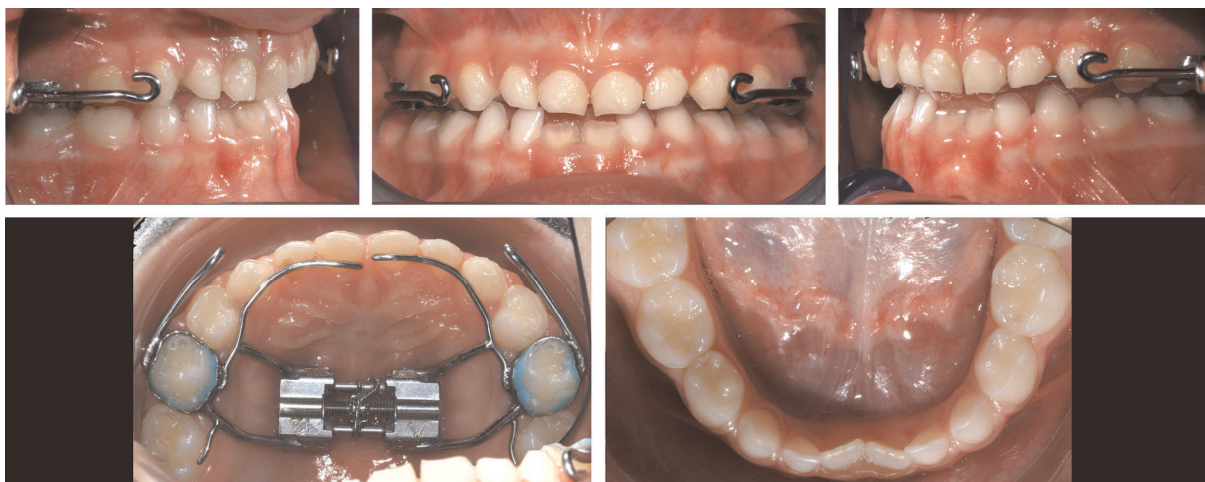

FIGURE 3
Occlusal results after 1 year of treatment with RPE and facemask

This phase of treatment ended one year later and we noted the change in occlusion with the correction of dental class malocclusion (figure 3). At this point, despite the improvement achieved, in the following months there was a little relapse that could be

observable at molars contact, likely due to a significant mandibular growth. Besides, the previous tooth-borne expander had following limitations: poor orthopaedic efficiency from 8 years upwards, loss of space for the erupting teeth, dento-alveolar tipping [14-17]. We could not therefore proceed with

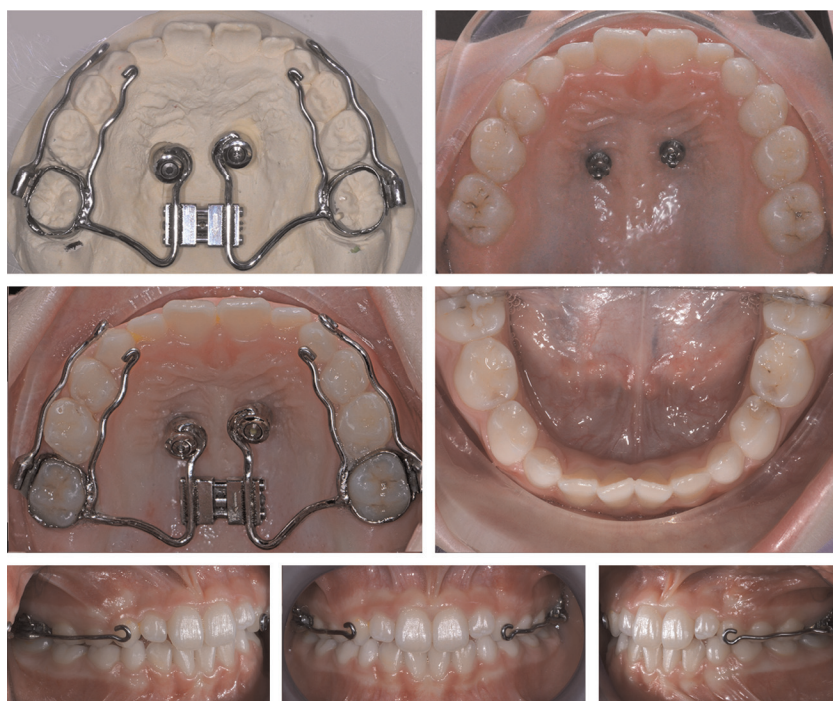


FIGURE 4
Setting up of the Hybrid rapid palatal expander at 8-year-old

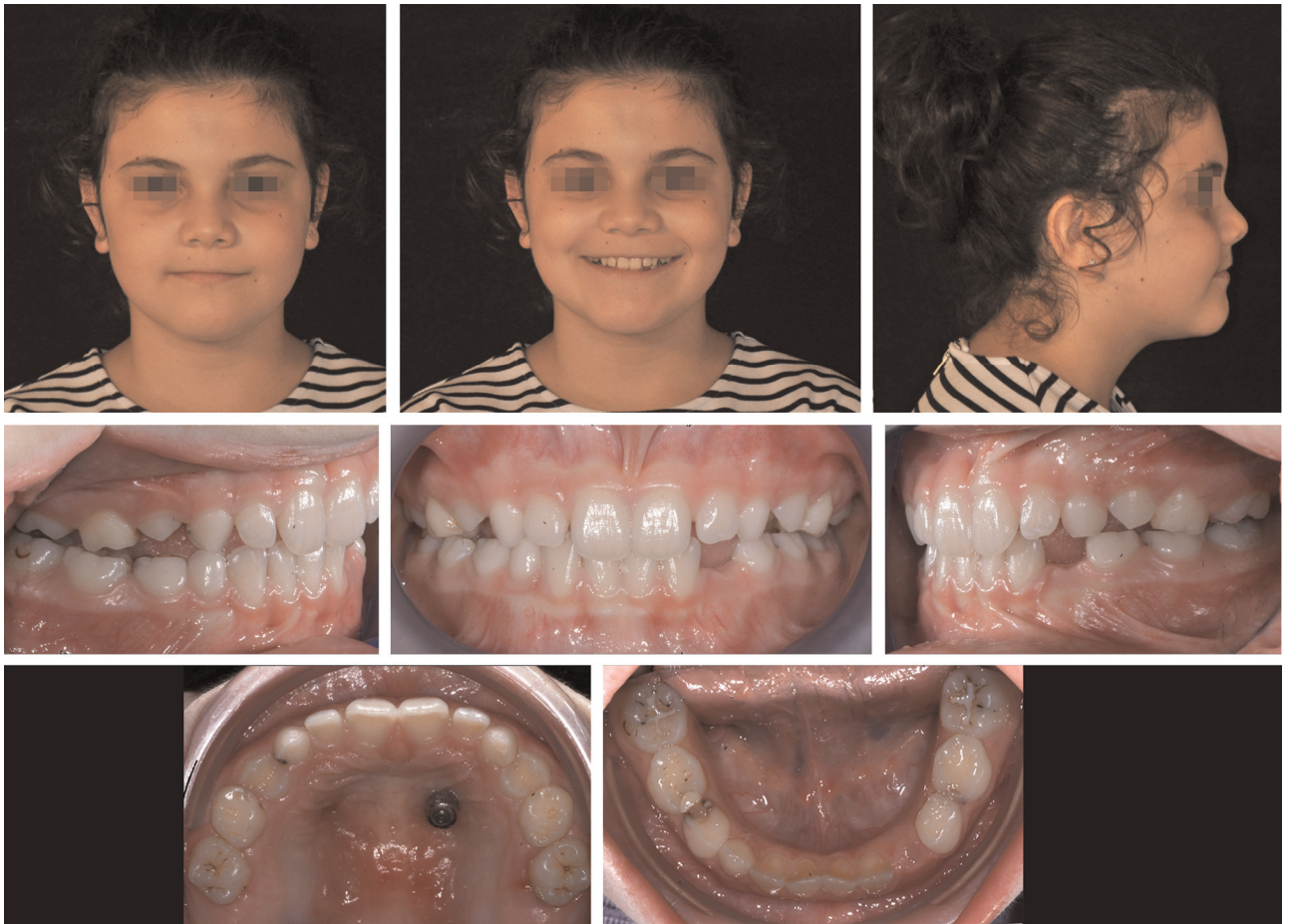

FIGURE 5
9-year-old patient after 1 year of treatment with hybrid RPE and facemask

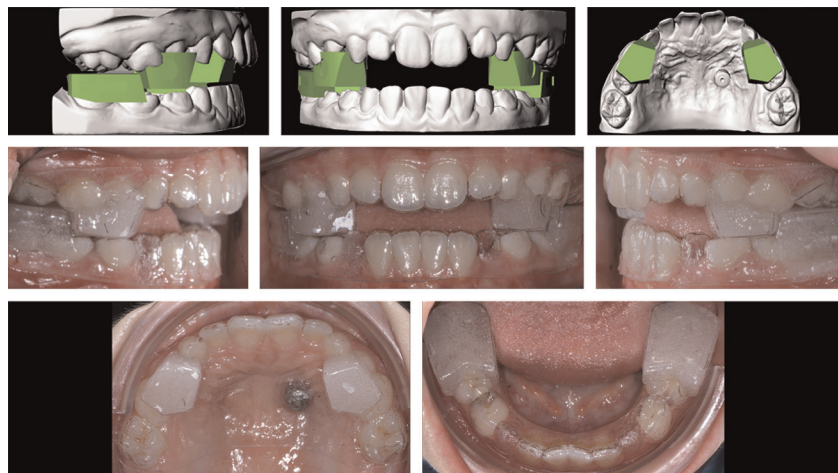

FIGURE 6
Runner III appliance designed as active retainer

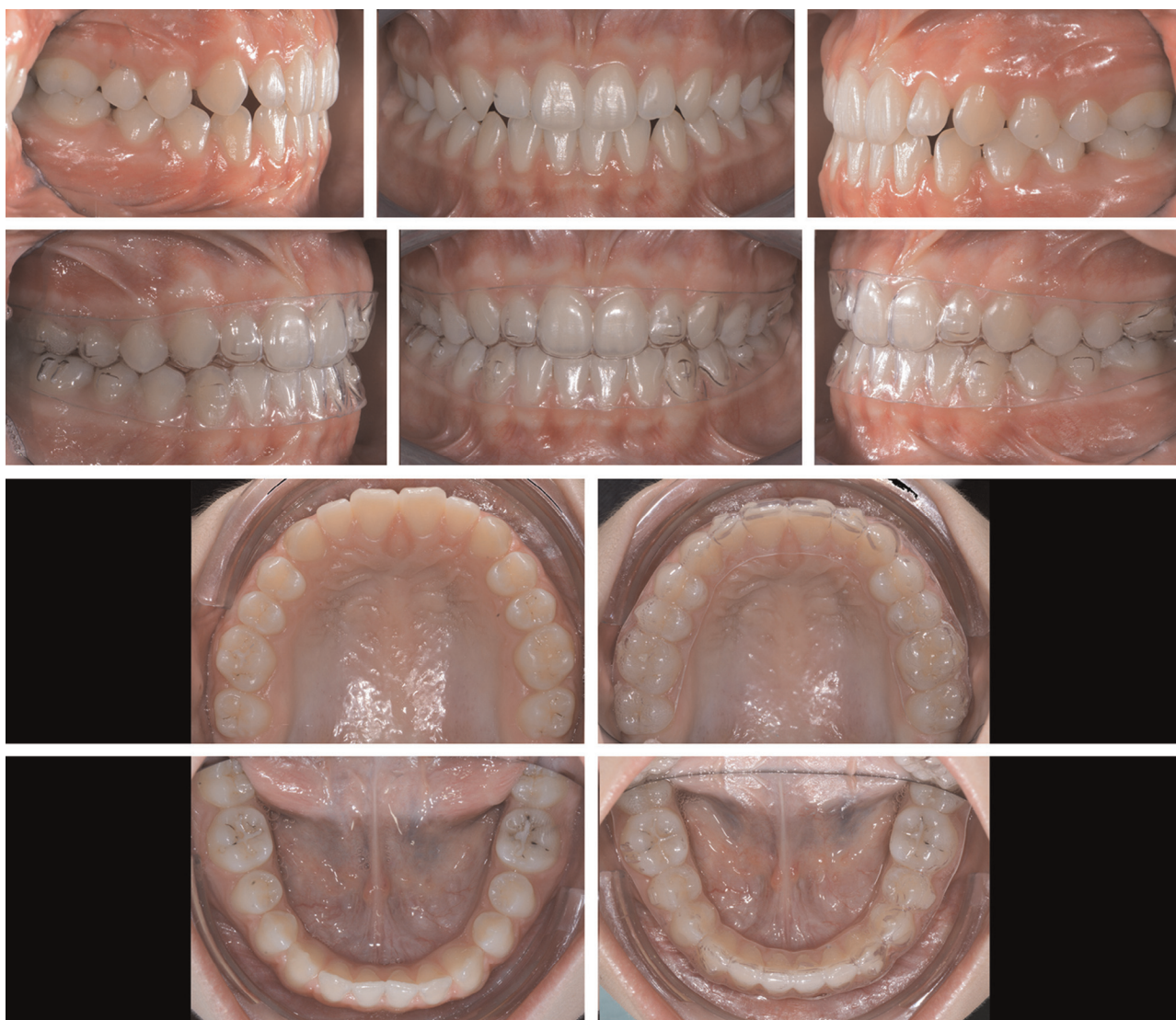

FIGURE 7
 Patient at the beginning of the aligner treatment. Patient at the end of the aligner treatment

the same type of expander and we had to find a new therapeutic solution; innovative expanders on miniscrews were described in the literature as a solution to avoid dental side effects and orthognathic surgery [13]. We presented this option to the parents which accepted and then a rapid maxillary expansion with miniscrews started at the age of eight. Two mini-screws (2 × 11 mm; Spider Screw Regular Plus; HDC, Vicenza, Italy) were inserted in the paramedian areas. The miniscrews were applied using the guided insertion protocol MAPA System [18]. The position of the screws were programmed superimposing TC Cone Beam with the stereolithographic (stl) models, in order to obtain bicorticalism and consequently

a greater stability of the screws. Once the screws were inserted, the appliance, previously adapted with the stl model of the maxilla, was positioned in the same operative session [19]. The expansion device used was SKAR III (Skeletal Alt-RAMEC for class III), which featured mixed dental and skeletal anchorage and welded vestibular arms for attaching the facemask. Liou's protocol [20] was applied in order to obtain a greater maxilla mobility and provided an alternation of 4 activations a day in expansion for 1 week, followed by 4 activations a day in constriction (figure 4). At the end of the fifth week the rapid maxillary expander was activated until the transversal deficit was corrected. The maxillary protraction was achieved via

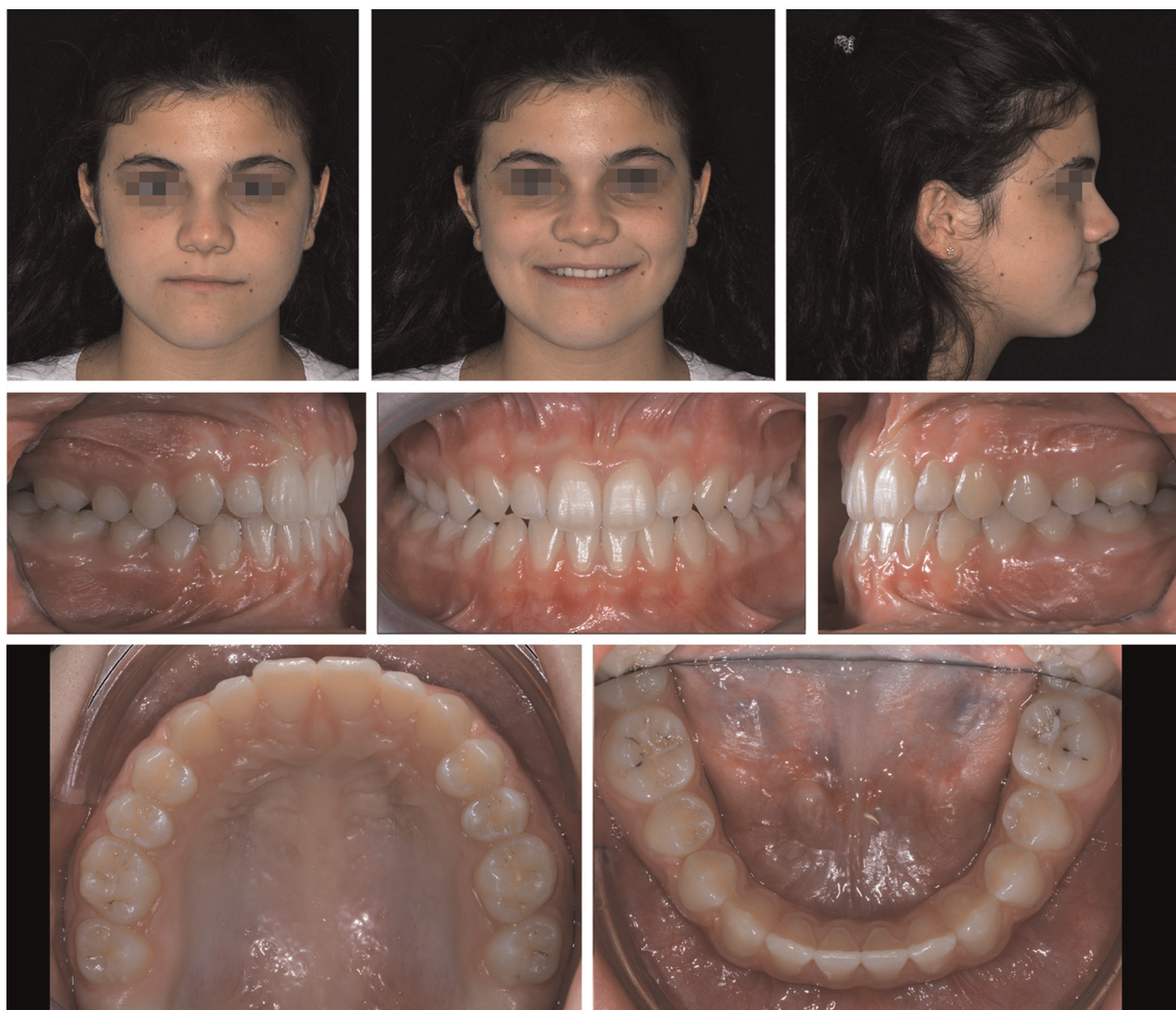

FIGURE 8
Final records

facemask, to be worn 14 hour a day for 4 months. This protocol allowed to obtain a dental class II, overcorrected in view of a relapse, a large amount of expansion that allows a greater eruption space for the canines (figure 5). The difference in ANB angle is 9° ; however, it was accompanied by an increase of the divergence, with the mandible operating a clockwise rotation. The long-term stability of this protocol has not been studied in the literature. For this reason, an appliance similar to an inverse Twin Block, renamed "Runner III", was designed as active retainer, incorporating a miniscrew to ensure that the load exerted on the retainer is discharged, minimizing the dental side effects.

The construction bite was performed with the mandible in retruded and centred position.

The upper blocks extended from the second deciduous molars to the distal surfaces of the canines, and the lower blocks covered the second deciduous molars and the first molars. The height and thickness of the blocks were sufficient to ensure the maintenance of the planned position. The inclination of the plane was roughly 70° (figure 6).

Although the patient would have benefited from a buccal fixed orthodontic therapy, the parents asked to use an aesthetic appliance. Given the good situation of molar class I on the left side, while on the right side there is a "end to end" molar class and the

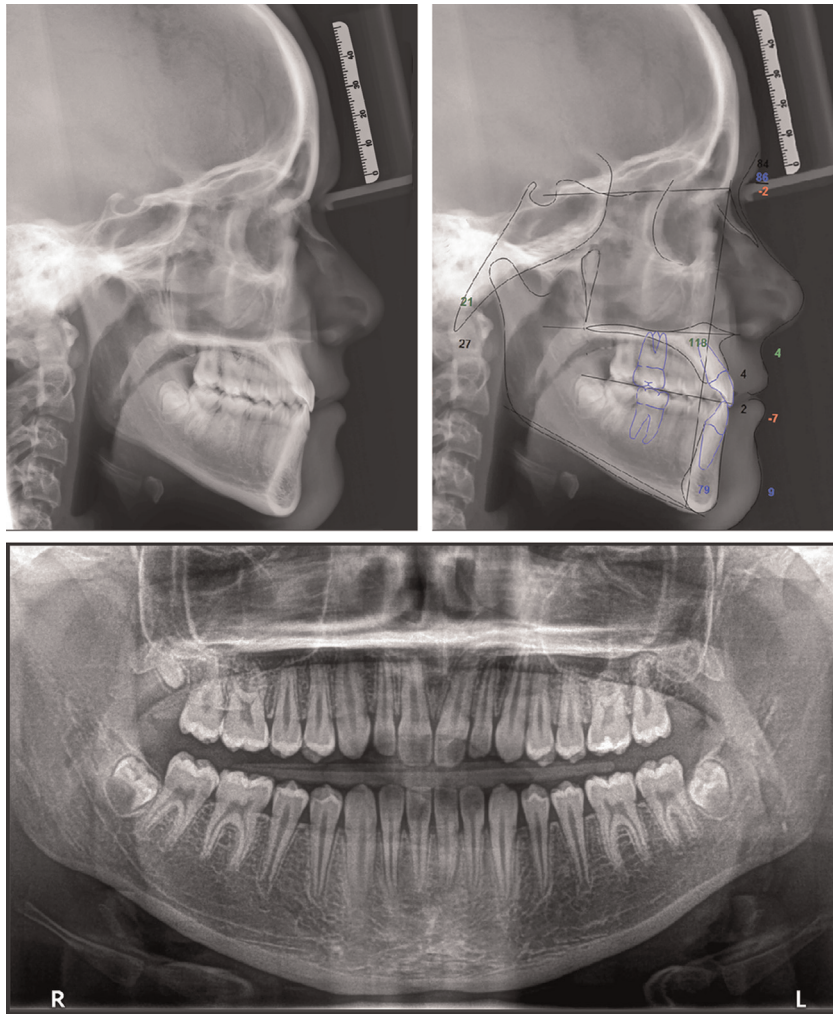


FIGURE 9
X-rays documents after treatment

possibility of a shortened treatment time, we have opted for a treatment with clear aligners (F22) (figure 7).

Treatment results

11 aligners have been programmed to foresee the disto-rotation of the upper molars. The aligners were changed every 7 days, and in 77 days a correct occlusion of class I was achieved with the medians centred (figure 8). The final orthopantomography

and the latero-lateral cephalogram showed a strong dental compensation (IMPA: 79.4°) (figure 9). Arne Björk's structural superimpositions [21,22] of pre- and post-treatment cephalometric tracings highlight the treatment effects (figure 10). With such an important mandibular growth it represented the best non-surgical therapeutic solution. Intraoral and extraoral pictures taken one year after the end of treatment showed a good stability and a pleasant smile (figures 11 and 12).

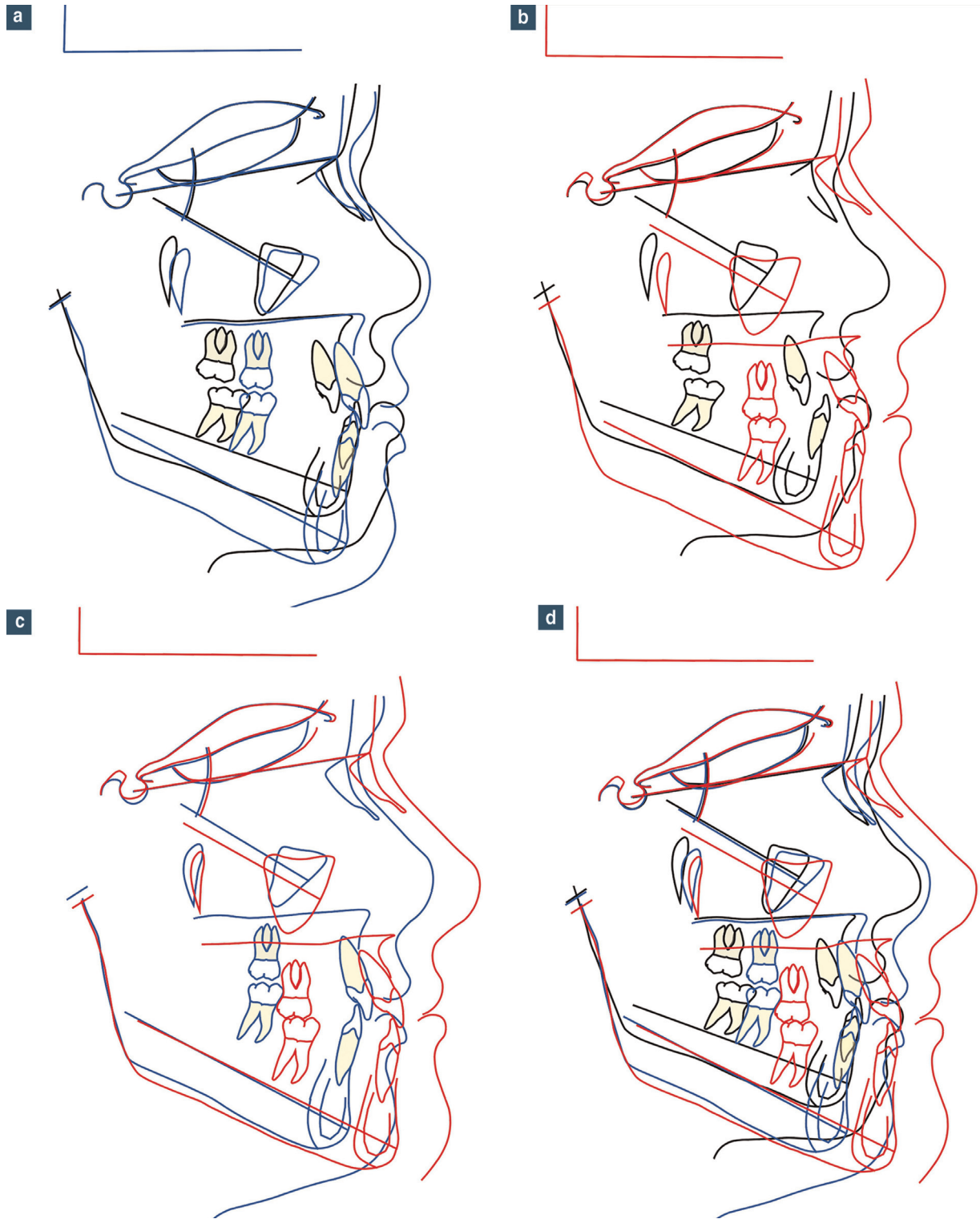


FIGURE 10
Structural general superimpositions: a: orthopaedic phase; b: runner phase; c: aligner phase; d: before-after treatment



FIGURE 11
Extraoral views one year after the end of the treatment

Discussion

As recommended by many authors [14,22], class III treatments should start as early as possible in order to optimize the traditional expander effects. Then, we can subsequently introduce the hybrid-anchored expanders in order to maximize the skeletal advancement and to avoid the loss of space for the erupting teeth and the dento-alveolar tipping. The ortho-surgical correction was first illustrated to the parents without success and it was emphasized that the first phases of treatment would still have reduced the skeletal discrepancies. Many authors demonstrated the facemask therapy effects on the craniofacial skeleton: forward dislocation of the maxilla, backward movement of the mandible, clockwise rotation of the mandibular plane and counterclockwise rotation of the maxillary plane [14,23]. Related to these factors, the case showed a substantial improvement in the Wits appraisal (+9 mm) and in the ANB angle (+9°). Similarly, Nienkemper et al. found an average improvement of 4.1 mm in Wits values using the Hybrid Hyrax combined with facemask, but specifying that skeletal effects

would have been even greater if patients were treated at a younger age (mean age of their sample: 9.5 ± 1.3 years) [24]. Jager et al. showed that maxillary protraction is more effective if it is started before the age of 8 [22]. Wilmes et al. showed that the use of the Hybrid Hyrax, Facemask, and Alt-RAMEC protocol provided a longer-lasting "RPE effect," probably due to the repeated opening of the midpalatal sutures with the Alt-RAMEC protocol [24]. Many authors in the literature agree that skeletal anchorage produces greater maxillary protraction, reducing undesirable dental effects [25-32]. After the expansion, miniplates insertion would be a valid alternative to protract the maxillary, but the invasiveness would not have been easily tolerated by parents.

While palatal miniscrew insertion has been facilitated by techniques, studies and technologies, a digital 3D approach permitted to delete any damage risk and to reduce the patient discomfort, even more so in young patients [18,33,34]. The presence of a residual mini-screw with good stability gave the possibility to use it in combination with "The Runner III",

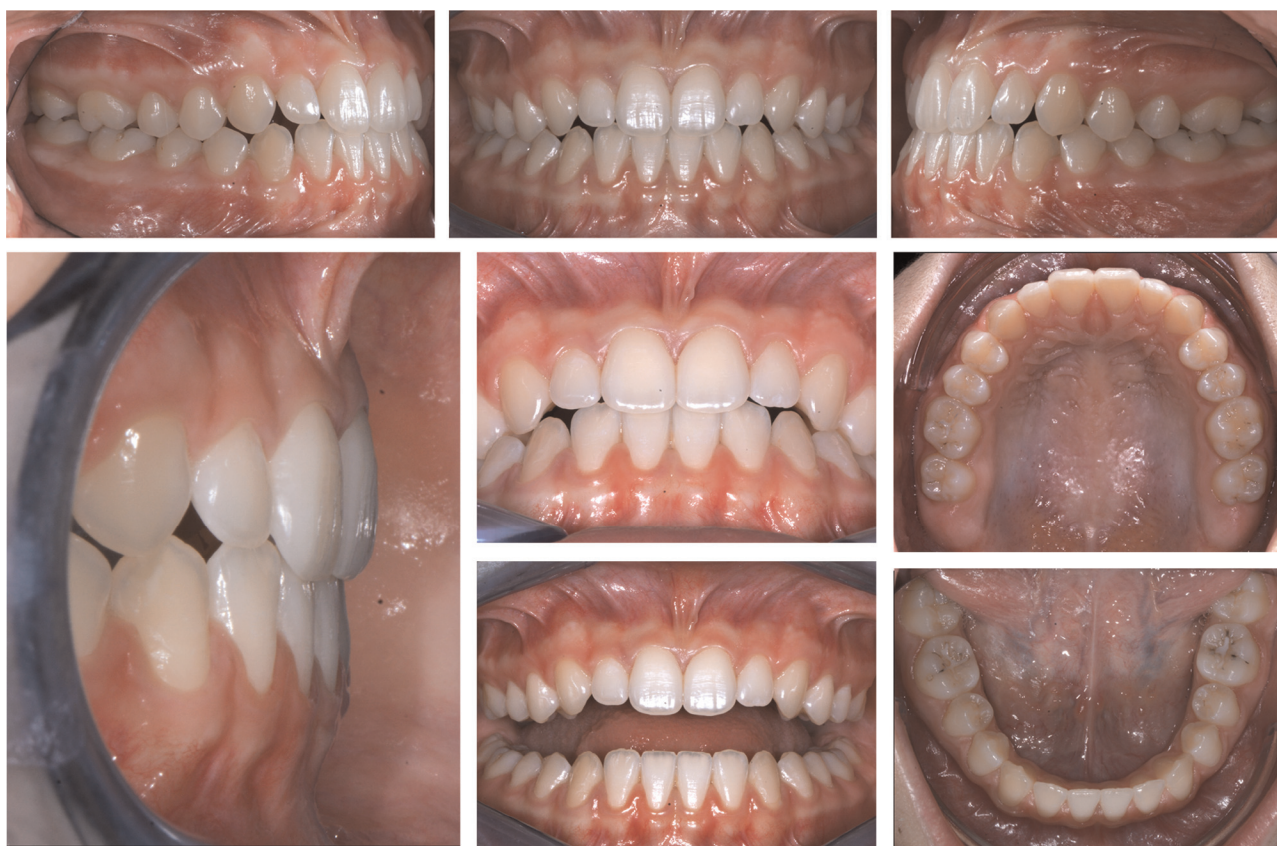

FIGURE 12

Intraoral views one year after the end of the treatment

an appliance similar to "The Runner" and Twin Block, but designed for class III [35,36] which functioned as active retainer and which principles are similar to the Frankel III. The good results of the phase I treatment and of the active retainer meant that a complex case would become relatively simple at the phase II treatment. Clear aligners were used in order to obtain a shorter treatment duration and a successful outcome [37]. The limits of this case are represented by dental compensations on the upper and lower incisors, which would have been certainly improved with orthognathic surgery or miniplates. The most invasive solutions would have given ideal face aesthetic parameters and incisors torque values; however, the best non-surgical therapeutic solution was chosen.

Conclusions

The combination of the rapid palatal expander, SKAR III (Skeletal Alt-RAMEC for Class III), Liou's Protocol, face-mask, and an active retainer offers the possibility to treat severe Class III cases with retrognathic maxilla because:

- the transversal and sagittal forces are transferred to the maxillary bone, obtaining clinically irrelevant side effects in terms

of mesial migration, loss of space for the eruptive teeth, skeletal movements;

- the treatment is less invasive than the surgery treatment alternatives;
- the results are good in a reasonable amount of time.

Funding: The authors declare that they have not received funding

Availability of data and materials: The authors declare that the materials are available

Authors' contributions: L.L. is responsible for the treatment planning decision and clinical patient treatment. P.A., L.B. did the article test production. F.C. had a hand in the digital elaboration set-up and planning. S.G. contributed in the treatment planning decision and clinical patient treatment.

Ethics approval and consent to participate: The study was performed in accordance with the Declaration of Helsinki.

Consent for publication: Written informed consent was obtained from the patient for publication of this short report and any accompanying images.

Disclosure of interest: The authors declare that they have no competing interest.

References

- [1] Potpeschenigg R. Deutsche Viertel Jahrschrift für Zahnheilkunde, 1885. Month Rev Dent Surg 1975;1974:464-5.
- [2] Delaire J. Confection du « masque orthopédique » Manufacture of the "orthopedic mask" Rev Stomatol Chir Maxillofac 1971;72:579-82.
- [3] Delaire J, Verdon P, Lumineau JP, Ghega-Negrea A, Talmant J, Boisson M. Some results of extra-oral tractions with front-chin rest in the orthodontic treatment of class 3 maxillomandibular malformations and of bony sequelae of cleft lip and palate. Rev Stomatol Chir Maxillofac 1972;73(8):633-42.
- [4] Delaire J. The frontomaxillary suture. Theoretical bases and general principles of the application of postero-anterior extraoral forces to the orthopedic mask. Rev Stomatol Chir Maxillofac 1976;77:921-30.
- [5] Petit HP. Adaptation following accelerated facial mask therapy. In: McNamara Jr. J.A, Ribbens K.A, Howe R.P, editors. In: Clinical alterations of the growing face. Monograph 14:253-89. Craniofacial Growth Series. Ann Arbor, Michigan: Center for Human Growth and Development, University of Michigan; 1983.
- [6] McNamara JA. An orthopedic approach to the treatment of Class III malocclusion in growing children. J Clin Orthod 1987;21:598-608.
- [7] Turley PK. Orthopedic correction of Class III malocclusion with palatal expansion and custom protraction headgear. J Clin Orthod 1988;22:314-25.
- [8] Mermigos J, Full CA, Andreasen G. Protraction of the maxillofacial complex. Am J Orthod Dentofac Orthop 1990;98:47-55.
- [9] Ngan P, Hägg U, Yiu C, Merwin D, Wei SHY. Treatment response to maxillary expansion and protraction. Eur J Orthod 1996;18:151-68.
- [10] Haas AJ. Treatment of maxillary deficiency by opening the midpalatal suture. Angle Orthod 1965;65:200-17.
- [11] Haas AJ. Palatal expansion: just the beginning of dentofacial orthopedics. Am J Orthod 1970;57:219-55.
- [12] McNamara Jr JA, Brudon WBL. Orthodontic and orthopedic treatment in the mixed dentition. 1st edition, Ann Arbor, Michigan: Needham Press; 1993 (365 p.).
- [13] Lee KJ, Park YC, Park JY, Hwang WS. Miniscrew-assisted nonsurgical maxillary expansion before orthognathic surgery for a patient with severe mandibular prognathism. Am J Orthod Dentofacial Orthop 2010;137:830-9.
- [14] Cordasco G, Matarese G, Rustico L, Fastuca S, Caprioglio A, Lindauer SJ. Efficacy of orthopedic treatment with protraction facemask on skeletal Class III malocclusion: a systematic review and meta-analysis. Orthod Craniofac Res 2014;17:133-43.
- [15] Capelozza Filho L, Cardoso Neto J, da Silva Filho OG, Ursi WJ. Non-surgically assisted rapid maxillary expansion in adults. Int J Adult Orthodon Orthognath Surg 1996;11:57-66.
- [16] De Clerck H, Cevidanes L, Baccetti T. Dentofacial effects of bone-anchored maxillary protraction: a controlled study of consecutively treated Class III patients. Am J Orthod Dentofacial Orthop 2010;138.5:577-81.
- [17] Gurel HG, Memili B, Erkan M, Sukurica Y. Long-term effects of rapid maxillary expansion followed by fixed appliances. Angle Orthod 2010;80.1:5-9.
- [18] Maino BG, Paoletto E, Lombardo L, Siciliani G. A three-dimensional digital insertion guide for palatal miniscrew placement. J Clin Orthod 2016;50.1:12-22.
- [19] Lombardo L, Gracco A, Zampini F, Stefanoni F, Mollica F. Optimal palatal configuration for miniscrew applications. Angle Orthod 2010;80.1:145-52.
- [20] Maino G, Turci Y, Arreghini A, Paoletto E, Siciliani G, Lombardo L. Skeletal and dentoalveolar effects of and facemask treatment in growing skeletal class III patients. Am J Orthod Dentofacial Orthop 2018;153:262-8.
- [21] Liou EJ. Effective maxillary orthopedic protraction for growing Class III patients: a clinical application simulates distraction osteogenesis. Prog Orthod 2005;6:154-71.
- [22] Jager A, Braumann B, Kim C, Wahner S. Skeletal and dental effects of maxillary protraction in patients with Angle Class III malocclusion: a meta-analysis. J Orofac Orthop 2001;62:275-84.
- [23] Foersch M, Jacobs C, Wriedt S, Hechtner M, Wehrbein M. Effectiveness of maxillary protraction using facemask with or without maxillary expansion: a systematic review and meta-analysis. Clin Oral Invest 2015;19:1181-92.
- [24] Nienkemper M, Wilmes B, Pauls A, Drescher D. Maxillary protraction using a hybrid hyrax-facemask combination. Prog Orthod 2013;14.1:5.
- [25] Wilmes B, Ngan P, Liou E, Franchi L, Drescher D. Early Class III facemask treatment with the hybrid Hyrax and Alt-RAMEC protocol. J Clin Orthod 2014;48:84-93.
- [26] Clemente R, Contardo L, Greco C, Di Lenarda R, Perinetti G. Class III treatment with skeletal and dental anchorage: a review of comparative effects. Biomed Res Int 2018;2018:7946019.
- [27] Hino CT, Cevidanes LH, Nguyen TT, De Clerck HJ, Franchi L, McNamara Jr JA. Three-dimensional analysis of maxillary changes associated with facemask and rapid maxillary expansion compared with bone anchored maxillary protraction. Am J Orthod Dentofacial Orthop 2013;144:705-14.
- [28] Lee NK, Yang I-H, Baek S-H. The short-term treatment effects of face mask therapy in Class III patients based on the anchorage device: miniplates vs rapid maxillary expansion. Angle Orthod 2012;82:846-52.
- [29] Koh SD, Chung DH. Comparison of skeletal anchored facemask and tooth-borne facemask according to vertical skeletal pattern and growth stage. Angle Orthod 2014;84:628-33.
- [30] Tripathi T, Rai P, Singh N, Kalra S. A comparative evaluation of skeletal, dental, and soft tissue changes with skeletal anchored and conventional facemask protraction therapy. J Orthod Sci 2016;5:92-9.
- [31] Al-Mozany SA, Dalci O, Almuzian M, Gonzalez C, Tarraf NE, Ali Darendeliler M. A novel method for treatment of Class III malocclusion in growing patients. Prog Orthod 2017;18:40.
- [32] Lin HY, Yang H, Lai EH, Lin SY, Chang JZ. Three-phase treatment concept for skeletal Class III growing patients with severe space deficiency: a report of three cases with skeletally anchored maxillary protraction. J Formos Med Assoc 2020;119:869-78.
- [33] Ludwig B, Glasl B, Bowman SJ, Wilmes B, Kinzinger GS, Lisson JA. Anatomical guidelines for miniscrew insertion: palatal sites. J Clin Orthod 2011;45:433-41.
- [34] Maequezan M, Nojima LI, Freitas AO, et al. Tomographic mapping of the hard palate and overlying mucosa. Braz Oral Res 2012;26:36-42.
- [35] Arreghini A, Carletti I, Ceccarelli MC, Lombardo L, Siciliani G. Class II treatment in adolescent patient with "The Runner": combining Twin Block efficiency with aligner aesthetics. J World Fed Orthod 2014;3.2:e71-9.
- [36] Clark WJ. Twin-block functional therapy: applications in dentofacial orthopedics. 2nd Revised ed. London: Mosby-Wolfe; 2002 (384 p.).
- [37] Zheng M, Liu R, Ni Z, Yu Z. Efficiency, effectiveness and treatment stability of clear aligners: a systematic review and meta-analysis. Orthod Craniofac Res 2017;20.3:127-33.