

Systemic allergic dermatitis due to gentamicin.

Monica Corazza, Riccardo Forconi, Giulia Toni, Valeria Scuderi, Lucia Mantovani, Alessandro Borghi

Section of Dermatology, Department of Medical Sciences, University of Ferrara, Italy

Running head: systemic allergic dermatitis due to gentamicin.

Key words: case report, systemic allergic dermatitis, allergic contact dermatitis, patch test

Address:

Monica Corazza
Section of Dermatology, Department of Medical Sciences
University of Ferrara
via L. Ariosto 35
44121 Ferrara, Italy
Phone: +39 0532239685
E-mail: czm@unife.it

Conflict of interests: None to report

The sensitizing potential of aminoglycosides is well known and neomycin is the most commonly reported contact allergen (1). We report a case of systemic allergic dermatitis related to the use of topical gentamicin.

Case report

A 62-year-old woman developed a superficial and partial thickness thermal burn on her left leg and foot (4% of total body surface area) after accidental contact with boiling water. Iruxol ointment and Gentamicin 0.1% Mylan cream were topically administered. After 3 weeks the burn worsened and perilesional eczematization appeared (Fig.1a). An itchy eczema on her scalp and on the extensor part of her limbs and hands developed as well. The topical medications were discontinued; Betamethasone 0.05% Sandoz cream and Fusidic acid 0.02% Teva cream were applied. Patch test was performed with the Italian (SIDAPA) baseline series (F.I.R.M.A., Florence, Italy), which includes neomycin sulfate, and with all the topical products used for medications tested "as is".

This article has been accepted for publication and undergone full peer review but has not been through the copyediting, typesetting, pagination and proofreading process which may lead to differences between this version and the Version of Record. Please cite this article as doi: 10.1111/cod.13352

Patch test chambers (Van der Bend, Brielle, The Netherlands) were applied on the upper part of the patient's back. The readings on day (D) 2, D4 and D7, according to ESDC guidelines (2), showed a positive reaction only to Gentamicin cream (++)/+++/(+++). During patch testing the patient developed a widespread flare of itchy eczematous dermatitis involving the whole body except the face (Fig.1b,c,d). Systemic corticosteroids were prescribed and healing of the eczema and of the thermal injury was achieved. Six weeks later, a semi-open test with gentamicin 25% pet. on the right arm was performed, showing a positive localised reaction on D2 and D4 readings. Systemic allergic dermatitis due to gentamicin was diagnosed.

Discussion

Systemic allergic dermatitis is an eczematous reaction occurring in subjects previously sensitized by contact after subsequent systemic re-exposure to the same or cross-reacting substance. The related pathomechanism is probably a T cell-mediated, delayed hypersensitivity reaction to an allergen that reaches the skin through haematogenous transport. Systemic symptoms may be associated, including headaches, fever, arthralgia and diarrhoea (3).

In our patient we recognized Gentamicin cream as the causal agent of the widespread eczematous dermatitis. As recommended in the literature we waited six weeks after the resolution of the dermatitis before testing gentamicin as standardized test preparation (4). A semi-open test was preferred in order to avoid massive drug absorption.

The majority of cases of allergic contact dermatitis due to gentamicin reported in the literature are related to its topical use (5). Rare cases of systemic allergic dermatitis due to gentamicin are described: all these cases were due to intravenous administration or related to gentamicin-loaded arthroplasty implants (6-8). Although numerous cases of contact dermatitis due to gentamicin arise from cross-sensitivity to neomycin, in this case the patient appears to have been sensitized only to gentamicin. Broken skin and multiple, occlusive dressing for several days could have favored drug absorption, accumulation in the skin and sensitization.

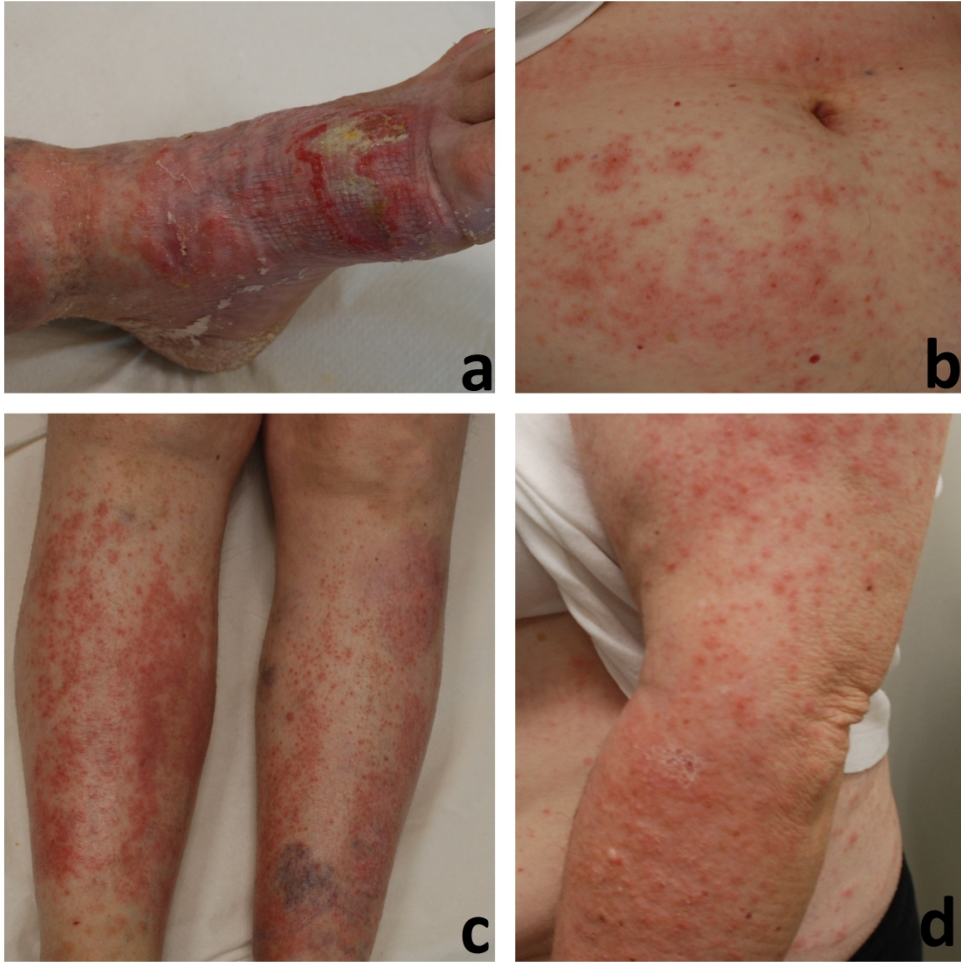
References

1. Gilissen L, Goossens A. Frequency and trends of contact allergy to and iatrogenic contact dermatitis caused by topical drugs over a 25-year period. *Contact Dermatitis*. 2016;75:290-302.
2. Johansen JD, Aalto-Korte K, Agner T, et al. European Society of Contact Dermatitis guideline for diagnostic patch testing - recommendations on best practice. *Contact Dermatitis*. 2015;73:195-221.

3. Thyssen JP, Maibach HI. Drug-elicited systemic allergic (contact) dermatitis – update and possible pathomechanisms. *Contact Dermatitis*. 2008;59: 195-202.
4. Barbaud A. Skin testing and patch testing in non-IgE-mediated drug allergy. *Curr Allergy Asthma Rep*. 2014;14:442.
5. Green CM, Holden CR, Gawkrödger DJ. Contact allergy to topical medicaments becomes more common with advancing age: an age-stratified study. *Contact Dermatitis*. 2007;56:229-231.
6. Paniagua MJ, García-Ortega P, Tella R, Gaig P, Richart C. Systemic contact dermatitis to gentamicin. *Allergy*. 2002;57:1086-1087.
7. Wittmann D, Summer B, Thomas B, Halder A, Thomas P. Gentamicin allergy as an unexpected ‘hidden’ cause on complications in knee arthroplasty. *Contact Dermatitis*. 2018;78:293-294.
8. Thomas B, Kulichova D, Wolf R, et al. High frequency of contact allergy to implant and bone cement components, in particular gentamicin, in cemented arthroplasty with complications: usefulness of late patch test reading. *Contact Dermatitis*. 2015;73:343-349.

Figure legend

Fig. 1. (a) Partial thickness thermal burn with perilesional eczematization. (b) Widespread eczematous dermatitis of the abdomen, (c) legs and (d) upper left limb.



276x276mm (300 x 300 DPI)