

Periacetabular bone densitometry after total hip arthroplasty with highly porous titanium cups: a 2-year follow-up prospective study

[AUTHOR: please add any middle initials for all authors where applicable.]

Leo Massari¹, Alessandro Bistolfi², Pier P. Grillo², Alda Borre³, Gaetano Gigliofiorito¹, Carlotta Pari¹, Andrea Francescotto⁴, Piermario Tosco², Davide Deledda², Laura Ravera², Araldo Causero⁴

¹University of Ferrara, Hospital S. Anna, Ferrara - Italy [AUTHOR: please check affiliations.]

²Department of Orthopaedics, Traumatology and Rehabilitation, University Hospital of Turin Health and Science, Turin - Italy

³Radiodiagnostic Orthopaedic Traumatology Centre, University Hospital of Turin Health and Science, Turin - Italy

⁴University Hospital of Udine, Udine - Italy

ABSTRACT

Introduction: Trabecular Titanium is an advanced cellular solid structure, composed of regular multiplanar hexagonal interconnected cells that mimic the morphology of the trabecular bone. This biomaterial demonstrated improved mechanical properties and enhanced osteoinduction and osteoconduction in several in vitro and in vivo studies. The aim of this study was to assess Trabecular Titanium osseointegration by measuring periacetabular changes in bone mineral density (BMD) with dual-emission x-ray absorptiometry (DEXA).

Methods: 89 patients (91 hips) underwent primary total hip arthroplasty (THA) with acetabular Trabecular Titanium cups. Clinical (Harris Hip Score (HHS), SF-36) and radiographic assessment were performed preoperatively, and postoperatively at 7 days and at 3, 6, 12 and 24 months. DEXA analysis was performed only postoperatively, using the BMD values measured at 7 days as baselines.

Results: After an initial decrease from baseline to 6 months, BMD increased and progressively stabilised in all 3 regions of interest (ROIs). Median (IQR) HHS and SF-36 increased from 48 (39-62) and 49 (37-62) preoperatively to 99 (96-100) and 86 (79-92) at 24 months, indicating a considerable improvement in terms of pain relief, functional recovery and quality of life. BMD patterns and radiographic evaluation showed evident signs of periacetabular bone remodelling and osseointegration; all cups were stable at the final follow-up without radiolucent lines, loosening or osteolysis. No revisions were performed.

Conclusions: After an initial reduction in periacetabular BMD, all 3 ROIs exhibited stabilisation or slight recovery. Although clinical outcomes and functional recovery proved satisfactory, longer follow-ups are necessary to assess this cup long-term survivorship.

Keywords: Cementless, DELTA-TT cup, Dual-emission x-ray absorptiometry (DEXA), Osseointegration, Total hip arthroplasty (THA), Trabecular titanium

Introduction

Revisions of the acetabular components have remained a limiting factor in the longevity of hip prostheses, with wear and aseptic loosening recorded as the major causes of failure (1, 2). Primary fixation of cementless cups is fundamental to

yield long-lasting implants and is usually achieved through a tight physical interlocking between the implant porous coating and the surrounding bone tissue at the time of surgery, which is instrumental in promoting secondary fixation via bone in-growth (1, 2). Furthermore, adequate 3-D structure and pore size are key factors for fostering osteogenic processes with effective vascularisation and oxygenation (3, 4). Trabecular Titanium is a highly porous biomaterial composed of regular multiplanar hexagonal interconnected cells that mirror the morphology of the trabecular bone. The geometric characteristics of the trabecular framework have been optimized to favour the process of osteogenic differentiation (3-6). Trabecular Titanium presents an elastic modulus (1.1 GPa) that is greatly inferior to those of other materials used in the orthopaedic field but more similar to that of trabecular bone (5, 6). Thus, it guarantees the transmission of physiological stresses from the implant to the bone without increasing

Accepted: March 1, 2017

Published online:

Corresponding author:

Leo Massari
University of Ferrara
S. Anna Hospital
Via Aldo Moro 8
44124 Cona, Ferrara, Italy
msl@unife.it

implant stiffness (7). Bone mineral density (BMD) is regarded as a good clinical indicator of the bone-remodelling response after arthroplasty (8). Dual-energy [x-ray](#) absorptiometry (DEXA) is currently the most widely used technique for measuring BMD after THA. Finite element analysis (FEM) and computer-simulated modelling have suggested that declines in periacetabular BMD reflect altered stress patterns within the pelvic area. Traditional metal-backed prosthetic implants are generally stiffer than the native subchondral plate and thus mechanically shield the cancellous bone at the central part of the ilium. In contrast, the iliac peripheral cortex is subjected to a greater transfer of weight-bearing force (7, 9-11). The aim of this prospective multicentre study was to investigate the osseointegrative potential of Trabecular Titanium by using DEXA to measure changes in BMD around cementless primary cups.

Methods

Patient population

The patients were selected from a population requiring primary THA according to the following eligibility criteria: males and females, aged between 18 and 75 years, body mass index (BMI) ≤ 40 kg/m², and affected by pathologies such as idiopathic osteoarthritis, avascular necrosis or post-traumatic arthritis. The following conditions were regarded as contraindications for inclusion in this investigation: age >76; haemophilic disease; femoral neck fracture; insulin dependent diabetes mellitus (IDDM); severe kidney failure (grade 4); not-responding hypo- or hyperthyroidism; Paget's disease; tumours; active or suspicious infections; neurosensory deficits or neuromuscular diseases; and severe and impairing vascular diseases.

89 patients (91 hips) underwent primary THA with DELTA-TT cups (Lima Corporate) at 4 centres between February 2009 and November 2010. There were 46 (52%) men and 43 (48%) women, with a median (IQR) age and BMI of 67 (57-70) years and 26 (24-29) kg/m², respectively. In 13 (14.3%) cases contralateral THAs were also performed. Underlying pathology was primary osteoarthritis (88%), osteonecrosis (6%), post-traumatic osteoarthritis (3%), developmental dysplasia of the hip (DDH) (2%) and oligoarthritis (1%). The study was approved by the Ethics Committee of each centre. Informed consent was obtained prior to enrolment from all patients.

Prostheses

Hemispherical press-fit acetabular cups of Trabecular Titanium (DELTA-TT) were used in all cases. The shell of this cup is manufactured entirely of titanium alloy (Ti6Al4V) via an electron beam melting procedure (5, 6). This [1-step](#) production process guarantees structural continuity between the external highly porous surface and the inner solid part that hosts the liner. Trabecular Titanium differs from most conventional prosthetic coatings; the absence of an interface between the external trabecular structure and the bulk confers higher structural solidity and tensile resistance (5, 6). Its regular trabecular structure is characterized by an average porosity of 65% with a mean pore diameter of 640 μ m (5).

The surface of Trabecular Titanium is characterised by a high coefficient of friction that is responsible intraoperatively for the initial grip of the DELTA-TT cup (12). The cups ranged in diameter from 48 to 60 mm and were implanted with a wide selection of bearing couplings, including Ceramic-Ceramic (70%), Cer-XLPE (23%), Met- XLPE (1%), and Met-Met (6%). Additional reinforcement screws were used in 6 (6.6%) cases as a further safety measure to prevent possible risks of loosening in the cases in which patients presented with particularly poor bone quality.

Surgical technique

All procedures were performed in each centre by a senior surgeon, or under his direct supervision, according to standard surgical technique under either spinal (92.3%) or general anaesthesia (7.7%). The surgical approach was lateral in 28 (30.8%) cases, posterolateral in 49 (53.8%) and anterior in 14 (15.4%) cases. The surgeons and physical therapists considered variables such as the subject's age, health and physical fitness when recommending a rehabilitation programme. Patient mobilisation generally began on the 1st postoperative day, and continued with 50% weight-bearing on 2 crutches starting the 3rd day after surgery, followed by full ambulation with 1 crutch after 1 month.

Clinical and radiographic assessment

Clinical and radiographic evaluations were performed preoperatively and postoperatively, at 7 days and at 3, 6, 12 and 24 months. Patients were evaluated using the Harris Hip Score (HHS) (13) and a self-assessment questionnaire (SF-36) (14). The incidences of intra- and postoperative complications were also monitored.

The radiographic assessment included standard views, such as the anteroposterior (AP) of the pelvis and the anteroposterior (AP) and lateral (LAT) of affected hip. Radiolucent lines were evaluated according to their presence, location and thickness. Postoperative radiographs at discharge were used as baselines to evaluate the progressions of radiolucent lines and to assess the initial angle of abduction and the initial postoperative fit of the cup. Evidence of osteolysis (location), sclerosis, atrophy (degree and location), ectopic bone formation (15), dislocation and subluxation were recorded.

DEXA analysis

Periprosthetic BMD was evaluated via DEXA using a bone densitometer Hologic® Scanner (QDR 4500 Elite or QDR Delphi) equipped with a metal-removal scanning mode that allowed for the exclusion of the prosthetic acetabular component from the analysis. Image acquisitions were executed in the frontal plane using the femoral head to centre the scans with an upper limit of the entire whole scanning zone of 3.0-3.5 cm above the proximal edge of the acetabular component. Pelvic scans were analysed using 3 regions of interest (ROIs) that were defined according to a modified DeLee and Charnley's model (16) (Fig. 1). Scans of the affected hip were performed postoperatively at 7 days and at 3, 6, 12 and 24 months after surgery. Variations in BMDs were evaluated

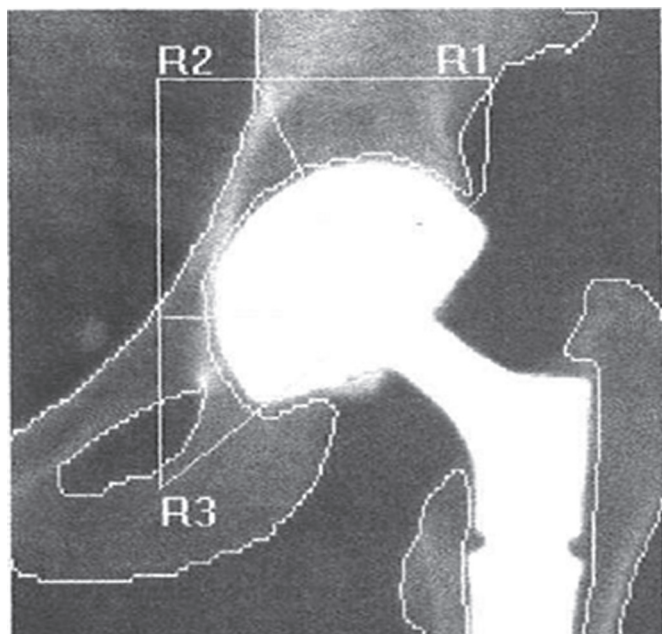


Fig. 1 - Subdivision of the acetabulum into 3 regions of interest (ROIs) according to a modified DeLee and Charnley’s model (16). The 3 zones were determined by tracing a line connecting the centre of the prosthetic head to the two edges of the acetabulum. Zone 3 was defined by intersecting this line with a horizontal line that originated from the centre of the femoral head. Zones 1 and 2 were partially modified with respect the original model as they were divided by a second line drawn from the centre of the femoral head to the lower part of the sacroiliac joint.

on each scan for every ROI at each follow-up. The BMD values measured at 7 days were used as baselines.

Statistical analysis

An independent blinded statistical analysis was performed using the SAS JMP software. The normality of the quantitative variables was assessed with Shapiro-Wilk test. The data dis-

tribution 3rd found to be non-Gaussian; therefore, medians and percentiles (25° and 75°) were used as measures of the central tendency and dispersion, and $p < 0.05$ was used as the threshold for statistical significance. Specific nonparametric tests were applied: the Mann-Whitney *U*-test to compare 2 groups, the Kruskal-Wallis test to compare 3 or more groups and the Wilcoxon signed-rank test to compare ante-post data belonging to 2 groups. Correlation analysis was performed to determine whether the values of 2 numerical variables were associated. χ^2 tests and Fisher’s exact tests were used to analyse the qualitative variables.

Results

Densitometric analysis

After an initial decrease in BMD values from baseline at 7 days to 6 months, the BMD slightly increased in ROI I and stabilised in ROI III. The BMD in ROI II increased after 12 months and stabilised at 24 months (Tab. I, Fig. 2).

The variations in the BMD of the acetabular area were found to be statistically influenced primarily by the patient’s BMI (Tab. II); a statistically significant increase was observed for the patients with BMI ≥ 25 , particularly in ROIs I and II ($p < 0.05$, Mann-Whitney *U*-test). Gender was also found to affect bone remodelling (Tab. III), particularly in ROIs II and III; greater BMD changes were observed in men than in women in all ROIs. No statistically significant correlation was observed between BMD and the patient work status (retired/working; $p < 0.05$, Mann-Whitney *U*-test) and between BMD and the coupling material ($p < 0.05$, Kruskal-Wallis Test). A statistically significant correlation between BMD and age was observed but was limited to ROI III ($p < 0.05$, Mann-Whitney *U*-test) in patients with age < 65 years (Tab. IV).

Clinical outcomes

The median (IQR) HHS improved from 48 (39-62) before surgery to 99 (96-100) at 24 months (Tab. V). HHS outcomes were considered to be ‘excellent’ (90-100) in 73 (90.1%)

TABLE I - Median (IQR) bone mineral density (BMD, g/cm^2) results divided according to single regions of interest (R1-3) and as the total BMD across the 3 ROIs (BMD NET)

	1 week n = 91	3 months n = 85	6 months n = 84	12 months n = 83	24 months n = 81
BMD R1 (g/cm^2)	1.44w (1.21-1.67)	1.31 (1.05-1.55)	1.27 (1.08-1.52)	1.29 (1.12-1.52)	1.30 (1.11-1.55)
<i>p</i> -value	-	$< 0.0001^*$	$< 0.0001^*$	0.0002^*	0.0001^*
BMD R2 (g/cm^2)	1.23 (0.99-1.49)	1.16 (1.88-1.40)	1.14 (0.89-1.37)	1.07 (0.90-1.30)	1.12 (0.96-1.36)
<i>p</i> -value	-	0.0645	0.0043*	0.0001*	0.0098*
BMD R3 (g/cm^2)	1.11 (0.85-1.48)	1.05 (0.72-1.33)	1.05 (0.73-1.35)	1.06 (0.76-1.31)	1.04 (0.80-1.25)
<i>p</i> -value	-	0.0094^*	0.0020^*	0.0114^*	0.0230^*
BMD NET (g/cm^2)	1.30 (1.12-1.53)	1.22 (1.01-1.41)	1.20 (1.00-1.39)	1.17 (1.02-1.37)	1.17 (1.05-1.40)
<i>p</i> -value	-	$< 0.0001^*$	$< 0.0001^*$	$< 0.0001^*$	$< 0.0001^*$

* statistically significant ($p < 0.05$), Wilcoxon signed-rank test.
n = number of implants; ROIs = regions of interest.



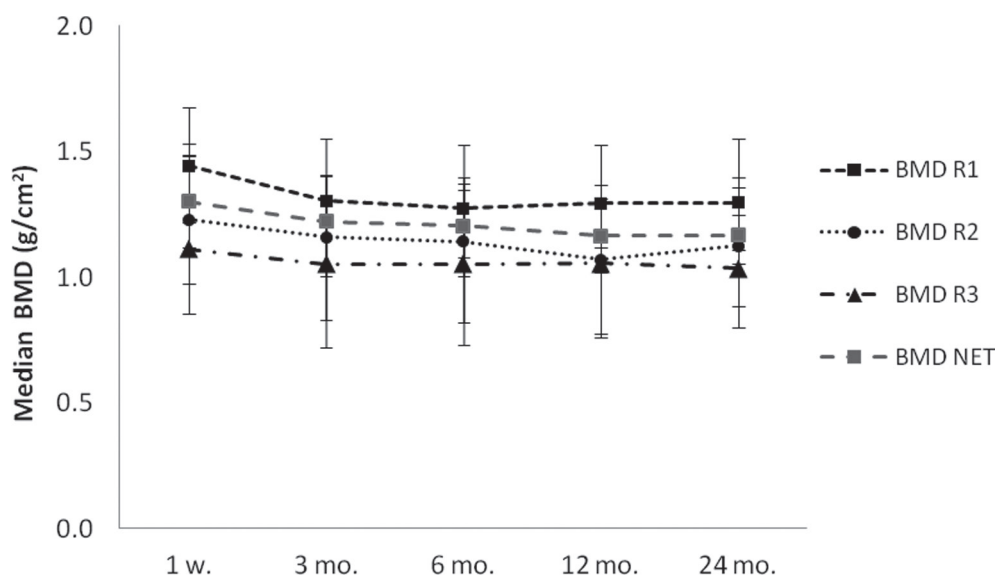


Fig. 2 - Median (IQR) Bone Mineral Density (BMD, g/cm²) outcomes divided according to single regions of interest (R1-3) and as the total BMD across the 3 ROIs (BMD NET).

TABLE II - Outcomes (p-value) of the analysis to assess the statistical significance of the correlation between bone mineral density (BMD) vs. BMI sub-groups (Group A: BMI <25 Kg/m²; Group B: BMI ≥25 Kg/m²)

	1 week n = 91	3 months n = 85	6 months n = 84	12 months n = 83	24 months n = 81
BMD R1	0.0696	0.0737	0.0300*	0.0149*	0.0074*
BMD R2	0.8580	0.4057	0.8961	0.2351	0.0316*
BMD R3	0.9558	0.3438	0.8832	0.5378	0.5216
BMD NET	0.1625	0.0603	0.2336	0.0430*	0.0088*

A p-value < 0.05 (Mann-Whitney U-test) indicates a statistically significant correlation (*).
BMI = body mass index; n = number of implants.

TABLE III - Analysis to assess the statistical significance of the correlation between bone mineral density (BMD) vs. Gender sub-groups (Group A: male patients; Group B: female patients)

	1 week n = 91	3 months n = 85	6 months n = 84	12 months n = 83	24 months n = 81
BMD R1	0.0344*	0.1133	0.4352	0.0614	0.1594
BMD R2	0.0011*	0.0090*	0.0992	0.0128*	0.0244*
BMD R3	<0.0001*	<0.0001*	<0.0001*	<0.0001*	<0.0001*
BMD NET	<0.0001*	0.0011*	0.0052*	0.0003*	0.0021*

A p-value < 0.05 (Mann-Whitney U-test) indicates a statistically significant outcome (*).
n = number of implants.

cases, 'good' (80-89) in 5 (6.2%), 'fair' (70-79) in 2 (2.5%) and 'very poor' (<60) in 1 (1.2%) case at the last follow-up. The 3 cases whose HHS outcomes were classified as 'fair' or 'very poor' experienced painful postoperative complications that were not related to the acetabular cups being evaluated in this study. 1 'fair' case was due to a periprosthetic fracture in the contralateral hip after a 1st revision surgery that was followed by complications. The contralateral implant was not part of this investigation. The 2nd 'fair' outcome was

influenced by intense back pain due to spondyloarthritis that resulted in limited functional recovery. The 'very poor' case was undergoing trochanteric bursitis infiltration in response to the persistence of painful symptoms. At the last follow-up visit, this patient's conditions seemed unresponsive to medical therapy. The median (IQR) SF-36 total increased from 49 (37-62) preoperatively to 86 (79-92) at 24 months (Tab. V). In terms of both HHS and SF-36, patient recovery was statistically influenced by gender and age; higher clinical scores were

TABLE IV - Analysis to assess the statistical significance of the correlation between bone mineral density (BMD) vs. Age sub-groups (Group A: patients with age <65 years old; Group B: patients with age ≥65 years old)

	1 week n = 91	3 months n = 85	6 months n = 84	12 months n = 83	24 months n = 81
BMD R1	0.7823	0.9208	0.5142	0.6258	0.8017
BMD R2	0.6908	0.7317	0.8016	0.1969	0.3201
BMD R3	0.4792	0.1063	0.0861	0.0419*	0.0026*
BMD NET	0.6542	0.5610	1.000	0.5479	0.2982

A p -value <0.05 (Mann-Whitney U-test) indicates a statistically significant outcome (*).
n = number of implants.

TABLE V - Median (IQR) Harris hip score (HHS) and median (IQR) SF-36 outcomes at the preoperative visit and postoperatively at 7 days and at 3, 6, 12 and 24 months

	Preop. n = 91	1 week n = 91	3 months n = 85	6 months n = 84	12 months n = 83	24 months n = 81
HHS Total score	47.7 (38.6-61.7)	51.8 (44.6-68.3)	87.9 (81.3-93.0)	95.7 (89.9-99.8)	99.0 (93.0-100.0)	99.4 (96.0-100.0)
p -value	-	0.0003*	<0.0001*	<0.0001*	<0.0001*	<0.0001*
SF-36 Total score	48.6 (37.2-62.2)	47.3 (44.2-57.9)	78.6 (69.9-86.5)	85.5 (71.8-90.8)	85.8 (76.1-91.0)	86.4 (78.8-91.5)
p -value	-	0.5613	<0.0001*	<0.0001*	<0.0001*	<0.0001*

* statistically significant (p <0.05), Wilcoxon signed-rank test.
n = number of implants.

recorded for men than women and for patients <65 years compared to older patients (p <0.05, Mann-Whitney *U*-test). Neither implant-related complications nor cup failures were observed. 2 dislocations were reported; 1 was resolved with closed reduction, and the other was resolved with a revision of the neck and head. All cups were stable at the final follow-up, and no revisions were performed.

Radiographic assessment

Postoperatively, the median cup inclination angle was 42° (39°-47°). No cases of loosening and radiolucent lines and no osteolytic areas were observed. After 2 years, 29 (35.8%) cases of heterotopic ossifications were confirmed, and 84% of these cases have already been observed at 3 months. 24 (29.6%) cases were identified as non-progressive Brooker class I, 3 (3.7%) as class II and 2 (2.5%) as class III. No statistically significant correlations were observed between the formation of heterotopic ossifications and the different surgical approaches used (X^2 test), as reported in previous literature (17, 18).

Discussion

Several in vitro and in vivo studies have reported promising data regarding the osteoinductive and osteoconductive properties of Trabecular Titanium. This biomaterial has been shown to significantly affect osteoblast attachment, proliferation and infiltration while inhibiting osteoclastogenesis (19-23). In vitro experiments have demonstrated that human adipose

stem cells (hASCs) grown on this cellular solid scaffold in the absence of osteogenic factors are able to adhere, proliferate and differentiate into an osteoblast-like phenotype (19). Concomitant deposition of a calcified extracellular bone matrix has been observed on this construct surface, proving thus its effectiveness in regenerating damaged bone tissue (19-23). Furthermore, in vivo analysis of the osseointegrative potential of Trabecular Titanium in a sheep model revealed high bone in-growth percentages in both cancellous (+68%) and cortical bone (+87%) (20). The aim of this investigation was to determine whether Trabecular Titanium combines the mechanical advantages of titanium alloys with the properties of a highly porous cellular solid.

Levenston et al (9) reported that an analysis of simulated stress-related bone remodelling around cementless acetabular components has estimated a bone loss up to 50% in the medial zone (ROI II) and BMD increases of up to 30% in the regions of the periacetabular rim (9, 10). Periacetabular BMD has been observed to vary in most DEXA studies with a similar trend: after an initial BMD fall in the immediate postoperative analysis, a slight increase or stabilisation has been recorded, especially in ROI I and III, which was attributed to rim loading (11, 24-31).

In our study, after an initial fall in periacetabular BMD in the first 3 months, all ROIs exhibited progressive stabilisation or slight recovery around the DELTA-TT cups. These findings are consistent with the majority of BMD outcomes that are reported in the literature (11, 24-35). For instance, Periasamy et al (11) described similar results on Trabecular Metal acetabular components. They reported greater load transfer at

the lateral peripheral rim with these monoblock cups compared to traditional cemented cups. They suggested that the observed retro-acetabular stress shielding was simply a remodelling response that represented a successful adaptation of the medial cancellous bone to the reduced load transfer at the bone-implant interface.

During the course of the present study, variations in bone mineral density were found to be primarily influenced by the patient's BMI and gender; statistically significant increases were found for the male patients and those with BMI ≥ 25 . Correlations of bone remodelling with the patient's BMI (29, 30, 33) and gender (24, 28, 30) have also been confirmed in other studies in which both female patients and patients with low BMI exhibited reduced abilities to recover BMD after THA. These findings can be explained by the fact that women generally have lower bone density than men and bone remodelling phenomena have been correlated with higher BMI due to greater load transfer. In terms of the different bone remodelling patterns observed across the 3 acetabular areas (i.e. ROIs), our results also corroborate the data reported in the literature according to the DeLee and Charnley model (16), although no detailed explanations have been provided regarding the specific effects of BMI, age and gender on the postoperative BMD recovery in the 3 different ROIs. In the context of the available literature, statistically significant changes have also been observed in ROIs 2 and 3 in the works of Sabo et al (24) and Kim et al (30) that evaluated the effects of gender on bone remodelling over time. ROI 1 has been observed to be the acetabular region that was most affected by the patient's BMI in the present study, as well as in the previous work by Kim et al (30). Valancius et al (25) inferred that this acetabular area was the most affected in terms of BMD changes because it is the area to which the greatest proportion of the load is transferred. In contrast to other works (26, 28, 30), in the present study, a statistically significant correlation was identified between the BMD change in ROI III and the patient's age ($p < 0.05$, Mann-Whitney *U*-test). However, this result could easily be attributable to the higher levels of physical activity of younger patients and the consequently higher load transfer on the hip joint. No statistically significant correlation was observed between the material of the bearing couplings and the BMD values in our study, as already reported in the works by Kim et al (30) and Gauthier et al (36). These authors found no differences in BMD recovery following THA with either ceramic, metal or polyethylene couplings.

All of the DELTA-TT cups resulted radiographically stable with no signs of radiolucent lines. The macro-porous structure of Trabecular Titanium generates in fact a high coefficient of friction (12), which furthers a firm mechanical interlocking at the implant-bone interface, thus reducing the risk of micromotions. The clinical and subjective patient results were satisfactory and indicated functional improvements and a complete patient recovery. Neither implant-related complications nor revisions were recorded.

This study design has some limitations because it is non-comparative and nonrandomised. Additionally, the DEXA scan is a bi-dimensional technique and thus cannot appropriately measure bone mineral density in the acetabular areas that are covered by the cup. Clinical outcomes have been satisfactory in the present study, which might have been expected

given the short-term follow-up. They are comparable to those that have been reported in other studies of cementless acetabular cups (11, 24-35).

Conclusions

After an initial reduction in the BMD around the DELTA-TT cup, all of the regions of interest exhibited stabilization or slight recovery, and these findings are similar to those of other reports in the literature related to cementless acetabular components. Although clinical outcomes, functional recovery and implants stability proved satisfactory, longer follow-ups are necessary to assess the long-term survivorship of this acetabular cup.

Acknowledgements

Lima Corporate acted as the sponsor of the clinical investigation.

Disclosures

Financial support: This investigation was sponsored by Lima Corporate.

[AUTHOR: please provide initials of the author and replace X and Y (leave periods)]

Conflict of interest: X.Y. was consultant for Lima Corporate.

All other authors: None.

References

1. Yamada H, Yoshihara Y, Henmi O, et al. Cementless total hip replacement: past, present, and future. *J Orthop Sci.* 2009;14(2):228-241.
2. Macheras GA, Papagelopoulos PJ, Kateros K, Kostakos AT, Baltas D, Karachalios TS. Radiological evaluation of the metal-bone interface of a porous tantalum monoblock acetabular component. *J Bone Joint Surg Br.* 2006;88(3):304-309.
3. Frosch KH, Barvencik F, Viereck V, et al. Growth behavior, matrix production, and gene expression of human osteoblasts in defined cylindrical titanium channels. *J Biomed Mater Res A.* 2004;68(2):325-334.
4. Karageorgiou V, Kaplan D. Porosity of 3D biomaterial scaffolds and osteogenesis. *Biomaterials.* 2005;26(27):5474-5491.
5. Marin E, Fusi S, Pressacco M, Paussa L, Fedrizzi L. Characterization of cellular solids in Ti6Al4V for orthopaedic implant applications: [Trabecular titanium](#). *J Mech Behav Biomed Mater.* 2010; 3(5):373-381.
6. Dalla Pria P, Pressacco M, Veronesi E. Nuove frontiere nell'osteointegrazione: il Trabecular Titanium™. *Sphera Med J.* 2008;7:46-50.
7. Meneghini RM, Ford KS, McCollough CH, Hanssen AD, Lewallen DG. Bone remodeling around porous metal cementless acetabular components. *J Arthroplasty.* 2010;25(5):741-747.
8. Kröger H, Miettinen H, Arnala I, Koski E, Rushton N, Suomalainen O. Evaluation of periprosthetic bone using dual-energy x-ray absorptiometry: precision of the method and effect of operation on bone mineral density. *J Bone Miner Res.* 1996;11(10): 1526-1530.
9. Levenston ME, Beaupré GS, Schurman DJ, Carter DR. Computer simulations of stress-related bone remodeling around non-cemented acetabular components. *J Arthroplasty.* 1993;8(6): 595-605.
10. Wilkinson JM, Peel NF, Elson RA, Stockley I, Eastell R. Measuring bone mineral density of the pelvis and proximal femur after total hip arthroplasty. *J Bone Joint Surg Br.* 2001;83(2):283-288.

[AUTHOR: Please provide the volume number, issue number, ref. 22]



11. Periasamy K, Watson WS, Mohammed A, et al. A randomised study of peri-prosthetic bone density after cemented versus trabecular fixation of a polyethylene acetabular component. *J Bone Joint Surg Br.* 2011;93(8):1033-1044.
12. Marin E, Fedrizzi L, Regis M, Pressacco M, Zagra L, Fusi S. Stability enhancement of prosthetic implants: friction analysis of Trabecular Titanium. *Hip Int.* 2012;22(4):427-428.
13. Harris WH. Traumatic arthritis of the hip after dislocation and acetabular fractures: treatment by mold arthroplasty. An end-result study using a new method of result evaluation. *J Bone Joint Surg Am.* 1969;51(4):737-755.
14. Brazier JE, Harper R, Jones NM, et al. Validating the SF-36 health survey questionnaire: new outcome measure for primary care. *BMJ.* 1992;305(6846):160-164.
15. Brooker AF, Bowerman JW, Robinson RA, Riley LH Jr. Ectopic ossification following total hip replacement. Incidence and a method of classification. *J Bone Joint Surg Am.* 1973;55(8):1629-1632.
16. DeLee JG, Charnley J. Radiological demarcation of cemented sockets in total hip replacement. *Clin Orthop Relat Res.* 1976;(121):20-32.
17. Schara K, Herman S. Heterotopic bone formation in total hip arthroplasty: predisposing factors, classification and the significance for clinical outcome. *Acta Chir Orthop Traumatol Cech.* 2001;68(2):105-108.
18. Morrey BF, Adams RA, Cabanela ME. Comparison of heterotopic bone after anterolateral, transtrochanteric, and posterior approaches for total hip arthroplasty. *Clin Orthop Relat Res.* 1984;(188):160-167.
19. Benazzo F, Botta L, Scaffino MF, et al. Trabecular titanium can induce in vitro osteogenic differentiation of human adipose derived stem cells without osteogenic factors. *J Biomed Mater Res A.* 2014;102(7):2061-2071.
20. Devine D, Arens D, Burelli S, Bloch HR, Boure L. In vivo evaluation of the osteointegration of new highly porous Trabecular Titanium™. *J Bone Joint Surg Br.* 2012;94-B(Suppl XXXVII):201.
21. Sollazzo V, Massari L, Pezzetti F, et al. Genetic effects of Trabecular Titanium™ on MG-63 cell line: a genetic profiling evaluation. *ISRN Mater Sci.* 2011:392763.
22. Asti A, Gastaldi G, Dorati R, et al. Stem Cells Grown in Osteogenic Medium on PLGA, PLGA/HA, and Titanium Scaffolds for Surgical Applications. *Bioinorg Chem Appl.* 2010;831033.
23. Gastaldi G, Asti A, Scaffino MF, et al. Human adipose-derived stem cells (hASCs) proliferate and differentiate in osteoblast-like cells on trabecular titanium scaffolds. *J Biomed Mater Res A.* 2010;94(3):790-799
24. Sabo D, Reiter A, Simank HG, Thomsen M, Lukoschek M, Ewerbeck V. Periprosthetic mineralization around cementless total hip endoprosthesis: longitudinal study and cross-sectional study on titanium threaded acetabular cup and cementless Spotorno stem with DEXA. *Calcif Tissue Int.* 1998;62(2):177-182.
25. Valancius K, Søballe K, Nielsen PT, Laursen MB. No superior performance of hydroxyapatite-coated acetabular cups over porous-coated cups. *Acta Orthop.* 2013;84(6):544-548.
26. Korovessis P, Piperos G, Michael A, Baikousis A, Stamatakis M. Changes in bone mineral density around a stable uncemented total hip arthroplasty. *Int Orthop.* 1997;21(1):30-34.
27. Digas G, Kärrholm J, Thanner J. Different loss of BMD using uncemented press-fit and whole polyethylene cups fixed with cement: repeated DXA studies in 96 hips randomized to 3 types of fixation. *Acta Orthop.* 2006;77(2):218-226.
28. Shetty NR, Hamer AJ, Kerry RM, Stockley I, Eastell R, Wilkinson JM. Bone remodelling around a cemented polyethylene cup. A longitudinal densitometry study. *J Bone Joint Surg Br.* 2006;88(4):455-459.
29. Laursen MB, Nielsen PT, Søballe K. Bone remodelling around HA-coated acetabular cups: a DEXA study with a 3-year follow-up in a randomised trial. *Int Orthop.* 2007;31(2):199-204.
30. Kim YH, Yoon SH, Kim JS. Changes in the bone mineral density in the acetabulum and proximal femur after cementless total hip replacement: alumina-on-alumina versus alumina-on-polyethylene articulation. *J Bone Joint Surg Br.* 2007;89(2):174-179.
31. Kim YH. The results of a proximally-coated cementless femoral component in total hip replacement: a five- to 12-year follow-up. *J Bone Joint Surg Br.* 2008;90(3):299-305.
32. Huang Q, Shen B, Yang J, Zhou ZK, Kang PD, Pei FX. Changes in bone mineral density of the acetabulum and proximal femur after total hip resurfacing arthroplasty. *J Arthroplasty.* 2013;28(10):1811-1815.
33. Baad-Hansen T, Kold S, Nielsen PT, Laursen MB, Christensen PH, Soballe K. Comparison of trabecular metal cups and titanium fiber-mesh cups in primary hip arthroplasty: a randomized RSA and bone mineral densitometry study of 50 hips. *Acta Orthop.* 2011;82(2):155-160.
34. Penny JO, Brixen K, Varmarken JE, Ovesen O, Overgaard S. Changes in bone mineral density of the acetabulum, femoral neck and femoral shaft, after hip resurfacing and total hip replacement: two-year results from a randomised study. *J Bone Joint Surg Br.* 2012;94(8):1036-1044.
35. Field RE, Cronin MD, Singh PJ, Burtenshaw C, Rushton N. Bone remodeling around the Cambridge cup: a DEXA study of 50 hips over 2 years. *Acta Orthop.* 2006;77(5):726-732.
36. Gauthier L, Dinh L, Beaulé PE. Peri-acetabular bone mineral density in total hip replacement. *Bone Joint Res.* 2013;2(8):140-148.