

Eradication of Hairy Mouth After Oncological Resection of the Tongue and Floor Mouth Using a Diode Laser 808 nm Postoperative Pain Assessment Using Thermal Infrared Imaging

Antonio Scarano, DDS, MD ^{1,*}, Felice Lorusso, DDS,¹ Alessandro Di Cerbo, DBT,^{1,2} Alberta Greco Lucchina, DDS,^{2,3} and Francesco Carinci, MD, DDS⁴

¹Department of Medical, Oral and Biotechnological Sciences and CeSi Met, University of Chieti-Pescara, Chieti, Italy

²Department of Life Sciences, University of Modena and Reggio Emilia, Modena, Italy

³University of Eastern Piedmont, Novara, and Oral Surgery Unit, Regina Margherita Pediatric Hospital, Turin, Italy

⁴Department of Morphology, Experimental Medicine and Surgery, University of Ferrara, Ferrara, Italy

Objectives: Vascularized soft tissue flaps are often harvested from hair-bearing areas, such as the radial forearm or anterolateral thigh, making their use in oral reconstruction problematic due to postoperative hair growth. The presence of intact hair follicles in free tissue transfer and continued hair growth at the recipient site can result in difficulties with oral hygiene, intraoral irritation, food trapping, and patient distress. This study was to evaluate the intraoral efficacy and safety of a diode laser 808 nm when used for hair removal.

Materials and Methods: Sixteen male patients, between 2010 and 2017, were referred for intraoral hair eradication with a history of squamous cell carcinoma of the tongue or floor mouth resection. An 808 nm diode laser (Stark 808, Plume s.r.l., Rome, Italy) was used to remove the intraoral hair. Each patient received a total of six treatments at 4-week intervals. Perifollicular pain was quantified by the physician using visual analog scales. Follow-up visits were scheduled at 1, 4, and 6 days to check the state of the tissues. The recall program included assessments of VAS, erythema, and perifollicular temperature. Patients were followed up for long-term assessments at 6 and 12 months after the final treatment session.

Results: All patients presented well with no occurrence of symptoms, indicating possible perifollicular inflammation. Based on the VAS scores, very mild discomfort during laser irradiation was recorded in all patients, with average pain score of 10.98 ± 1.42 . No pain or discomfort was recorded 1, 4, and 6 days after the procedure. After the third pulse of light was applied, the average temperature with standard deviation of the hair tip with both the dark and light skin was $74.4 \pm 11.7^\circ\text{C}$. The difference in temperature before the procedure (basal measurement $37.5 \pm 2.8^\circ\text{C}$) and immediately after laser irradiation was $36.9 \pm 3.7^\circ\text{C}$. The difference in temperature disappeared after 0.29 seconds, and no temperature increase was recorded on days 1, 4, or 6. In all the patients, the hair clearance between baseline and the 6th treatment, the 6-month follow-up, and the 12-month

follow-up rated as significant $P < 0.05$. The mean percentage of hair reduction was 97.3% at 12 months.

Conclusion: In conclusion, the clinical findings demonstrate the safety and efficacy of the 808 nm diode laser system for intraoral hair removal *Lasers Surg. Med.* 51:516–521, 2019. © 2018 Wiley Periodicals, Inc.

Key words: oral reconstruction; intraoral hair; diode laser 808 nm; oral cancer

INTRODUCTION

Surgical resection of oral cancer requires that the defect needs to be covered with a cutaneous flap. Different techniques and methods have been used for reconstructing intraoral tissues and tongue after oncological resection. Currently, fasciocutaneous flaps are used, such as the anterolateral thigh flap or the free radial forearm flap in the reconstruction of intraoral soft tissue [1].

Free tissue transfer for mouth tissue reconstruction in oncological patients has become the first rung on the reconstructive ladder which achieves both functional and aesthetic restorations.

It is harvested with an accompanying skin paddle, which is placed intraorally to fill soft tissue defects. The

Conflict of Interest Disclosures: All authors have completed and submitted the ICMJE Form for Disclosure of Potential Conflicts of Interest and none were reported.

Statement of Clinical Relevance: This article highlights the effectiveness of the 808 nm diode laser in intraoral hair eradication. It induces a rapid healing of the treated area, minimal pain, a rapid resolution of the erythema as well as few and short-lived untoward effects.

*Correspondence to: Antonio Scarano, DDS, MD, Department of Medical, Oral and Biotechnological Sciences, University of Chieti-Pescara, Via Dei Vestini 31, 66100 Chieti, Italy. E-mail: ascarano@unich.it

Accepted 8 December 2018

Published online in Wiley Online Library

(wileyonlinelibrary.com).

DOI 10.1002/lsm.23054

epidermis of flap could undergo metaplastic transformation to mucosal epithelium, but in some patients producing intraoral hypertrichosis [2].

In fact today, the overall consensus is that skin flaps retain their epidermal architecture years after oral reconstruction [3–5]. Many clinical situations require a postoperative radiation therapy that results in epilation, but not all tumors require radiation therapy. Intraoral hirsutism as a consequence of reconstruction with skin flaps can be problematic.

The undesirable intraoral hair causes trapping of saliva and food, difficulty with oral hygiene, halitosis, irritation, gagging, and intermittent dysphagia [6,7]. Postoperative laser therapy has been prescribed for intraoral de-epithelialization.

In this study, the intraoral efficacy and safety of an 808 nm diode laser was evaluated when used for hair removal. This involved a clinical evaluation of erythema and pain during hair removal, assessed through infrared thermal imaging (i.e., thermography) and the visual analog scale.

MATERIALS AND METHODS

Sixteen patients, between 2010 and 2017, were referred to the Department of Oral Surgery of the University of Chieti-Pescara by their doctors for intraoral hair eradication, having a history of squamous cell carcinoma of the tongue and floor mouth resection. There was no postoperative radiotherapy. Intraoral examination in each of the patients showed coarse, terminal hairs of the reconstructed floor of the mouth and tongue. The color of the hairs prior to treatment was black in all patients (Fig. 1). All patients reported halitosis, bothersome intraoral sensations, difficulty with eating, irritation of mucosae, and swallowing. These clinical signs diminished the quality of life because of intraoral hair growth.

The authors treated 16 male patients for the removal of intraoral hair. Patient ages ranged between 43 and 64 years. An 808 nm diode laser (Stark 808, Plume s.r.l., Rome, Italy) was used to remove the intraoral hair. The laser used in the present study with a spot size of

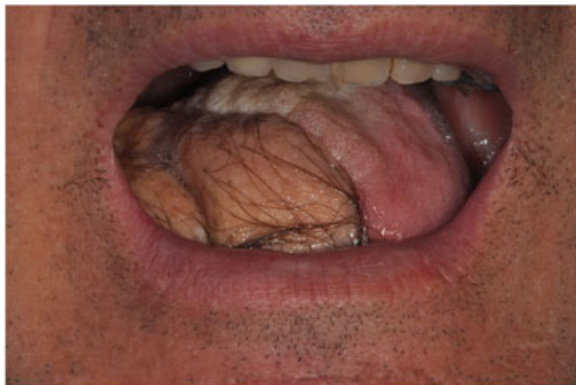

Fig. 1. Patient's tongue and floor mouth after free tissue transfer from radial forearm. Many hairs were present on the tongue and floor mouth.

0.5 mm × 0.5 mm does not have a cooling system. All patients provided written consent to undergo intraoral hair removal with diode laser 808 nm. Each patient received a total of six treatments at 4-week intervals. During each treatment session, the intraoral tissues were treated once with the 808 nm linear-scanning diode laser using a fluence of 24–30 J/cm², a pulse duration of 12 millisecond with a tip and a spot size of 0.5 mm × 0.5 mm. We targeted individual hairs with three consecutive deposition of energy. A lidocaine spray 15% (OGNA Lab S.r.l, Monza, Italy) was used for superficial anesthetics before each treatment. To deliver the energy safely and consistently with good visualization in the deeper oral cavity, with the conventional handpiece, the tongue and the tissues were moved forcefully using a small mirror.

After treatment, the subjects were alerted to avoid eating hot food for 1 day. Intraoral hair density was assessed at baseline, before each treatment and at each follow-up visit using the automatic software package with image-capturing capabilities, then recorded using a Sony α330 digital camera and subjected to morphometric analysis using digital image-analysis (NIS-Elements AR 3.0 software, Nikon, Minato, Japan). When the images are loaded onto a computer, this software analyzes hair density (n/cm²). Perifollicular pain was quantified by the physician using visual analog scales [8].

Pain intensity was classified into four categories. Postoperative pain was scored by means of a 100-mm VAS from 0 (no pain) to 100 (worst pain imaginable) at 1-, 4-, and 6-day intervals. Erythema was classified into four categories: number 1 stands for the absence of erythema, patients with a perifollicular erythema extending for 1 mm scored 2, patients with a perifollicular erythema extending for 2 mm scored 3, and intense erythema exhibited by perifollicular and erythema extending beyond 3 mm in the treated zone scored 4 [9].

During the control visits after 3 and 12 months, the patients were asked to complete a survey based on the validated Global Aesthetic Improvement Scale (GAIS):

- Grade 3: Excellent (the patient is completely satisfied with the result).
- Grade 2: Very good (the patient is very satisfied with the result).
- Grade 1: Satisfactory (although the patient sees slight improvement, additional correction is required).
- Grade 0: Indifferent (the patient sees no changes).
- Grade –1: Unsatisfied (the patient's condition is worse than before the procedure).

Follow-up visits were scheduled at 1, 4, and 6 days to check the state of tissues. The recall program included assessments of VAS, erythema, and perifollicular temperature assessment. Patients were followed up for long-term assessments at 6 and 12 months after the final treatment session.

Temperature Measurements

Thermal measurements were performed in a climate-controlled room (temperature: 22–24°C, relative humidity:

$50 \pm 5\%$, with no direct ventilation into mouth of patients). Perifollicular temperature of the treated side was obtained using a 14-bit digital infrared camera (FLIR SC660 QWIP, Flir Systems, Danderyd, Sweden). The acquisition parameters were as follows: 320×240 pixels focal plane array; $8\text{--}9\ \mu\text{m}$ spectral range; 0.02 K noise equivalent temperature differences (NETDs); 50-Hz sampling rate; optics: germanium lens; $f20$; and $f/1.5$. The camera was set 0.50 m away from the mouth for maximum spatial resolution. Images were acquired at a rate of 10 images per second and subsequently re-aligned using an edge-detection based method implemented with in-house software. A video was performed, and the photos were extrapolated via dedicated software. Temperature changes in the perifollicular were computed on the realigned thermal images. Thermographic data analysis was performed using FLIR QuickReport v.1.2 (FLIR Systems Inc., North Billerica, MA), which includes a tool to obtain maximum, minimum, and average temperature of a perifollicular area.

Statistical Evaluation

To evaluate the differences in the VAS, erythema, and perifollicular temperature before and after treatment, one-way ANOVA statistical analysis was used. A value of $P \leq 0.05$ was considered to be statistically significant. Data treatment and statistical analysis were done by Excel (Microsoft Excel, Redmond, WA) Origin (OriginLab, Northampton, MA), and SPSS software (IBM, Armonk, NY).

The hair density at baseline, 6 months, and 12 months was also recorded and evaluated. The intergroups experimental time differences were analyzed by one-way analysis of variance (ANOVA) followed by Newman–Keuls post-hoc test. A P -value < 0.05 was considered statistically significant.

RESULTS

All patients presented well with no occurrence of symptoms, indicating possible perifollicular inflammation.

Based on the VAS scores, very mild discomfort during laser irradiation was reported in all patients with average pain score of 10.98 ± 1.42 . No pain or discomfort was recorded 1, 4, and 6 days after the procedure. No statistical difference was recorded before and after laser irradiation ($P < 0.5$). No erythema was recorded at 1, 4, and 6 days. No outbreaks of herpes, hypopigmentation, ecchymosis, hyperpigmentation, erythema, itching, infectious processes, or scarring were observed. Erythema, as a typical sign of heat application to the superficial mucosa, was present to a minimal extent only with an average 1.2 ± 0.99 immediately after laser irradiation and was absent at 1, 4, and 6 days after.

After the third pulse of light was applied, the average temperatures with standard deviation of the hair tip with both the dark and light mucosae were $74.4 \pm 11.7^\circ\text{C}$. The difference in temperature before the procedure (basal measurement $37.5 \pm 2.8^\circ\text{C}$) $37.5 \pm 2.8^\circ\text{C}$ and immediately after laser irradiation was $36.9 \pm 3.7^\circ\text{C}$ (Figs. 2 and 3). The difference in temperature disappeared after 0.29 seconds.

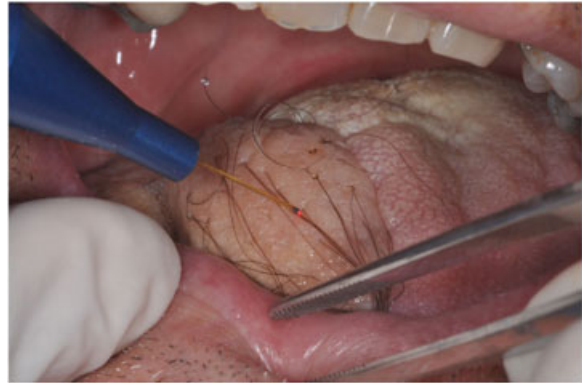


Fig. 2. Handpiece of the laser devices with a tip and a spot size of $0.5\ \text{mm} \times 0.5\ \text{mm}$ for targeting individual hairs. Photographs demonstrate laser handpiece size.

Average hair densities at baseline were 15.91 ± 2.90 per cm^2 . The hair densities decreased with each subsequent treatment session, with a statistically significant difference before and after laser treatment. After laser epilation protocols, a total removal of hair growth at the 6-month follow-up visit was observed, only in a few areas was it possible to observe a single hair (Figs. 4 and 5).

The overall hair clearance at 12 months showed a reduction to 0.4 ± 0.22 hairs/ cm^2 . All the patients rated the hair clearance between baseline and the 6th treatment, the 6-month follow-up, and the 12-month follow-up as significant (Fig. 6). A statistical difference was recorded between the group at baseline and the one at 6 months after the treatment ($P < 0.1$), also between baseline and at 12 months after laser therapy ($P < 0.1$).

No statistical differences in hair reduction were evident between the examinations at 6 months and 12 months from the treatment ($P > 0.5$).

Among the 16 patients treated with the diode laser, none referred to be unsatisfied or indifferent during the course of the treatment and a Grade 3 of GAIS was recorded. In fact, the number of patients that referred an “excellent” outcome, was 12 at 6 months and 16 at 12 months. A total of six sections of laser irradiation in 6 months was needed for total eradication of hair. The mean percentage hair reduction was 97.3% at 12 months.

DISCUSSION

The outcome of this study shows a statistical difference in mouth hair density before and after 808 nm diode laser treatment. A statistical difference was observed in hair densities after six subsequent treatment sessions. This result shows the efficacy of the 808 nm diode laser treatment against hair growth. The treatment used in the present study improved the quality of life of the patients operated for tumors; in fact, the presence of hair in the mouth causes annoyance due to the trapping of food, collection of saliva, tickling, and gagging. The diode laser hair removal system involves a beam of concentrated light and heat that is directed into the melanin contained in the hair follicles.




Fig. 3. (A) Measuring body temperature with infrared thermal camera during laser section. (B) The temperature disappeared after 0.29 seconds. The dimensions of the image are $11.8 \times 12.7 \times 7.2$ mm, while the spatial resolution of the interrogation area is 320×240 pixels.

As in previously reported cases, the diode laser 808 nm was chosen for the hair removal procedure because of its ability to selectively target the chromophore melanin and its safety profile [10]. The melanin pigment absorbs the diode laser energy and is shattered, inhibiting hair growth in the affected hair follicles. A critical requirement of photo-epilation is to cause maximum temperature rise in the hair follicle while keeping the temperature of the epidermis under damage threshold [11]. Hair follicle is completely shattered at 65°C [12]. The laser energy is directed at these follicles while simultaneously protecting the surrounding mucosae from harm.

Oral cancer is a malignant neoplasia, which arises in the oral cavity or on the lip with high risk of metastases to lymph nodes in the neck [13], histologically originating in the squamous cells [14]. After surgical cancer removal, there is a deficit of tissues in the mouth and different techniques are used for reconstructing intraoral soft defects. The vascularized soft tissue flaps are often harvested from hair-bearing areas, such as the radial forearm or anterolateral thigh, making their use in oral reconstruction problematic due to postoperative hair growth. These techniques used for soft tissue reconstruction in the mouth must allow for restoring speech and

swallowing function and aesthetically acceptable tissue repair. The hair-bearing nature of the skin donor site in men, complicates use of the flaps in the mouth due to difficulties with chewing, oral hygiene and swallowing, and aesthetics, because hair continues to grow in the mouth [15]. Despite flaps becoming mucosalized for most patients, however, a major concern remains the presence hair in the mouth.

The laser therapies were proposed for hair removal since its introduction in aesthetic medicine [16] for hair removal in different areas of the human body. Different lasers have been proposed successfully, including the long-pulse diode (810, 755, 1060 nm) [17,18], long-pulse alexandrite (755 nm), 808 nm diode laser, the Nd:YAG (1064 nm) [19].

During these procedures, it is important not to damage the transplanted tissue; in fact it is well known that flaps used for reconstruction undergo volume reduction [20]. Throughout laser hair removal, it is important to deliver sufficient heat to the hair follicle to thermally kill it and to achieve instantaneous high thermal confinement, to prevent thermal damage to non-targeted tissues [21].

Nevertheless, to the best of our knowledge, there has been no study to evaluate temperature profiles on the mucosae when diode laser is used for intraoral hair removal. The temperature increase with different devices induces a

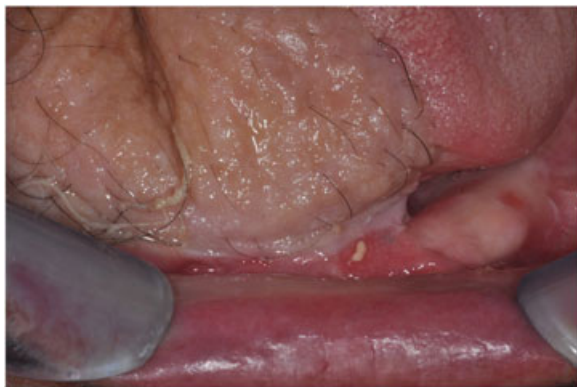

Fig. 4. After a single session of treatment with diode laser, the number of hairs was reduced.

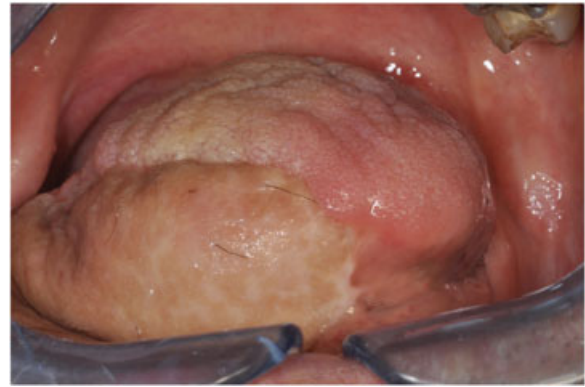

Fig. 5. After six sessions, the hair was completely removed; only a few were present, 0.4 ± 0.22 hairs/cm².

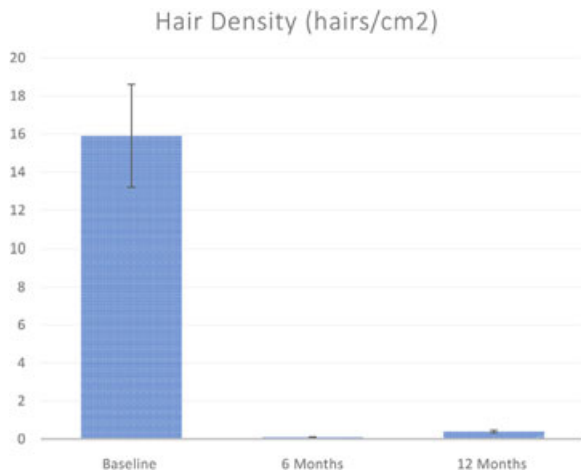


Fig. 6. The chart shows the average hair densities of the treated areas at different times (preoperative, 6 months, and 12 months). The outcome is concerned with a consistent reduction of the hair growth after the laser epilation procedure.

tissue contraction [22], and during intraoral operating on the flaps used for reconstruction, it is important to avoid this. Indeed, an adequate flap volume is critical for the restoration of speech function, swallowing, and also for a satisfactory aesthetic outcome.

In the present study, we had an instantaneous increase of temperature (84°C) which in a few seconds had disappeared. There is no standard protocol for laser use on intraoral flaps, and the present study highlights this important therapeutic option. Different techniques have been used for hair eradication. The pulsed alexandrite laser therapy was used with difficulty, as it was hampered by limited access to the mouth [23]. The 1,064-nm neodymium-doped yttrium aluminum garnet (Nd:YAG) was used with success because the shape of the handpiece fits inside the oral cavity [24], the same being true for the 800 nm diode laser [25]. Also, the preoperative electrolysis or de-epithelialization with surgical dissection from the flap of skin containing hairs follicles before flap transfer has been experimented [26]. The preoperative electrolysis or depilation is effective but has timing and access disadvantages in the setting of malignancy with a tip and a spot size of 0.5 mm × 0.5 mm. We have targeting individual hairs with three consecutive deposition of energy.

Based on our results, the 808 nm diode laser with a tip and a spot size of 0.5 mm × 0.5 mm was successfully applied for removal of the intraoral hair. All patients achieved hair eradication, regardless of the initial flap donor site, with significant improvement in the quality of life. In conclusion, the clinical findings demonstrate the safety and efficacy of the 808 nm diode laser system for intraoral hair removal.

REFERENCES

- de Vicente JC, de Villalain L, Torre A, Peña I. Microvascular free tissue transfer for tongue reconstruction after hemiglossectomy: a functional assessment of radial forearm versus anterolateral thigh flap. *J Oral Maxillofac Surg* 2008; 66(11):2270–2275.
- Shibahara T, Noma H, Takeda E, Hashimoto S. Morphologic changes in forearm flaps of the oral cavity. *J Oral Maxillofac Surg*. 2000;58(5):495–499.
- Dellon AL, Tarpley TM, Chretien PB. Histologic evaluation of intraoral skin grafts and pedicle flaps in humans. *J Oral Surg* 1976;34(9):789–794.
- Rubino C, Dessy LA, Farace F, Ena P, Mazzarello V. Microscopic and immunohistochemical analysis of the skin changes of free forearm flaps in intraoral reconstruction. *Ann Plast Surg* 2002;49(4):362–368.
- Maria L, Ioannis D, Konstantinos V, Fotis I, Konstantinos A. Histological changes in nasolabial cutaneous flaps employed in intraoral reconstruction. *J Maxillofac Oral Surg* 2017; 16(3):292–299.
- Shim TN, Abdullah A, Lanigan S, Avery C. Hairy intraoral flap—An unusual indication for laser epilation: A series of 5 cases and review of the literature. *Br J Oral Maxillofac Surg* 2011;49(7):e50–e52.
- Kuriloff DB, Finn DG, Kimmelman CP. Pharyngoesophageal hair growth: The role of laser epilation. *Otolaryngol Head Neck Surg* 1988;98(4):342–345.
- Scarano A, Lorusso F, Arcangelo M, D'Arcangelo C, Celletti R. Lateral sinus floor elevation performed with trapezoidal and modified triangular flap designs: A randomized pilot study of post-operative pain using thermal infrared imaging. *Int J Environ Res Public Health* 2018;15(6).
- Al-Samman AA, Othman HA. Facial expression drawings and the full cup test: Valid tools for the measurement of swelling after dental surgery. *Br J Oral Maxillofac Surg* 2017;55(1): 22–25.
- Grunewald S, Bodendorf MO, Zygouris A, Simon JC, Paasch U. Long-term efficacy of linear-scanning 808 nm diode laser for hair removal compared to a scanned alexandrite laser. *Lasers Surg Med* 2014;46(1):13–19.
- Glavaš H, Vukobratović M, Keser T. Infrared thermography as control of handheld IPL device for home-use. *J Cosmet Laser Ther* 2018;20(5):269–277.
- Gault DT, Grobbelaar AO, Grover R, et al. The removal of unwanted hair using a ruby laser. *Br J Plast Surg* 1999;52(3): 173–177.
- Kelner N, Vartanian JG, Pinto CAL, Coutinho-Camillo CM, Kowalski LP. Does elective neck dissection in T1/T2 carcinoma of the oral tongue and floor of the mouth influence recurrence and survival rates? *Br J Oral Maxillofac Surg* 2014;52(7):590–597.
- Cai W-X, Yu RQ, Ma L, Huang HZ, Zheng LW, Zwahlen R. Differences between epithelial and mesenchymal human tongue cancer cell lines in experimental metastasis. *Oncol Lett* 2018;15(6):9959–9964.
- Bozec A, Demez P, Gal J, et al. Long-term quality of life and psycho-social outcomes after oropharyngeal cancer surgery and radial forearm free-flap reconstruction: A GETTEC prospective multicentric study. *Surg Oncol* 2018;27(1): 23–30.
- Anderson RR, Parrish JA. Selective photothermolysis: Precise microsurgery by selective absorption of pulsed radiation. *Science* 1983;220(4596):524–527.
- Royo J, Moreno-Moraga J, Trelles MA. Clinical assessment of a new 755 nm diode laser for hair removal: Efficacy, safety and practicality in 56 patients. *Lasers Surg Med* 2017;49(4): 355–360.
- Ross EV, Ibrahim OA, Kilmer S. Long-term clinical evaluation of hair clearance in darkly pigmented individuals using a novel diode 1060 nm wavelength with multiple treatment handpieces: A prospective analysis with modeling and histological findings. *Lasers Surg Med* 2018;50(9): 893–901.
- Bodendorf MO, Wagner JA, Grunewald S, Simon J-C, Paasch U. Efficacy and safety of laser shields to prevent radiant transmission onto pigmented nevi during laser epilation: An ex vivo histology study. *Int J Hyperthermia*. 2013;29(6): 539–543.
- Joo Y-H, Hwang S-H, Sun D-I, Park J-O, Cho K-J, Kim M-S. Assessment of volume changes of radial forearm free flaps in head and neck cancer: long-term results. *Oral Oncol* 2011;47(1): 72–75.

21. Gold MH. Lasers and light sources for the removal of unwanted hair. *Clin Dermatol* 2007;25(5):443–453.
22. Scarano A, Lorusso F, Bruccoli M, Lucchina AG, Carinci F, Mortellaro C. Upper eyelid blepharoplasty with voltaic arc dermabrasion. *J Craniofac Surg* 2018;29(8):2263–2266.
23. Conroy FJ, Mahaffey PJ. Intraoral flap depilation using the long-pulsed alexandrite laser. *J Plast Reconstr Aesthet Surg* 2009;62(11):e421–e423.
24. Yan BY, Hibler BP, Connolly KL, Rossi AM. Intraoral laser hair removal of a palate free flap: Tips and technique. *Dermat Surg* 2018;44(1):122–124.
25. Ibrahimi OA, Kilmer SL. Long-term clinical evaluation of a 800-nm long-pulsed diode laser with a large spot size and vacuum-assisted suction for hair removal. *Dermatol Surg* 2012;38(6):912–917.
26. Rahpeyma A, Khajehahmadi S. Reconstruction of the maxilla by submental flap. *ANZ J Surg* 2015;85(11):873–877.