

Osteoarthritis and Cartilage

Review

Ultrasound in the diagnosis of calcium pyrophosphate dihydrate deposition disease. A systematic literature review and a meta-analysis



G. Filippou †*, A. Adinolfi †, A. Iagnocco ‡, E. Filippucci §, M.A. Cimmino ||, I. Bertoldi †, V. Di Sabatino †, V. Picerno †, A. Delle Sedie ¶, L.M. Sconfienza #, B. Frediani †, C.A. Scirè ††

† Department of Medicine, Surgery and Neurosciences, Rheumatology Section, University of Siena, Siena, Italy

‡ Rheumatology Unit, Sapienza Università di Roma, Rome, Italy

§ Rheumatology Department, Università Politecnica delle Marche, Jesi, Ancona, Italy

|| Research Laboratory and Academic Division of Clinical Rheumatology, Dipartimento di Medicina Interna, University of Genoa, Genoa, Italy

¶ Rheumatology Unit, University of Pisa, Pisa, Italy

Unit of Radiology, San Donato Hospital, San Donato Milanese, Milan, Italy

†† Epidemiology Unit, Italian Society for Rheumatology, Milan, Italy

ARTICLE INFO

Article history:

Received 22 June 2015

Accepted 19 January 2016

Keywords:

Ultrasonography
Crystal arthropathies
Synovial fluid analysis
Radiology
Systematic review
Chondrocalcinosis

SUMMARY

Objective: Ultrasonography (US) demonstrated to be a promising tool for the diagnosis of calcium pyrophosphate dihydrate deposition disease (CPPD). The aim of this systematic literature review (SLR) was to collect the definitions for the US elementary lesions and to summarize the available data about US diagnostic accuracy in CPPD.

Methods: We systematically reviewed all the studies that considered US as the index test for CPPD diagnosis without restrictions about the reference test or that provided definitions about US identification of CPPD. Sensitivity and specificity were calculated for each study and definitions were extrapolated. Subgroup analyses were planned by anatomical site included in the index text and different reference standards.

Results: Thirty-seven studies were included in this review. All the studies were eligible for the collection of US findings and all definitions were summarized. US description of elementary lesions appeared heterogeneous among the studies. Regarding US accuracy, 13 articles entered in the meta-analysis. Considering each joint structure, the sensitivity ranged between 0.77 (0.63–0.87) and 0.34 (0.16–0.58) while the specificity varies between 1.00 (0.89–1.00) and 0.92 (0.16–1.00). Considering the reference standards used, the sensibility ranged between 0.34 (0.02–0.65) and 0.87 (0.76–0.99) while specificity ranged between 0.84 (0.52–1.00) and 1.00 (0.99–1.00).

Conclusion: US is potentially a useful tool for the diagnosis of CPPD but universally accepted definitions and further testing are necessary in order to assess the role of the technique in the diagnostic process.

© 2016 Osteoarthritis Research Society International. Published by Elsevier Ltd. All rights reserved.

Introduction

Calcium pyrophosphate dihydrate deposition disease (CPPD) is the third most common inflammatory arthritis¹ and its prevalence grows with ageing². For many years, the diagnosis of CPPD has been based on the McCarty criteria³, which includes the presence of typical crystal deposits at conventional radiology (CR)

and synovial fluid analysis. In the last decade, ultrasonography (US) has been extensively used for detecting calcium pyrophosphate dihydrate crystal (CPP) deposits in joint and periarticular tissues, demonstrating to be a useful diagnostic tool for this condition^{4–11}.

Recently, a task force of the European League Against Rheumatism (EULAR)¹² has published a set of recommendations for CPPD regarding terminology, diagnosis and management. The experts, after a systematic review of the literature, concluded that US can demonstrate CPP crystals in peripheral joints with high accuracy. This is the first time that US enters, although only as recommendation, in a diagnostic criteria set for CPPD.

* Address correspondence and reprint requests to: G. Filippou, Department of Medicine, Surgery and Neurosciences, Rheumatology Section, Policlinico le Scotte, Viale Bracci 16, 53100 Siena, Italy. Tel: 39-0577-586770/1; Fax: 39-0577-40450.
E-mail address: gfilippou@gmail.com (G. Filippou).

Because of the increasing interest in the role of US as diagnostic tool for CPPD, it seemed timely to summarize the results of the available literature. To the best of our knowledge, a US protocol for the identification of CPPD deposits is not currently available and there is a great heterogeneity in the literature in terms of inclusion criteria, study design, and type of reference standard.

The objective of this study was double: the evaluation of US diagnostic accuracy in the diagnosis of CPPD and the collection of the definitions available in the literature about US elementary findings detectable in CPPD in order to define the US specific lesions for this disease. To achieve our aims, we performed a systematic literature review (SLR) and subsequent meta-analyses in which we considered US as index test and other diagnostic tools as reference standards for the diagnosis of CPPD.

Methods

The Preferred Reporting Items for Systematic Reviews and Meta-analyses (PRISMA) guidelines for reporting systematic reviews and meta-analysis were used for this review¹³. Before beginning the study, a protocol that defined all the aspects of each phase (research questions, search strategy, inclusion criteria for the articles and methods for the analysis) was developed.

Structured search strategy

The research was performed by one author and the control search by another one. We used the Medline (Pubmed), Embase, Dare and Cochrane databases, starting our research from January 1, 1980. The search strategies are shown in the [Supplemental Fig. 1](#) and were based on terms related to CPPD and US. No language or publication restrictions were applied and studies were not selected on the basis of their quality.

Study selection and data extraction

The final selection included studies on patients with suspected CPPD, independently of the clinical subtype, in which US was considered the index test, without restrictions about the reference test. No limitations were applied regarding the study type: prospective and retrospective diagnostic cohort studies, case control studies, case reports and reviews were eligible for inclusion in the review. For the eligibility of each study, we required the presence of sufficient data to build a 2×2 table of diagnostic performance and/or the presence of the definitions of US elementary lesions of CPPD in order to satisfy one of our end points or both of them.

Two authors independently screened the titles and the abstracts of the papers. An inclusion assessment was performed on the full-text of the potentially eligible articles by one reviewer and checked by a second. Discordant assessments between authors were resolved by consensus.

Data were extracted using a standardized form including author, publication year, index test, target condition, study design, inclusion criteria, number of patients, setting (inpatients, outpatients), reference standards, and 2×2 tables for every couple of index and reference test. The data about accuracy were extracted as 2×2 tables. The definitions of the US elementary lesions were summarized in *ad hoc* tables.

Quality assessment

The quality of selected studies was assessed using the modified version of the Quality Assessment of Diagnostic Accuracy Studies (QUADAS) tool¹⁴. Data extraction and quality assessment were performed by one reviewer and checked by a second one.

Data analysis

Sensitivity and specificity were calculated for each 2×2 set of data. Heterogeneity among included studies was visually evaluated, by plotting sensitivity and specificity on a receiver operating characteristic (ROC) graph, and separately tested by the Chi-square test using $n - 1$ degrees of freedom.

In the presence of heterogeneity and negative correlation between sensitivity and specificity, as commonly seen in diagnostic studies, the bivariate model was used to estimate summary sensitivity and specificity with 95% confidence intervals (CI) and to derive a hierarchical summary receiver operating characteristic (HSROC) curve¹⁵.

Given the expected methodological heterogeneity, subgroup analyses by anatomical sites examined by the index test were planned. The influence of different reference standards has been explored by univariable meta-regression analyses. Publication bias was indirectly assessed by the funnel plot of logDOR. Formal testing of asymmetry was calculated. Influential observations and outliers were evaluated by plotting Cook's distance and standardized predicted random effects (standardized level-2 residuals), respectively.

Stata, version 11 (StataCorp, College Station, Texas) was used to perform all analyses. In particular the generalized linear mixed model approach to bivariate meta-analysis of sensitivity and specificity was obtained using the 'metandi' and 'midas' commands of Stata.

Results

Description of the studies

The search strategy identified 238 articles. [Fig. 1](#) reports the phases of the selection process. After the first evaluation of the titles and abstracts, 41 full-text articles were included for the review but four articles^{16–19} were rejected afterwards. The rejection of two of these studies^{16,17} was due to a lack of sufficient data to satisfy at least one of our objectives, while two other articles^{18,19} were rejected because the US was used as reference test.

Of the remaining 37 articles^{4–11,20–48}, 10 were case control studies^{4–8,10,30,31,41,43}, 12 were cohort studies^{9,11,21,22,24,32–36,38,44}, eight were case reports^{20,23,26,27,40,46–48}, and seven reviews^{25,28,29,37,39,42,45}.

Considering the cohort studies, the mean number of patients included was 46 (SD ± 28, range 6–100) and the median value was 42. The mean age of subjects enrolled was 66 years (SD ± 9.37,

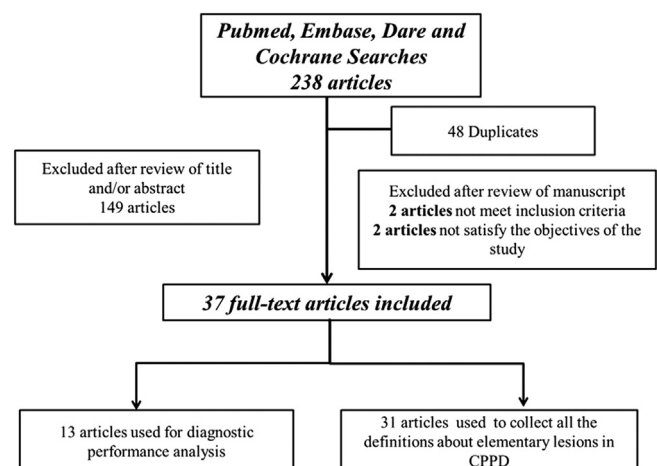


Fig. 1. Phases of the study selection (PRISMA flow-chart).

range 49–78). The sex ratio is not reported in all studies but from available information a higher prevalence of males was present (approximately 58%).

In the case–control studies, the mean number of patients enrolled as cases was 37.7 (SD \pm 25, range 11–80) and the median value was 33. The mean age of these patients was 61 years (SD \pm 16, range 49–69). Regarding the control groups, the mean number of patients included was 40 (SD \pm 30, 13–100) and the median value was 25. The mean age was 61 years (SD \pm 8.47, range 45–69). Although the exact sex ratio is not reported in all studies, there is a weak prevalence of males among cases (51%) and a higher prevalence of females among controls (63%). Furthermore, in most studies, controls are affected by other rheumatic diseases such as osteoarthritis (OA), rheumatoid arthritis (RA) or psoriatic arthritis (PsA), and gout. Only in two studies, the controls were healthy subjects.

Regarding the reference standard used, the diagnosis of CPPD was based on the McCarty criteria in six studies^{6,10,11,30,36,38}, on a positive synovial fluid analysis in 10^{7,9,21,22,31,32,41,43,44}, and on the presence of radiographic chondrocalcinosis (CC) in two^{4,5}. In three studies, produced by the same group, the reference standard was the microscopic analysis of the specimens^{33–35}.

Descriptive data of the studies are summarized in Table I.

Diagnostic accuracy results

Regarding the evaluation of US diagnostic accuracy in CPPD, only 13 studies had enough data for constructing the contingency tables but in one of these^{4–6,8,10,22,30,31,34,35,41,43}, only sensitivity could be calculated²¹.

In all the selected studies but five^{8,22,31,35,43} the data were suitable for defining US sensitivity and specificity only at the level of a single joint structure (i.e., cartilage, fibrocartilage, tendon) and not at the level of the whole joint or patient.

The values of sensitivity and specificity for each study are illustrated in Table II while Fig. 2 illustrates the ROC curves about the sensitivity and specificity values relating at a single structure and at joint/patient level.

For the studies considering the whole patient and not a single structure^{8,22,31,35,43}, sensitivity and specificity ranged from 0.60 to 1.00 and from 0.88 to 1, respectively. The pooled sensitivity was 0.89 (95% CI 0.72–0.97) and specificity was 0.94 (95% CI 0.87–0.98).

Considering the US performance at the level of each joint structure, the highest value of sensitivity was obtained at the hyaline cartilage^{4,5,10,21,35,41,43} with a pooled sensitivity of 0.77 (95% CI 0.63–0.87) and specificity of 0.92 (0.16–1.00), and at the fibrocartilage^{4,34,35,41,43} with a pooled sensitivity of 0.77 (95% CI 0.31–0.96) and specificity of 0.96 (95% CI 0.75–1.00), while for the tendons^{6,30} the sensitivity and specificity were respectively 0.34 (0.16–0.58) and 1.00 (95% CI 0.89–1.00).

Another important source of heterogeneity among the studies was the type of reference standard used. Considering synovial fluid analysis^{8,21,22,31,41,43} as reference standard, the pooled sensitivity of US was 0.87 (95% CI 0.76–0.99) and specificity 0.98 (0.96–1.00). When the reference standard was radiography^{4,5} the sensitivity of US was 0.58 (95% CI 0.09–1.00) and specificity 0.84 (95% CI 0.52–1.00). In comparison to McCarty criteria^{6,10,30}, US sensitivity and specificity were 0.34 (95% CI 0.02–0.65) and 1.00 (95% CI 0.99–1.00), respectively. Finally using microscopic analysis as reference standard^{34,35}, sensitivity was 0.84 (95% CI 0.61–1.00) and specificity 0.93 (0.77–1.00). The lowest values of sensitivity have been calculated in the studies that evaluated tendons for the presence of CPPD and for those that adopted the McCarty criteria as the reference standard.

Methodological quality assessment

Most of the studies had a low risk of bias in many items. However two of them^{6,10} had a high risk of differential verification bias because some of the index test results were verified by different reference standards.

Regarding the time of execution of index and reference tests, in most of the studies the delay between them was not reported. In one study the risk of bias was low (the delay between tests was less than an hour)⁸ and in another one⁴¹ it was high because of the use of an historical archive of synovial fluid analyses to select the controls. Furthermore, in some studies the blinding of the index and reference tests was not explicitly reported^{4–6,10,21,22,30,31,41,43}. Finally, most of the studies were transversal and no withdrawals of patients were reported in any study. The evaluation of the methodological quality of the included studies is represented in Fig. 3.

Two studies^{5,6} resulted both outliers and influential. Excluding those influential observations, the overall sensitivity changes from 0.75 (95% CI) to 0.79 (0.64–0.89) and specificity from 0.98 (0.92–0.99) to 0.97 (0.95–0.99).

Finally, publication bias was indirectly evaluating the symmetry on the funnel plot of logDOR. This diagram and forma testing showed a marginally significant small study effect, but not in the direction of publication bias (Supplemental Fig. 2).

Definition of US specific findings in CPPD

Considering the second end point of this systematic review, almost all studies were eligible. The definitions used for the identification of the US features of CPP deposits were divided depending on the anatomical structure under examination. In particular, different definitions were used for CPP deposition at the level of hyaline cartilage, fibrocartilage, tendons and synovial fluid.

Considering the hyaline cartilage, CPP crystals are generally described as hyperechoic deposits, placed within the layer of the cartilage, that reach large dimensions. At the level of the fibrocartilage, CPP crystals usually appear as hyperechoic, rounded or amorphous-shaped deposits placed within the structure. In the tendons, CPP crystals are usually described as linear deposits within the fibrillar echotexture (multiple or single lines or thick solid band), but in some studies these deposits are described also as punctate. Finally, in the synovial fluid CPP crystals appear as hyperechoic spots or ovalar aggregates. The definitions used in the studies for US diagnosis of CPPD were summarized in Table III and characteristic examples of CPPD appearance in US are provided in Fig. 4.

Discussion

For many years, the diagnosis of CPPD has been based on the McCarty criteria³ that were based on CR and synovial fluid analysis. In the last years US has demonstrated to be a potential alternative diagnostic method^{7,8,10} and has been included in the diagnostic methods proposed by the EULAR task force for diagnosis of the disease¹². To the best of our knowledge, this is the first systematic review on the diagnostic accuracy of US in CPPD and global results confirm a good diagnostic accuracy of US, however some issues can be raised regarding mainly different methodology between studies.

Of the 37 studies included in the review, 21 came from two centres: Siena (eight papers) and Jesi (13 papers) in Italy. Generally, 25 out of 37 studies have been carried out in Italy, denoting a particular interest for this disease. Excluding the case reports (eight papers) and the review articles (seven papers), 22 studies investigated the utility of US in CPPD. Twelve articles tried to assess the

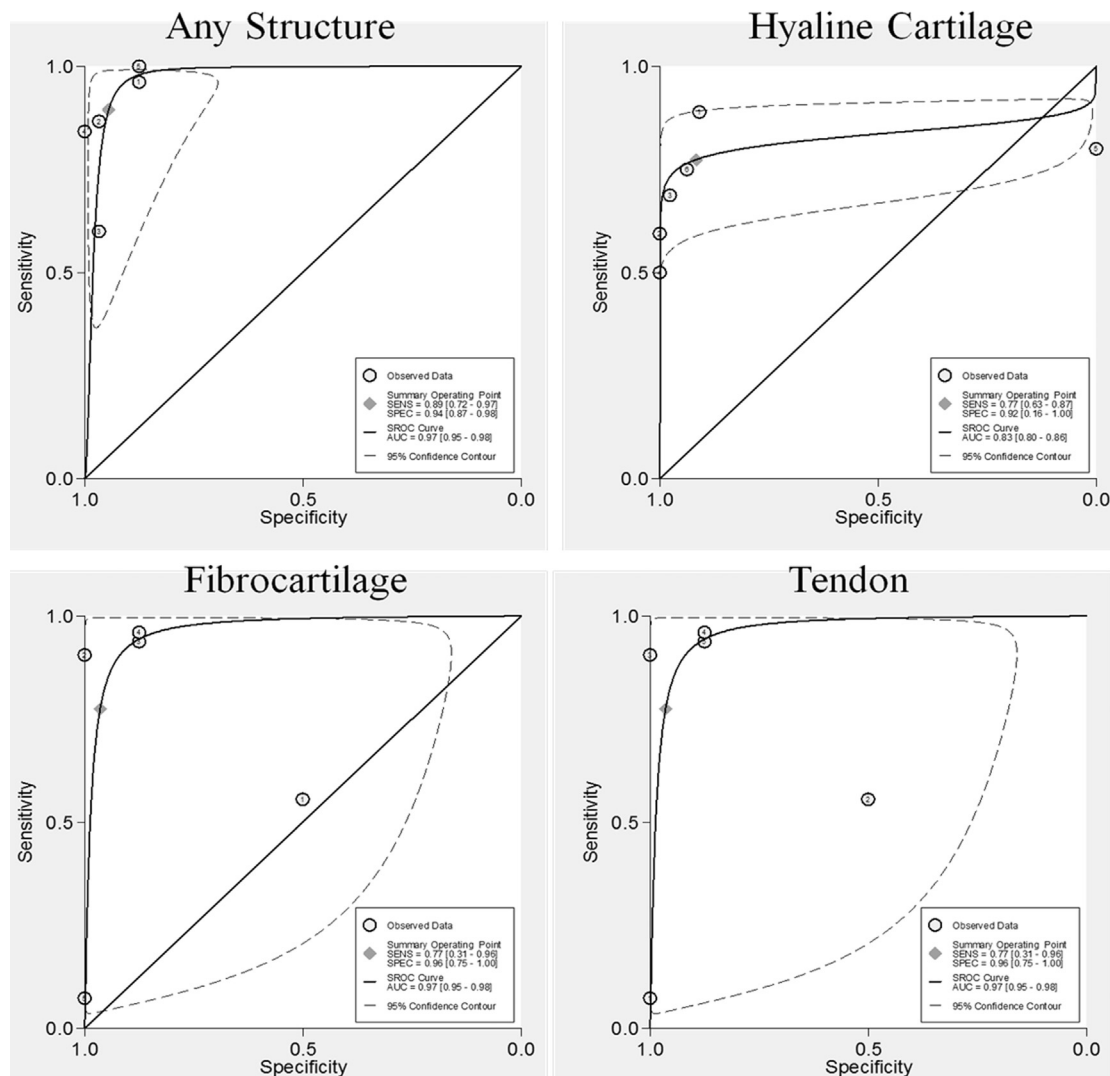
Table 1
 Characteristics of the included studies. N number of patients included; n.a not applicable; US ultrasound; SFA synovial fluid analysis, XR radiography; MA microscopic analysis; ARA American Rheumatism Association

Author	Study design	Inclusion criteria	N	Index test	Reference tests
1995 Coari⁴	Case control	Two groups of subjects. In the first, the patients were affected by CPPD defined according to McCarty criteria. The controls were healthy subjects.	28 Cases 46 controls	US	XR
2000 Monteforte⁴⁶	Case report	n.a	n.a	n.a	n.a
2002 Farina³²	Cohort study	Consecutive patients affected by several rheumatic diseases (RA, PsA, gout, CPPD, post-traumatic synovitis, septic arthritis, OA).	69	US	SFA
2002 Foldes⁵	Case control	Two groups of patients. In the first, the patients had a history of unilateral knee CC. In the second, the patients were affected by mild OA without CC at XR.	21 Cases 19 controls	US	XR
2002 Sofka⁴⁸	Case report	n.a	n.a	n.a	n.a
2004 Falsetti⁶	Case control	Two groups of subjects. In the first, the patients were affected by CPPD defined according to McCarty criteria. In the second, 50 controls were affected by knee OA without signs of CC at XR and 50 controls were healthy subjects.	57 Cases 100 controls	US	SFA + XR
2005 Frediani⁷	Case control	Two groups of subjects. In the first, the patients with US features of CPPD. In the second, patients without US signs of CPPD.	11 Cases 13 controls	US	SFA
2006 Grassi⁹	Cohort study	Consecutive patients affected by crystal-related arthropathies (34 with CPPD and 26 with gout) confirmed by SFA.	60	US	SFA
2007 Delle Sedie²⁸	Review	n.a	n.a	n.a	n.a
2007 Filippou⁸	Case control	Two groups of patients. In the first, patients with knee effusion and US features of CPPD. In the second, the patients had knee effusion without US signs of CPPD.	14 Cases 29 controls	US	SFA
2008 Ciapetti²⁴	Cohort study	Presence of CPP crystals confirmed by analysis of synovial fluid.	42	US	SFA
2009 Filippucci¹⁰	Case control	Two groups of subjects. In the first, 48 patients were affected by CPPD according to McCarty criteria and 32 affected by gout according to ARA guidelines. In the second, the controls were patients affected by RA, PsA or OA.	80 Cases 52 controls	US	SFA + XR
2009 Gutierrez⁴²	Review	n.a	n.a	n.a	n.a
2010 Filippucci¹¹	Cohort study	Two cohorts of subjects. In the first, the patients were affected by CPPD according to McCarty criteria. In the second, the patients were affected by gout, diagnosed using ARA guidelines.	70 CPPD 30 gout	US	SFA + XR
2010 Dufauret-Lombard²⁹	Review	n.a	n.a	n.a	n.a
2010 Gutierrez⁴⁰	Case report	n.a	n.a	n.a	n.a
2011 Checa²³	Case report	n.a	1	n.a	n.a
2011 Di Geso²⁷	Case report	n.a	n.a	n.a	n.a
2012 Di Geso²⁶	Case report	n.a	n.a	n.a	n.a
2012 Ellabban³⁰	Case control	Two groups of subjects. In the first, the patients were affected by CPPD defined according to McCarty criteria. In the second the patients were affected by OA without CPP crystals at SFA or signs of CC at XR.	38 Cases 22 controls	US	SFA + XR
2012 Filippou³⁴	Cohort study	Consecutive patients who waiting to undergo knee replacement surgery.	6	US	MA
2012 Ellabban³¹	Case control	A cohort of patients with knee effusion was divided in two groups. In the first, the patients were positive for CPP crystals according to SFA. In the second, the patients were negative for CPP crystals at SFA.	60	US	SFA
2012 Filippucci³⁷	Review	n.a	n.a	n.a	n.a
2012 Magarelli⁴⁵	Review	n.a	n.a	n.a	n.a
2013 Adinolfi²⁰	Case report	n.a	1	n.a	n.a
2013 Barskova²¹	Cohort study	Patients < 60 years with diagnosis of CPPD defined according to McCarty criteria.	25	US	SFA
2013 Catay²²	Cohort study	Consecutive patients > 50 years with knee effusion on clinical examination.	39	US	SFA
2013 Filippou³³	Cohort study	Consecutive patients who waiting to undergo knee replacement surgery.	6	US	MA
2013 DeJaco²⁵	Review	n.a	n.a	n.a	n.a
2013 Filippou³⁶	Cohort study	Patients affected by CPPD defined according to McCarty criteria.	42	US	SFA + XR
2013 Filippucci³⁸	Cohort study	Two cohorts of subjects. In the first, the patients were affected by CPPD defined according to McCarty criteria. In the second, the patients were affected by gout, diagnosed using ARA guidelines.	42 Gout 46 CPPD	US	SFA + XR
2013 Kudaeva⁴⁴	Cohort study	Patients affected by crystal-related arthropathies (gout or CPPD) confirmed by synovial fluid analysis.	15	US	SFA
2013 Russell⁴⁷	Case report	n.a	n.a	n.a	n.a
2014 Gutierrez⁴¹	Case control	Two groups of subjects. In the first, the patients were affected by CPPD defined according to SFA. In the second, the patients were affected by AR, seronegative arthritis, gout and OA and not having CPP crystals at synovial fluid analysis.	74 Cases 83 controls	US	SFA
2014 Filippou³⁵	Cohort study	Consecutive patients waiting to undergo knee replacement surgery.	42	US	MA
2014 Filippucci³⁹	Review	n.a	n.a	n.a	n.a
2014 Juge³³	Case control	Patients with painful knee effusion. The final diagnosis of CPPD was proven by identification of CPP crystals in SFA.	n.a	US	SFA

Table II

Values of sensitivity and specificity of each study included. SFA synovial fluid analysis, XR radiography; MA microscopic analysis

Study	Structure assessed	Reference standard	Sensitivity (95% CI)	Specificity (95% CI)
<i>Coari 1995</i> ⁴	Hyaline cartilage	XR	0.80 (0.66–0.90)	0.00 (0.00–0.46)
<i>Coari 1995</i> ⁴	Fibrocartilage	XR	0.07 (0.02–0.20)	1.00 (0.78–1.00)
<i>Foldes 2002</i> ⁵	Hyaline cartilage	XR	0.89 (0.74–0.97)	0.91 (0.78–0.97)
<i>Falsetti 2004</i> ⁶	Achilles tendon	McCarty criteria	0.58 (0.44–0.71)	1.00 (0.96–1.00)
<i>Falsetti 2004</i> ⁶	Plantar fascia	McCarty criteria	0.16 (0.07–0.28)	0.99 (0.95–1.00)
<i>Filippou 2007</i> ⁸	Any	SFA	0.87 (0.60–0.98)	0.97 (0.83–1.00)
<i>Filippucci 2009</i> ¹⁰	Hyaline cartilage	SFA	0.69 (0.54–0.81)	0.98 (0.92–1.00)
<i>Ellaban 2012</i> ³⁰	Achilles tendon	McCarty criteria	0.58 (0.41–0.74)	1.00 (0.85–1.00)
<i>Ellaban 2012</i> ³⁰	Plantar fascia	McCarty criteria	0.16 (0.06–0.31)	1.00 (0.85–1.00)
<i>Ellaban 2012</i> ³¹	Any	SFA	0.84 (0.69–0.94)	1.00 (0.79–1.00)
<i>Barskova 2013</i> ²¹	Hyaline cartilage	SFA	1.00 (0.86–1.00)	1.00 (0.86–1.00)
<i>Filippou 2012</i> ³⁴	Fibrocartilage	MA	0.56 (0.21–0.86)	0.50 (0.01–0.99)
<i>Catay 2013</i> ²²	Any	SFA	0.60 (0.32–0.84)	0.97 (0.88–1.00)
<i>Gutierrez 2014</i> ⁴¹	Hyaline cartilage	SFA	0.59 (0.47–0.71)	1.00 (0.95–1.00)
<i>Gutierrez 2014</i> ⁴¹	Fibrocartilage	SFA	0.91 (0.81–0.96)	1.00 (0.95–1.00)
<i>Filippou 2014</i> ³⁵	Any	MA	0.96 (0.80–1.00)	0.88 (0.62–0.98)
<i>Filippou 2014</i> ³⁵	Hyaline cartilage	MA	0.50 (0.19–0.81)	1.00 (0.74–1.00)
<i>Filippou 2014</i> ³⁵	Fibrocartilage	MA	0.96 (0.80–1.00)	0.88 (0.62–0.98)
<i>Juge 2014</i> ⁴³	Any	SFA	1.00 (0.79–1.00)	0.88 (0.62–0.98)
<i>Juge 2014</i> ⁴³	Fibrocartilage	SFA	0.94 (0.70–1.00)	0.88 (0.62–0.98)
<i>Juge 2014</i> ⁴³	Hyaline cartilage	SFA	0.75 (0.48–0.93)	0.94 (0.70–1.00)

**Fig. 2.** ROC curves about the sensitivity and specificity values relating any structures or a single one.

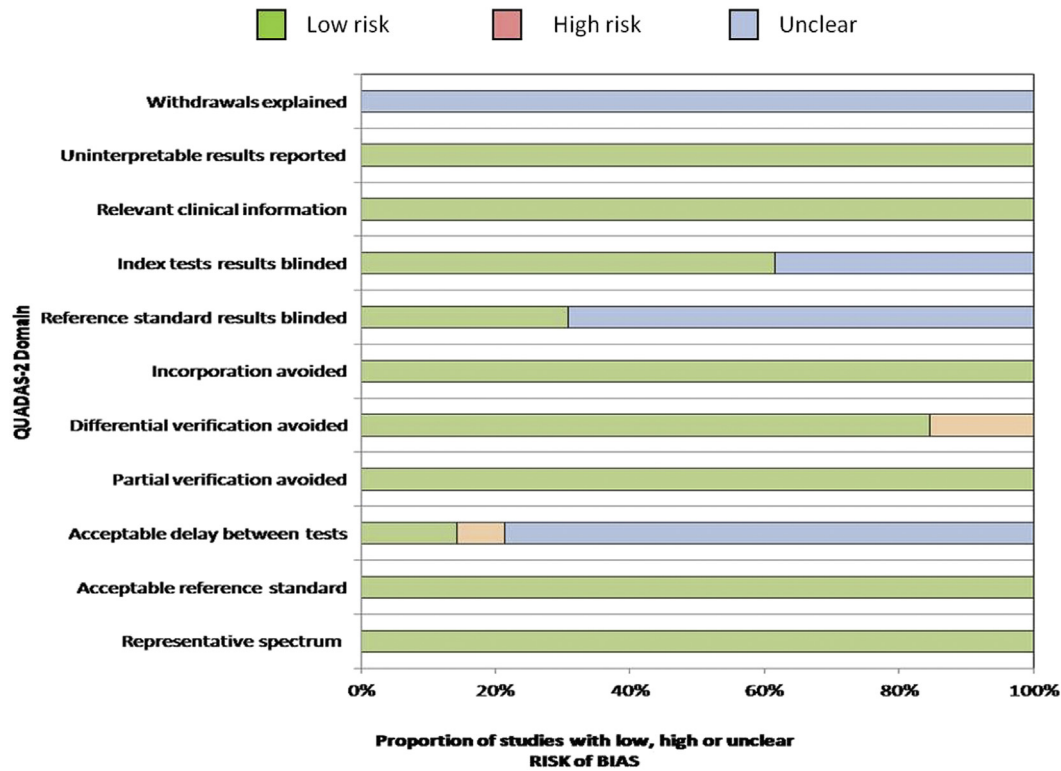


Fig. 3. Evaluation of the methodological quality of the included studies.

ultrasonographic appearance of CPP deposition and 10 of them assessed the sensitivity and specificity of US in CPPD. As described in the results however, not all the studies evaluated the diagnostic accuracy of US at the patient level. Most of them assessed only a single joint and in some cases only a single structure from a single joint (i.e., hyaline cartilage or meniscus). This fact could explain the

differences in diagnostic accuracy, because not all structures are affected by CPP deposition at the same time and with the same extension³⁶.

In fact, the sensitivity of US in detecting CPPD varies according to the structure under examination ranging from 34% (tendon) to 80% (hyaline cartilage). Sensitivity and specificity compared to

Table III
Summary of definitions used in the studies for US diagnosis of CPPD

Structure assessed	Percentage of description	Shape of CPP crystals	Echogenicity of CPP crystals	Localization of CPP crystals
Fibrocartilage	62%	<ul style="list-style-type: none"> ✓ Spots (“punctuate pattern”)^{7,22,25,28,30,34,36,39,42,45} ✓ Rounded or amorphous-shaped areas^{9,11,24,28} ✓ Rounded foci^{29,47} ✓ Rounded Deposits^{20,26,27} ✓ Punctate dots²³ 	<ul style="list-style-type: none"> ✓ Defined as Hyperechoic/Hyperechogenic in all the studies ✓ Characterized by echogenicity similar to the bone cortex even at very low levels of gain¹¹ 	<ul style="list-style-type: none"> ✓ Localized within the fibrocartilage in all the studies ✓ It could be localized also on the surface of meniscal fibrocartilage³⁴
Hyaline cartilage	84%	<ul style="list-style-type: none"> ✓ Images parallel to the surfaces, classified as punctiform or linear if longer^{4,29} ✓ Linear deposits^{20,24,26,27,46–48} ✓ Thin bands parallel to the surfaces of the hyaline cartilage^{5,7,9,11,22,25,28,36,39,45} ✓ Spots not generating a posterior acoustic shadow^{10,25,38,39,42} ✓ “Rosary beads signs” – punctate dots²³ ✓ Aggregates that could be linear or homogeneous³⁷ 	<ul style="list-style-type: none"> ✓ Defined as Hyperechoic/Hyperechogenic in all the studies 	<ul style="list-style-type: none"> ✓ Localized within the hyaline cartilage in all the studies ✓ In could be localized on the superficial margin of the hyaline cartilage, resembling the double contour sign typical of UA deposits²⁰
Tendons	43%	<ul style="list-style-type: none"> ✓ Linear deposits, parallel to the tendon fibrillar structure, not in continuity with the bone profile. It could be single or multiple^{6,25,29,30,36,39} ✓ Spots – “punctate” pattern^{7,24,28} ✓ Linear and extensive and may generate an acoustic shadow^{9,11,37,39,43} 	<ul style="list-style-type: none"> ✓ Defined as Hyperechoic/Hyperechogenic in all the studies 	<ul style="list-style-type: none"> ✓ Localized within the tendons in all the studies
Synovial fluid	12%	<ul style="list-style-type: none"> ✓ Spots without acoustic posterior shadowing^{32,41} ✓ Uniformly rounded in shape with a sharply defined outer profile.⁹ ✓ Aggregates uniformly rounded in shape with sharply defined margins²⁴ 	<ul style="list-style-type: none"> ✓ Defined as Hyperechoic/Hyperechogenic in all the studies 	<ul style="list-style-type: none"> ✓ Localized within the synovial fluid in all the studies

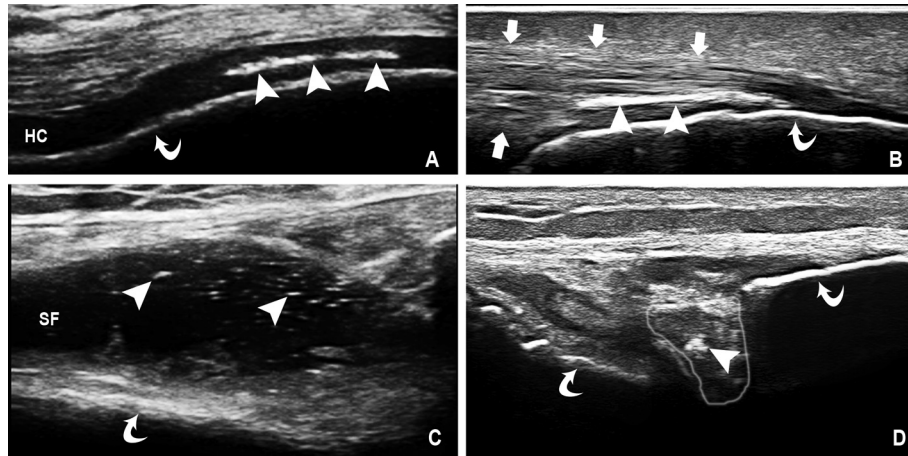


Fig. 4. Characteristic US images of CPPD appearance. Even if these patterns are frequently observed, they are not exclusive of the appearance of CPPD and other forms and shapes of deposits may be encountered. CPPD appears as hyperechoic deposits with echogenicity similar to that of the bone profile. A: hyperechoic deposits within the hyaline cartilage layer of the knee B: hyperechoic deposits within Achilles tendon. C: hyperechoic deposits within synovial fluid (only two of them indicated in this illustration). D: hyperechoic deposits within meniscal fibrocartilage. Legend: arrowheads: CPP deposition, curved arrows: the bone profile, arrows: tendon margins, HC: hyaline cartilage layer (anechoic/hypoechoic on US), SF (anechoic/hypoechoic on US), grey line in frame D individuates the lateral meniscus of the knee.

synovial fluid analysis were high, suggesting that US may help also in the diagnosis of CPPD and not only of CC. The low sensitivity at the tendon level is probably due to a late involvement of this structure in the natural history of CPPD³⁶. On the other hand, specificity is high, independently of the examined structure (range from 93% to 100%). This indicates that the US appearance of CPP deposition is quite characteristic and well defined in the literature. Finally, if we consider the values of sensitivity and specificity at the patient level (all structures of several examined joints) sensitivity is 91% and specificity 97%. Thus, the best values of diagnostic accuracy are obtained if we consider both fibrocartilage and hyaline cartilage, preferably in more than one joint.

Further, the sensitivity and specificity values of the studies varied also depending on the gold standard used for diagnosis. Ten studies used the presence of CPP crystals in the synovial fluid (SF) alone as the criterion for the diagnosis. Only few studies used the McCarty's criteria (SF + radiological positivity) and even less studies used radiography or histology alone as criterion for the diagnosis (see Table I). There are different interpretations for these data. First, there is no evidence on sensitivity and specificity of SF analysis for diagnosis of CPPD, because it has never been tested against another gold standard. Only recently³⁵, the sensitivity of SF analysis (70%) and its role as diagnostic gold standard have been challenged. On the other hand, the use of a strict gold standard, such as histology of the cartilage and fibrocartilage, produced lower values of sensitivity and specificity probably because the presence of crystals in the joint is not detectable by US before the aggregates reach sufficient dimensions.

Of all studies included in the review, only four^{10,36,41,43} assessed the inter-observer agreement, while no study evaluated the intra-observer agreement. In two of these studies^{10,41} the agreement has been assessed only at the hyaline cartilage level and in the other two^{36,43} both at the level of hyaline cartilage and of the fibrocartilage of the knee. In two studies, assessment was compared between expert and a non-expert operators^{10,41} whereas in three studies only experts were involved. Therefore, the results are variable and not easily comparable, with differences in agreement between menisci and hyaline cartilage. Values of kappa ranged from 0.55 to 0.81 for the hyaline cartilage and from 0.68 to 1 for the menisci.

The criteria for US identification of CPP deposition in fibrocartilage and hyaline cartilage were quite similar in all the studies and consisted in the presence of hyperechoic deposits (oval or

round shaped spots) in the context of hyaline cartilage and fibrocartilage. Diagnostic accuracy and reliability of US in these structures were high in all studies, indicating that the US appearance of CPPD in these structures is acceptably defined and understood by sonographers. CPPD affecting the tendons is usually described as linear hyperechoic deposition that is disposed along their long axis. The diagnostic accuracy of US by evaluating tendons is rather low regarding sensitivity and this could be due to the definitions or to the late involvement of tendons in the disease course³⁶. The deposition of CPP on the superficial margin of the hyaline cartilage^{20,25}, mimicking the double contour sign of uric acid deposition, has been described. Since this is considered the most specific sign of gout⁴⁹, the finding should be further investigated in order to avoid misdiagnosis.

Finally, the overall quality of the studies included in the review was acceptable and the risk of bias was low. The number of studies was small and most of them used similar US techniques and definitions for CPPD, and evaluated similar joints (mainly the knee) thus making most of the studies of diagnostic accuracy comparable. The potential confounders and reasons for false positive and negative results, and some tricks that could facilitate CPPD identification by US were also described^{9,10,20,25,33}. Another issue that could be raised regarding the US CPPD deposition is the nature of the hyperechoic deposits. One study aimed to assess the validity of the method by demonstrating that hyperechoic deposits in the menisci are real CPP deposits at microscopic analysis³⁴. However, this study does not exclude that hyperechoic deposits found in other sites, different that fibrocartilage, could be of different nature but on the other hand there has not been any evidence until now, demonstrating that the US CPP deposits are due to other calcium crystals. A common limitation of most of the studies is the small number of patients included and in some the different comparator used (healthy controls or patients affected by other rheumatic diseases). Such methodological heterogeneity also accounts for the small study effect.

Therefore, according to the data available in the literature, US seems to be a promising tool for the diagnosis of CPPD but there are some aspects that have to be further assessed. The future research agenda should include the creation of universally accepted and reliable definitions for US identification of CPPD in all anatomical structures, the assessment of the reliability and the evaluation of sensitivity and specificity of the new criteria against a reliable gold

standard. However, even with some gaps in the actual knowledge, US has demonstrated to be, in trained hands, a valuable tool as it allows the evaluation of more joints in few minutes, the assessment of inflammation or other joint pathologies and the identification of CPPD deposits. Therefore, we believe that US, thanks also to its intrinsic characteristics, could be the first line exam when CPPD is suspected while SF analysis could be used for difficult cases or for all these cases when arthrocentesis is also indicated for therapeutic reasons. The role of CR has to be further established as the actual data do not indicate a clear advantage of CR over the other two methods. Finally, it is not clear if the combination of two or more techniques could further improve the diagnostic accuracy for CPPD, and this aspect should be further evaluated.

In conclusion, the data emerged from this meta-analysis indicate that US could be a useful tool in the diagnosis of CPPD but further studies are necessary to address its effective potential. The different clinical subsets of CPPD complicate the evaluation of the usefulness of US. All studies included in this meta-analysis addressed the first problem. Further, it is necessary to find a feasible and reliable gold standard for CPPD diagnosis vs whom all diagnostics methods should be tested. A new set of accepted US diagnostic criteria, could help to further improve the accuracy of the exam, mainly in the sites where US has a low potential (i.e., tendons). Finally, the reliability of the method, in particular intra- and inter-observer agreement should be studied. Then, the clinical utility and feasibility of US will be fully addressed and the technique could become an important tool in the diagnosis of CPPD.

Contributorship statement

All authors included on this paper fulfil the criteria of authorship.

Disclosure statement

The authors declare no conflicts of interest.

Funding statement

There are no funders to report for this submission.

Ethical approval information

Not applicable to this kind of study (SLR).

Acknowledgements

No acknowledgements.

Supplementary data

Supplementary data related to this article can be found at <http://dx.doi.org/10.1016/j.joca.2016.01.136>.

References

- Salaffi F, De Angelis R, Grassi W, MArche Pain Prevalence, INvestigation Group (MAPPING) study. Prevalence of musculoskeletal conditions in an Italian population sample: results of a regional community-based study. I. The MAPPING study. *Clin Exp Rheumatol* 2005;23(6):819–28.
- Musacchio E, Ramonda R, Perissinotto E, Sartori L, Hirsch R, Punzi L, et al. The impact of knee and hip chondrocalcinosis on disability in older people: the ProVA Study from northeastern Italy. *Ann Rheum Dis* 2011;70(11):1937–43, <http://dx.doi.org/10.1136/ard.2011.150508>.
- Ryan L, McCarty D. Calcium pyrophosphate crystal deposition disease, pseudogout and articular chondrocalcinosis. In: McCarty DJ, Koopman W, Eds. *Arthritis and Allied Conditions. A Textbook of Rheumatology*. 13th edn. Philadelphia, USA: Lea & Febiger; 1997:2013–25.
- Coari G, Iagnocco A, Zoppini A. Chondrocalcinosis: sonographic study of the knee. *Clin Rheumatol* 1995;14(5):511–4.
- Foldes K. Knee chondrocalcinosis: an ultrasonographic study of the hyalin cartilage. *Clin Imaging* 2002;26(3):194–6.
- Falsetti P, Frediani B, Acciai C, Baldi F, Filippou G, Prada EP, et al. Ultrasonographic study of Achilles tendon and plantar fascia in chondrocalcinosis. *J Rheumatol* 2004;31(11):2242–50.
- Frediani B, Filippou G, Falsetti P, Lorenzini S, Baldi F, Acciai C, et al. Diagnosis of calcium pyrophosphate dihydrate crystal deposition disease: ultrasonographic criteria proposed. *Ann Rheum Dis* 2005;64(4):638–40, <http://dx.doi.org/10.1136/ard.2004.024109>.
- Filippou G, Frediani B, Gallo A, Menza L, Falsetti P, Baldi F, et al. A “new” technique for the diagnosis of chondrocalcinosis of the knee: sensitivity and specificity of high-frequency ultrasonography. *Ann Rheum Dis* 2007;66(8):1126–8, <http://dx.doi.org/10.1136/ard.2007.069344>.
- Grassi W, Meenagh G, Pascual E, Filippucci E. “Crystal clear”—sonographic assessment of gout and calcium pyrophosphate deposition disease. *Semin Arthritis Rheum* 2006;36(3):197–202, <http://dx.doi.org/10.1016/j.semarthrit.2006.08.001>.
- Filippucci E, Gutierrez M, Georgescu D, Salaffi F, Grassi W. Hyaline cartilage involvement in patients with gout and calcium pyrophosphate deposition disease. An ultrasound study. *Osteoarthritis Cartilage* 2009;17(2):178–81, <http://dx.doi.org/10.1016/j.joca.2008.06.003>.
- Filippucci E, Scirè CA, Delle Sedie A, Iagnocco A, Riente L, Meenagh G, et al. Ultrasound imaging for the rheumatologist. XXV. Sonographic assessment of the knee in patients with gout and calcium pyrophosphate deposition disease. *Clin Exp Rheumatol* 2010;28(1):2–5.
- Zhang W, Doherty M, Bardin T, Barskova V, Guerne P-A, Jansen TL, et al. European League Against Rheumatism recommendations for calcium pyrophosphate deposition. Part I: terminology and diagnosis. *Ann Rheum Dis* 2011;70(4):563–70, <http://dx.doi.org/10.1136/ard.2010.139105>.
- Moher D, Liberati A, Tetzlaff J, Altman DG. Preferred reporting items for systematic reviews and meta-analyses: the PRISMA statement. *Int J Surg* 2010;8(5):336–41, <http://dx.doi.org/10.1016/j.ijsu.2010.02.007>.
- Reitsma J, Rutjes A, Whiting P, Vlassov V, Leeflang M, Deeks J. Assessing methodological quality. In: *Cochrane Handbook for Systematic Reviews of Diagnostic Test Accuracy*. The Cochrane Collaboration. Version 1.0.0, <http://srdta.cochrane.org/>.
- Reitsma JB, Glas AS, Rutjes AWS, Scholten RJP, Bossuyt PM, Zwinderman AH. Bivariate analysis of sensitivity and specificity produces informative summary measures in diagnostic reviews. *J Clin Epidemiol* 2005;58(10):982–90, <http://dx.doi.org/10.1016/j.jclinepi.2005.02.022>.
- Bergner R, Peters L, Schmitt V, Sattler H, Loffler C. Arthrosonographic findings in crystal arthropathies. *Ann Rheum Dis* 2013;72(Suppl 13):713.
- Diaz M, Calvo E, Chalem M. Diagnosis usefulness of high-resolution sonography (HRS) in crystal deposition disease (CDD). *J Clin Rheumatol* 2010;16(S26).
- Musetescu A, Ciurea P, Rosu A, Cojocaru-Gofita I, Vreju F. Musculoskeletal ultrasound detection of calcium aggregates in patients with osteoarthritis and nonradiographic chondrocalcinosis. *Osteoporos Int* 2013;24(1):S357.
- Russell E, Hussain H, Checa A. Detection by ultrasound of small calcium deposits within cartilage in patients without radiographic chondrocalcinosis. *Arthritis Rheum* 2011;63(10).

20. Adinolfi A, Picerno V, Di Sabatino V, Bertoldi I, Galeazzi M, Frediani B, et al. Inquiry is fatal to certainty – is the ultrasonography double contour sign specific for uric acid-induced arthritis? *Arthritis Rheum* 2013;65(7):1952, <http://dx.doi.org/10.1002/art.37952>.
21. Barskova VG, Kudaeva FM, Bozhieva LA, Smirnov AV, Volkov AV, Nasonov EL. Comparison of three imaging techniques in diagnosis of chondrocalcinosis of the knees in calcium pyrophosphate deposition disease. *Rheumatology* 2013;52(6):1090–4, <http://dx.doi.org/10.1093/rheumatology/kes433>.
22. Catay E, Ruta S, Rosa J, Navarta DA, Scolnik M, Garcia-Monaco R, et al. Knee effusion: sensitivity and specificity of ultrasound for the identification of calcium pyrophosphate crystals. *Arthritis Rheum* 2013;65(Suppl 10):859.
23. Checa A, Wong H, Chun W. Sonographic characterization of mixed crystal arthropathy due to monosodium urate and calcium pyrophosphate dihydrate: the triple-contour sign. *J Ultrasound Med* 2011;30(6):861–2.
24. Ciapetti A, Filippucci E, Gutierrez M, Grassi W. Calcium pyrophosphate dihydrate crystal deposition disease: sonographic findings. *Clin Rheumatol* 2009;28(3):271–6, <http://dx.doi.org/10.1007/s10067-008-1034-6>.
25. Dejaco C. SP0018 The practical case: is it really easy to distinguish gout from CPPD by ultrasound? Live case with patient. *Ann Rheum Dis* 2013;72(Suppl 3):A5, <http://dx.doi.org/10.1136/annrheumdis-2013-eular.18>.
26. Di Geso L, Filippucci E, Gutierrez M, Grassi W. Calcium pyrophosphate deposition: sonographic features in a familial case. *J Rheumatol* 2012;39(7):1488–90.
27. Di Geso L, Tardella M, Gutierrez M, Filippucci E, Grassi W. Crystal deposition at elbow hyaline cartilage: the sonographic perspective. *J Clin Rheumatol* 2011;17(6):344–5, <http://dx.doi.org/10.1097/RHU.0b013e31822e0d36>.
28. Delle Sedie A, Riente L, Iagnocco A, Filippucci E, Meenagh G, Grassi W, et al. Ultrasound imaging for the rheumatologist X. Ultrasound imaging in crystal-related arthropathies. *Clin Exp Rheumatol* 2007;25(4):513–7.
29. Dufauget-Lombard C, Vergne-Salle P, Simon A, Bonnet C, Treves R, Bertin P. Ultrasonography in chondrocalcinosis. *Joint Bone Spine* 2010;77(3):218–21, <http://dx.doi.org/10.1016/j.jbspin.2009.12.001>.
30. Ellabban AS, Kamel SR, Omar HAA, El-Sherif AM, Abdel-Magied RA. Ultrasonographic findings of Achilles tendon and plantar fascia in patients with calcium pyrophosphate deposition disease. *Clin Rheumatol* 2012;31(4):697–704, <http://dx.doi.org/10.1007/s10067-011-1911-2>.
31. Ellabban AS, Kamel SR, Omar HASA, El-Sherif AMH, Abdel-Magied RA. Ultrasonographic diagnosis of articular chondrocalcinosis. *Rheumatol Int* 2012;32(12):3863–8, <http://dx.doi.org/10.1007/s00296-011-2320-1>.
32. Farina A, Filippucci E, Grassi W. Sonographic findings of the synovial fluid. *Reumatismo* 2002;54(3):261–5.
33. Filippou G, Adinolfi A, Bozios P, Lorenzini S, Picerno V, Di Sabatino V, et al. Do not hallow until you are out of the wood! Ultrasonographic detection of CPP crystal deposits in menisci: facts and pitfalls. *Sci World J* 2013;2013:1–6, <http://dx.doi.org/10.1155/2013/181826>.
34. Filippou G, Bozios P, Gambera D, Lorenzini S, Bertoldi I, Adinolfi A, et al. Ultrasound detection of calcium pyrophosphate dihydrate crystal deposits in menisci: a pilot in vivo and ex vivo study. *Ann Rheum Dis* 2012;71(8):1426–7, <http://dx.doi.org/10.1136/annrheumdis-2011-201001>.
35. Filippou G, Adinolfi A, Lorenzini S, Bertoldi I, Di Sabatino V, Picerno V, et al. Diagnostic accuracy of ultrasound, X-rays and synovial fluid in the diagnosis of calcium pyrophosphate dihydrate deposition disease. Is it CPPD? *Ask US. Arthritis Rheum* 2014;66(S10):S77.
36. Filippou G, Filippucci E, Tardella M, Bertoldi I, Di Carlo M, Adinolfi A, et al. Extent and distribution of CPP deposits in patients affected by calcium pyrophosphate dihydrate deposition disease: an ultrasonographic study. *Ann Rheum Dis* 2013;72(11):1836–9, <http://dx.doi.org/10.1136/annrheumdis-2012-202748>.
37. Filippucci E, Di Geso L, Grassi W. Tips and tricks to recognize microcrystalline arthritis. *Rheumatology* 2012;51(Suppl 7):vii18–21, <http://dx.doi.org/10.1093/rheumatology/kes332>.
38. Filippucci E, Delle Sedie A, Riente L, Di Geso L, Carli L, Ceccarelli F, et al. Ultrasound imaging for the rheumatologist. XLVII. Ultrasound of the shoulder in patients with gout and calcium pyrophosphate deposition disease. *Clin Exp Rheumatol* 2013;31(5):659–64.
39. Filippucci E, Di Geso L, Girolimetti R, Grassi W. Ultrasound in crystal-related arthritis. *Clin Exp Rheumatol* 2014;32(1 Suppl 80):S42–7.
40. Gutierrez M, Di Geso L, Filippucci E, Grassi W. Calcium pyrophosphate crystals detected by ultrasound in patients without radiographic evidence of cartilage calcifications. *J Rheumatol* 2010;37(12):2602–3, <http://dx.doi.org/10.3899/jrheum.100653>.
41. Gutierrez M, Di Geso L, Salaffi F, Carotti M, Girolimetti R, De Angelis R, et al. Ultrasound detection of cartilage calcification at knee level in calcium pyrophosphate deposition disease: ultrasound in calcium pyrophosphate deposition disease. *Arthritis Care Res* 2014;66(1):69–73, <http://dx.doi.org/10.1002/acr.22190>.
42. Gutierrez M, Filippucci E, Salaffi F, Grassi W. Il ruolo attuale dell'ecografia nelle artropatie da microcristalli. *Reumatismo* 2009;61(3):216–21.
43. Juge P-A, Ottaviani S, Aubrun A, Palazzo E, Dieude P. SAT0535 Sensitivity and reproducibility of ultrasonography in calcium pyrophosphate crystal deposition: a case–control study. *Ann Rheum Dis* 2014;73(Suppl 2):784–5, <http://dx.doi.org/10.1136/annrheumdis-2014-eular.3849>.
44. Kudaeva F, Vladimirov S, Bozhieva L, Smirnov A, Volkov A, Barskova V. SAT0354 Usefulness of imaging techniques in mixed crystal deposition (Pilot study). *Ann Rheum Dis* 2013;72(Suppl 3):A703, <http://dx.doi.org/10.1136/annrheumdis-2013-eular.2079>.
45. Magarelli N, Amelia R, Melillo N, Nasuto M, Cantatore F, Guglielmi G. Imaging of chondrocalcinosis: calcium pyrophosphate dihydrate (CPPD) crystal deposition disease – imaging of common sites of involvement. *Clin Exp Rheumatol* 2012;30(1):118–25.
46. Monteforte P, Brignone A, Rovetta G. Tissue changes detectable by sonography before radiological evidence of elbow chondrocalcinosis. *Int J Tissue React* 2000;22(1):23–5.
47. Russell E, Checa A. Potential pitfalls in the diagnosis of crystal-induced arthritis and in the sonographic measurement of hyaline cartilage due to the presence of joint effusion. *J Clin Rheumatol* 2013;19(2):98–100, <http://dx.doi.org/10.1097/RHU.0b013e31828635c5>.
48. Sofka CM, Adler RS, Cordasco FA. Ultrasound diagnosis of chondrocalcinosis in the knee. *Skeletal Radiol* 2002;31(1):43–5, <http://dx.doi.org/10.1007/s002560100434>.
49. Chowalloor PV, Keen HI. A systematic review of ultrasonography in gout and asymptomatic hyperuricaemia. *Ann Rheum Dis* 2013;72(5):638–45, <http://dx.doi.org/10.1136/annrheumdis-2012-202301>.