

In Vivo Distribution of Corneal Epithelial Dendritic Cells in Patients With Glaucoma

Rodolfo Mastropasqua,¹ Luca Agnifili,² Vincenzo Fasanella,² Andrea Lappa,² Lorenza Brescia,² Manuela Lanzini,² Francesco Oddone,³ Paolo Perri,⁴ and Leonardo Mastropasqua²

¹Ophthalmology Unit, Department of Neurological, Neuropsychological, Morphological, and Movement Sciences, University of Verona, Verona, Italy

²Ophthalmology Clinic, Department of Medicine and Aging Science, University G. d'Annunzio of Chieti-Pescara, Chieti, Italy

³Istituto di Ricovero e Cura a Carattere Scientifico, Fondazione G.B. Bietti, Roma, Italy

⁴Department of Biomedical and Surgical Sciences, Division of Ophthalmology, University of Ferrara, Ferrara, Italy

Correspondence: Luca Agnifili, Ophthalmology Clinic, Via dei Vestini, 66100, Chieti, Italy; l.agnifili@unich.it.

RM and LA contributed equally to the work presented here and should therefore be regarded as equivalent authors.

Submitted: July 15, 2016

Accepted: October 3, 2016

Citation: Mastropasqua R, Agnifili L, Fasanella V, et al. In vivo distribution of corneal epithelial dendritic cells in patients with glaucoma. *Invest Ophthalmol Vis Sci.* 2016;57:5996–6002. DOI:10.1167/iovs.16-20333

PURPOSE. The purpose of this study was to evaluate dendritic cell (DC) distribution, morphology, and DC density in the entire cornea of medically controlled glaucoma patients (MCGP), using in vivo confocal microscopy (IVCM).

METHODS. Fifty MCGP were enrolled, 15 patients with dry eye, and 15 healthy subjects served as controls. Patients were asked to complete the Ocular Surface Disease Index (OSDI) questionnaire and then underwent tear film break-up time (BUT), corneal staining, and Schirmer test (ST) I and then IVCM. In vivo confocal microscopy evaluated the limbal and central DC density, the DCs morphology and distribution. Relationships among DC density, OSDI score, and corneal staining were analyzed.

RESULTS. Medically controlled glaucoma patients were divided into 2 groups; group 1 (29 eyes) was tested with one drug; group 2 (21 eyes) was tested with ≥ 2 drugs. Dendritic cells were significantly higher at limbus than at central cornea in both groups. Limbal DCs were found in the 86.7%, 89.7%, 90.4%, and 93.3% of eyes in controls, groups 1 and 2, and DED; central corneal DCs were found in the 26.6%, 75.9%, 80.9%, and 86.6% of eyes in controls, groups 1 and 2, and DED. Dendritic cell density was higher in glaucoma groups and DED than in controls ($P < 0.001$). Group 2 and DED presented DC density significantly higher compared with group 1 ($P < 0.05$). In group 1 DC density was higher in patients taking preserved drugs than in those taking preservative-free drugs ($P < 0.05$). Dendritic cell density was higher in DED than in group 2 ($P < 0.05$). Dendritic cell density significantly correlated with corneal staining and OSDI ($P < 0.001$).

CONCLUSIONS. Dendritic cells increase in the entire cornea of MCGP, with a higher density at limbus. These modifications may take part in the induction of the glaucoma-related ocular surface disease.

Keywords: antiglaucoma therapy, cornea, dendritic cells, glaucoma, glaucoma-related ocular surface disease, in vivo confocal microscopy, limbus

The daily instillation of IOP-lowering medications produces several alterations of the ocular surface in patients with glaucoma.^{1,2} Over the past 2 decades, in vivo confocal microscopy (IVCM), which permits a noninvasive in vivo cytologic observation of the ocular surface structures greatly increased the knowledge of these alterations.^{3–9}

In medically controlled glaucoma patients (MCGP), the cornea is one of the most altered tissues, with modifications involving all epithelial layers, subbasal nerve plexus, stroma, and endothelium.^{4,5} The most prominent changes include variations of the epithelial cells densities, stromal keratocyte activation, depletion of subbasal plexus nerves, and polymegathism and pleomorphism of endothelial cells. Antiglaucoma therapy also deeply affects the limbus in terms of worsening of transitional epithelium regularity, inflammation of Vogt's palisades, and increase in dendritic cells (DCs).⁸

Dendritic cells are bone marrow-derived professional antigen-presenting cells (APCs) that populate the interstitial tissue of solid organs. Within the cornea, which normally hosts

different populations of resident DCs,¹⁰ Langerhans cells (a subpopulation of DCs) represent the main APCs. These cells modulate the immune response toward pathogenic stimuli under different conditions, such as dry eye, infective keratitis, vernal keratoconjunctivitis, and contact lens wear and after different medical or surgical treatments.^{11–16}

Corneal DCs exist in immature and mature forms with a unique morphology, although with a different expression of their features. They may be located at the superficial, intermediate, or basal epithelium, at the basal lamina, and at the subbasal nerve plexus layer. Zhivov et al.¹⁵ found that in normal subjects, the DC density declines from peripheral toward central cornea. In the presence of inflammatory ocular surface conditions, DCs increases in both the central and peripheral regions of the cornea and become activated after up-regulation of MHC class II expression.¹¹

As observed at the limbus, DCs play a significant role in the development of glaucoma-related ocular surface disease (OSD), because DC density correlated with the clinical indices of



ocular surface inflammation.⁸ To date, no previous study has specifically investigated DCs in the entire cornea in MCGP and whether they have a role in the development of the OSD. We conducted the present study to evaluate the morphology, distribution, and density of DCs in the central and peripheral cornea in differently treated MCGP, by using IVCM.

METHODS

Patient Enrollment

This was an observational study that adhered to the tenets of the Declaration of Helsinki; the institutional review board approved the study (Department of Medicine and Ageing Science, G. d'Annunzio University of Chieti-Pescara, Chieti, Italy). We consecutively enrolled 72 Caucasian patients (50 eyes) who were referred to the Glaucoma Centre, affected with medically controlled open angle glaucoma. Fifteen age- and sex-matched patients (15 eyes) with Sjögren syndrome-related dry eye disease (DED; defined using International Dry Eye Workshop criteria)¹⁷ who also were referred to our Ocular Surface Diseases Centre and enrolled. Healthy controls required 15 age- and sex-matched Caucasian subjects (15 eyes) referred to the General Clinic for the control of refraction. Written informed consent was obtained from all patients prior to enrollment, after explanation of the nature and possible consequences of the study.

Inclusion criteria for patients with glaucoma were best corrected visual acuity $\geq 8/10$, mean IOP at the time of diagnosis ≥ 22 mm Hg and medically controlled at enrollment (IOP < 18 mm Hg; mean of three measurements taken at 9 AM, 12 noon, and 4 PM), central corneal thickness (obtained by ultrasound pachymetry; Altair; Optikon 2000, Rome, Italy) ranging from 530 to 570 μm , visual field test (30-2 test, full-threshold; Humphrey field analyzer II 750; Carl Zeiss Meditec, Inc., Dublin, CA, USA) showing at least three contiguous points on the total deviation probability plot at a level less than 2%, glaucoma hemifield test "outside normal limits," and ophthalmoscopic signs of glaucomatous optic consistent with the visual field alterations. Topical therapy had to be the same in both eyes, without any variation during the 12 months immediately prior to enrollment.

The exclusion criteria were history of systemic or ocular inflammatory diseases and systemic or topical therapies in the last 12 months that could have modified the corneal status, previous ocular surgery, laser therapy, trauma, chemical burn, end-stage glaucoma, pregnancy, and contact lens wear. Patients with a history of corneal dystrophies and dry eye prior to glaucoma diagnosis and who were beginning treatment were also excluded.

Patients with dry eye disease and healthy controls had to show a best correct visual acuity of $\geq 8/10$, a mean IOP lower than 18 mm Hg, a central cornea thickness ranging from 530 to 570 μm , absence of glaucomatous optic neuropathy, and a visual field examination with normal results. At the moment of enrollment, patients with DED were treated with lubricants at least five times a day (using preservative-free sodium hyaluronate or carboxymethylcellulose sodium) and did not receive topical steroids during the last 2 months.

Exclusion criteria for DED were non-Sjögren syndrome-related dry eye disease, ocular lymphoma, autoimmune deficiency syndrome, sarcoidosis, diabetes mellitus, corneal dystrophy, and non-DED-related ocular surface inflammatory diseases, systemic or topical therapy potential affecting the corneal status, glaucoma, topical therapy with steroids or non-steroidal anti-inflammatory drugs, use of contact lens, and previous ocular surgery. Exclusion criteria for normal controls

were history of systemic or topical therapy, ocular or systemic diseases in the previous 12 months, pregnancy, and contact lens wear. Both of the eyes were evaluated, but one eye per subject was randomly chosen (using a computer-generated random number list) for statistical analysis.

Patient Clinical Assessment

Each subject enrolled in the study underwent a careful slit lamp examination of both the anterior and posterior segments of the eye. Clinical tests included an OSD Index (OSDI) questionnaire and tear film function tests.

After all patients completed biomicroscopic examination, they were asked to complete the OSDI questionnaire and underwent tear film function tests. According to Dry Eye Workshop (DEWS) guidelines, tear film break-up time (BUT), corneal staining, and Schirmer test I (STI; 30 minutes after BUT measurements) were consecutively performed, after the OSDI questionnaire was completed.¹⁸ Break-up time was recorded as the average of three consecutive measurements; STI results were expressed as the length of the strip that was wet after 5 minutes; corneal staining was evaluated with 1% sodium fluorescein (using the van Bijsterveld method).¹⁹

IVCM of the Cornea

Twenty-four hours after clinical assessment, the central corneal and limbal epithelia were examined using a digital corneal confocal laser-scanning microscope (HRT III Rostock cornea module; Heidelberg Engineering GmbH, Dossenheim, Germany) to visualize DCs.

The confocal laser-scanning device was equipped with a water immersion objective (633/numerical aperture 0.95 W; Zeiss, Jena, Germany). The device allows for automatic z-scanning, determining focus depth within the cornea, and collecting and storing high-contrast digital images of corneal and limbal layers with a $400 \times 400 \mu\text{m}$ field of view, for a depth range of 90 μm beginning from the reference layer. The theoretical confocal section thickness is approximately 10 μm . This is the slice thickness (voxel), which is imaged by the confocal microscope to form a two-dimensional pixel-based digital image; the lateral and transverse resolution is 4 μm .

In vivo confocal microscopy was performed with the patient under topical anesthesia with 0.4% oxybuprocaine eye drops. The appropriate positioning and alignment of the head was maintained with a dedicated movable-target red fixation light for the fellow eye. A digital camera mounted on a side arm provided a lateral view of the eye and objective lens to monitor the position of the lens on the surface of the eye. A drop of 0.2% polyacrylic gel served as coupling medium between the poly (methyl methacrylate) contact cap of the objective lens and cornea.

The examinations were performed at the central cornea (4×4 mm) and, afterwards, at the limbus (12, 3, 6, and 9 o'clock positions, that is superior, temporal, inferior, and nasal quadrants); sequential images were derived from automatic scans and manual frame acquisition in the scheduled sectors. The "section mode" function of the instrument helped to search for DCs within the corneal and limbal epithelial layers, enabling instantaneous imaging of a single area at a desired depth.

Dendritic cells were examined to determine their morphology, distribution, and density at both the central cornea and limbus. Dendritic cells are normally located within the central and limbal epithelia, the basal lamina, and the subbasal nerve plexus layer, at a depth of 40 to 60 μm .

Dendritic cells show a different morphology depending on their maturity and activation. Mature, activated DCs show a

TABLE 1. Demographics and Clinical Data of Controls, Dry Eye, and Glaucoma Groups

Group	Mean \pm SD Age, y	Males/Females	Mean \pm SD IOP, mm Hg	Mean \pm SD MD, dB	Mean \pm SD Time Receiving Therapy, Months†
Controls	57.26 \pm 5.64	8/7	15.24 \pm 2.43	+1.53 \pm 0.56	NA
DED	55.32 \pm 4.56	6/9	16.82 \pm 2.65	+1.35 \pm 0.65	72.6 \pm 11.3
Group 1	58.68 \pm 3.45	15/14	15.63 \pm 2.57	-3.32 \pm 0.52*	70.2 \pm 9.5
Group 2	58.42 \pm 4.45	11/10	16.58 \pm 2.25	-4.34 \pm 1.34*	72.8 \pm 10.3

dB, decibel; DED, dry eye disease; MD, mean defect; NA, not applicable; SD, standard deviation.

* $P < 0.05$ versus healthy controls and dry eye.

† Time receiving therapy matched with the time of diagnosis.

slender cell body from which a network of long membrane processes extend resembling dendrites of nerve cells; immature DCs show a large body with fewer and shorter processes, if any. Usually, the peripheral cornea is populated by both of the phenotypes, whereas the central cornea has just the immature phenotype.¹⁴

Forty images from the central cornea, and 60 from the limbus were acquired from each eye; at least 60 randomly selected high-quality images without motion blur or compression lines (20 from the central corneal and 40 from the limbus, 10 for each limbal sector) were analyzed to determine DC density.

Dendritic cell density (cells/mm²) was calculated using the analysis software in the confocal microscope, by averaging numbers of cells from five images in each position (randomly selected among the recorded images), counted manually within a region of interest of standardized dimensions (250 \times 250 μ m).

The confocal examination lasted 5 minutes, and none of the patients experienced significant complications at the end of the session. A single operator (VF) performed confocal examinations and selected the images, which were evaluated by a second operator (LB). The operators were masked from the subject's history and from grouping.

The primary outcomes were the mean DC density of the central cornea and the mean DC density of the entire limbus. The secondary outcomes were the OSDI score and corneal staining.

TABLE 2. Therapy for Glaucomatous Patients

Group	Therapy	n
Group 1	Single	29
	β -blockers	14
	Timolol 0.5% (BAK 0.01)	7
	PF-timolol 0.5%	7
	PGAs	15
	Bimatoprost 0.001% (BAK 0.02)	8
	PF-tafluprost 0.015%	7
Group 2	Double or more	21
	Latanoprost 0.005%-timolol 0.5% fixed combination (BAK 0.04)	5
	Bimatoprost 0.001% (BAK 0.02) and BAK-preserved timolol 0.5%, unfixed combination	4
	Brimonidine 0.2% and timolol 0.5%, fixed combination (BAK 0.05)	3
	Dorzolamide-timolol 0.5% fixed combination (BAK 0.0075)	4
	Bimatoprost 0.001%, brimonidine and timolol 0.5% fixed combination	3
	Bimatoprost 0.001%, brimonidine 0.2% (BAK 0.05), and dorzolamide-timolol 0.5% fixed combination	2

BAK (benzalkonium chloride), % (mg/ml); PF, preservative-free; PGAs, prostaglandin analogs.

Statistical Analysis

Sample size calculation indicated that at least 50 patients were necessary to have an α of 0.05 and a β of 0.80. Analysis was performed using SPSS advanced statistical version 13.0 software (Chicago, IL, USA). Student's *t* and chi-squared tests were used to evaluate age and sex differences (respectively) between controls, glaucomatous, and dry eye patients. Mann-Whitney *U* test was used to determine differences among groups of patients. Spearman's correlation was used to analyze the relationships between DC density and OSDI score, BUT, STI, and corneal staining. *P* values less than 0.05 were considered statistically significant.

RESULTS

Demographics

Table 1 shows the demographic and clinical data of enrolled subjects. According to the number of antiglaucoma medications they were taking, glaucomatous patients were divided into two groups: group 1 (29 eyes) received monotherapy, and group 2 (21 eyes) received multitherapy (two or more drugs). Table 2 shows the treatment of glaucomatous patients at the moment of enrollment. Therapy for all group 1 patients was not modified from treatment onset. More than 80% of patients with DED presented with a severity level 2, according to criteria previously reported.¹⁷

Ocular Surface Clinical Tests

The OSDI questionnaire score, BUT, and fluorescein corneal staining were significantly different between glaucomatous groups and controls (Table 3). In overall group 1, the OSDI score and corneal staining were significantly higher than those in group 2, whereas BUT and STI were lower ($P < 0.05$). In DED, the OSDI score and corneal staining were significantly higher than those in healthy controls ($P < 0.001$) and in group 1 ($P < 0.05$), with BUT and STI lower. No significant differences were found between DED and group 2. Figure 1 shows the corneal fluorescein staining in glaucoma groups, dry eyes, and healthy controls.

IVCM of the Cornea

In vivo confocal microscopy clearly distinguished among DCs in all examined subjects; reliable images of the central cornea and limbus were obtained in all cases.

DC Morphology

Dendritic cells appeared as hyperreflective elongated cellular structures, presenting dendritic processes according to their maturity, and were found mainly at a depth of 35 to 65 μ m. They populated the central cornea extending from the

TABLE 3. Ocular Surface Clinical Tests

Group	Mean \pm SD OSDIs	Mean \pm SD BUT	Mean \pm SD STI	Mean \pm SD Corneal Staining
Controls	7.9 \pm 0.7*	16.1 \pm 1.5*	14.3 \pm 2.3*	0.6 \pm 1.1*
DED	56.9 \pm 6.3‡	3.4 \pm 1.9‡	4.3 \pm 1.7‡	2.6 \pm 1.4‡
Group 1	21.3 \pm 5.7†	11.2 \pm 2.5†	11.3 \pm 2.4†	1.6 \pm 1.3†
PF drugs	18.7 \pm 4.9	10.9 \pm 2.1	10.5 \pm 1.9	1.4 \pm 1.2
Preserved drugs	23.7 \pm 3.2	11.5 \pm 3.1	12.1 \pm 2.6	1.9 \pm 1.4
Group 2	51.4 \pm 7.1	6.6 \pm 1.4	7.9 \pm 1.7	2.4 \pm 1.9

BUT, break-up time; DED, dry eye disease; OSDI, ocular surface disease index; PF, preservative-free; STI, Schirmer test I.

* $P < 0.001$ versus DED, overall group 1 and group 2.

† $P < 0.05$ versus group 2.

‡ $P < 0.05$ versus group 1.

intermediate epithelial layers to the subbasal nerve plexus, just above Bowman's layer; at the limbus, DCs were observed mainly at the basal layer and basal membrane. However, in most patients, DCs were found mainly found within the subbasal nerve plexus.

Evident morphologic differences were noted between controls and patients with glaucoma or DED (Fig. 2). In healthy subjects, corneal and limbal DCs presented a moderate reflectivity and a mildly elongated cellular body with, very rarely, small dendritic processes. In cornea and limbus of glaucomatous and dry eye patients, DCs showed a more reflective and elongated cellular body with more dendritic processes and, sometimes, a tendency to cluster.

Morphologic differences were found at both central cornea and limbus in subclasses of group 1 and between groups 1 and 2. Group 2 and DED were not particularly different from each other, except for the presence of slightly more elongated DCs in DED. In group 1, patients taking preserved medications presented higher evidence of dendritic processes along with a greater presence of globular cells. Also punctate hyperreflective elements, which are considered additional confocal signs of inflammation,^{4,6,8} were slightly more evident in eyes receiving benzalkonium chloride (BAK) preserved formulations. Overall, patients treated with prostaglandin analogs (PGA) presented with higher evidence of mature DCs and with elongated cellular body and dendritic processes than patients treated with β -blockers. Clear morphologic differences were not found between preservative-free (PF) PGA and PF β -blocker-treated eyes. Compared to patients taking monotherapy, groups 2 and DED presented highly reflective and mature DCs, with a greater number of dendritic processes and tendency to cluster.

In glaucomatous patients receiving multitherapy and dry eye, DCs presented a higher linear length than those in patients in the monotherapy group and healthy subjects (up to 30–35 μ m versus up to 20–25 μ m, respectively).

DC Distribution

In the limbal epithelium, DCs were observed in 86.7% of healthy subjects (13 of 15 subjects), 89.7% of eyes in group 1 (26 of 29 subjects), 90.4% of group 2 (19 of 21 subjects), and 93.3% of DED (14 of 15 subjects). Differences among groups were not statistically significant. In the central corneal epithelium, DCs were observed in 26.6% of healthy eyes (4 of 15 subjects), in 75.9% (22 of 29 subjects) in group 1, in 80.9% (17 of 21 subjects) in group 2, and 86.6% (13 of 15 subjects) in DED. Differences between healthy controls and patients with DED and glaucoma (both groups) were statistically significant ($P < 0.001$); significant differences were found between DED and group 1 ($P < 0.05$) but not between DED and group 2.

DC Density

Limbal and central DC densities are reported in Tables 4 and 5. In all patients (glaucoma and dry eye) and in healthy controls, DC density was significantly higher in the limbal epithelium with respect to the central cornea epithelium.

Limbal DC Density

Limbal DC density was intended as the mean value of the four quadrants. Limbal DC density was significantly higher in groups 1 and 2 and DED than in healthy controls. Patients taking multitherapy or those affected with dry eye presented values significantly higher with respect to overall patients in monotherapy. In DED, DC density was overall significantly higher than in participants in groups 1 and 2.

In group 1, patients treated with preserved medications showed DC density significantly higher than those in patients treated with PF medications. Preserved PGA and preserved β -blockers did not show significant differences between each

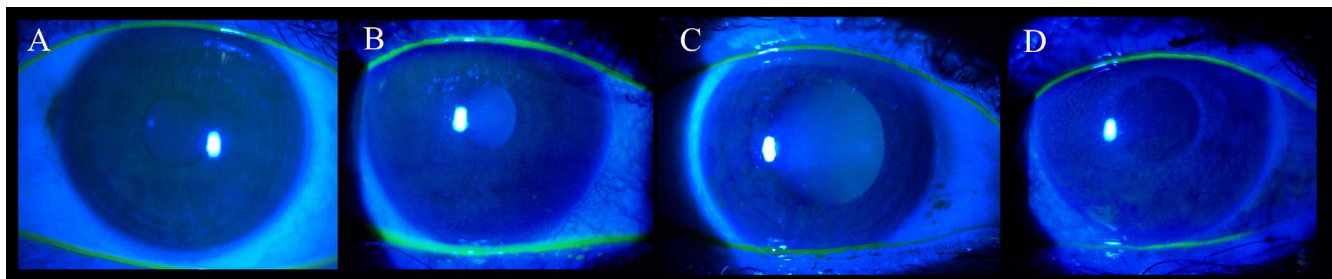


FIGURE 1. Slit lamp biomicroscopy shows the corneal fluorescein staining in healthy controls (A), group 1 (B) BAK-preserved β -blocker, and group 2 (C) BAK-preserved β -blocker/ α -agonist fixed combination plus BAK-preserved PGA and dry eye syndrome (D). Dry eye and multitreated glaucoma patients present an evident epithelial fluorescein staining compared to monotherapy and healthy controls.

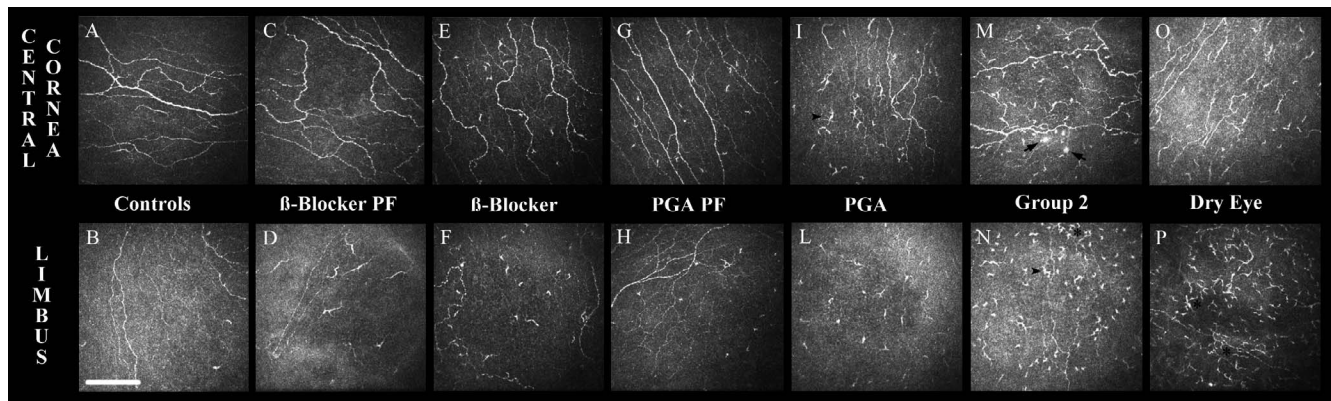


FIGURE 2. Dendritic cells at the central cornea and limbus in glaucoma groups, controls, and dry eye patients. Dendritic cells are significantly more represented in dry eyes (O, P) and group 2 (M, N) than in healthy controls (A, B) and group 1 subclasses (C-L). Group 2 and dry eye patients present clusters of DCs (asterisks) and some highly reflective globular cells (arrows). In group 1, DCs are slightly more represented in patients taking preserved medications (E, F; I, L) than respective PF formulations (C, D; G, H). Overall, patients treated with PGA present more inflammatory signs than patients receiving beta-blockers. In preserved PGA, group 2, and dry eye patients, DCs also present evident dendritic processes (arrowheads). Scale bar: 100 μm.

other; similarly, no significant differences were found between PF PGA and PF beta-blockers. Conversely, preserved PGA showed significantly higher DC density values than PF PGA and PF beta-blockers. Preserved beta-blockers did not show DC density values higher than those of PF monotherapies. For all considered parameters, there were no significant differences among the explored limbal quadrants.

Central Cornea DC Density

Central cornea DC density was significantly higher in group 2 and in DED than in controls; no overall significant differences were found between group 1 and healthy controls. Overall, patients receiving monotherapy presented values significantly lower with respect to patients receiving multitherapy and dry eye patients. Dendritic cell density was significantly higher in DED than overall in groups 1 and 2.

In group 1, patients treated with preserved medications showed DC density values significantly higher than those in patients treated with PF medications. Preserved PGA and preserved beta-blockers did not show significant differences between each other; similarly, no significant differences were found between PF PGA and PF beta-blockers. Conversely, preserved PGA showed significantly higher DC density values than overall PF monotherapy, whereas preserved beta-blockers did not show higher DC density than overall PF monotherapy.

TABLE 4. DC Density in Controls, Dry Eye, and Glaucoma Groups

Group	Mean ± SD Central Cornea DCD, cells/mm ²	Mean ± SD Limbal DCD, cells/mm ²
Controls	7.33 ± 4.96*	33.54 ± 9.84*
DED	147.00 ± 13.29†	200.75 ± 17.89†
Group 1	33.96 ± 18.77‡	75.74 ± 21.87‡
Preserved drugs	50.84 ± 12.23§	92.07 ± 17.75§
PF drugs	20.25 ± 9.51	62.46 ± 15.07
Group 2	85.34 ± 30.21	132.02 ± 27.81

DC, dendritic cells; DCD, dendritic cell density; DCL, dendritic cell length; DED, dry eye disease; PF, preservative-free.
 * P < 0.001 versus DED, group 1 and 2.
 † P < 0.05 versus group 1 and 2.
 ‡ P < 0.05 versus group 2.
 § P < 0.05 versus PF drugs.

Correlations

Both limbal and corneal DC density correlated with corneal staining and OSDI (rho = 0.88 and 0.79, respectively; P < 0.001).

DISCUSSION

Dendritic cells play a crucial role in the innate and adaptive arms of the immune system in most solid organs, including cornea. Healthy corneas normally host a large population of DCs with a density varying from 19 to 100 cells/mm² in the central cornea and limbus, respectively.^{8,11,12,20,21} An inflamed ocular surface profoundly triggers these cells, which increase density and change their morphology into the mature phenotype. Thus, DCs have been considered one of the hallmarks of corneal inflammation in many diseases.^{11,22}

In MCGP, IOP-lowering medications induce a highly inflamed ocular surface microenvironment with stimulation of conjunctival, limbal, and central cornea DCs.¹⁻⁸ Nonetheless, to date, the role of corneal DCs in the development of

TABLE 5. DC Density in Group 1

Group	Mean ± SD Corneal DCD, cells/mm ²	Mean ± SD Limbal DCD, cells/mm ²
Controls	7.33 ± 4.96*	33.54 ± 9.84*
DED	147.00 ± 13.29	200.75 ± 17.89
Preserved beta-blockers	42.57 ± 9.37†	78.82 ± 7.03‡
PF beta-blockers	17.50 ± 4.24§	52.97 ± 7.69§
Preserved PGA	60.50 ± 6.77	107.54 ± 12.19**
PF PGA	23.00 ± 12.60††	71.97 ± 14.88‡‡

DC, dendritic cells; DCD, dendritic cell density; DCL, dendritic cell length; DED, dry eye disease; PF, preservative-free.
 * P < 0.001 versus DED.
 † P < 0.05 versus controls; P < 0.001 versus DED.
 ‡ P = 0.002 versus controls; P < 0.001 versus DED.
 § P < 0.001 versus DED.
 || P = 0.03 versus PF beta-blockers; P < 0.05 versus PF PGA; P < 0.001 versus controls and dry eye.
 ** P < 0.001 versus PF beta-blockers; P < 0.05 versus PF PGA; P < 0.001 versus controls and DED.
 †† P < 0.001 versus DED.
 ‡‡ P < 0.05 versus controls; P < 0.001 versus DED.

glaucoma-related OSD has not been adequately investigated. For the most part, studies have focused on alterations of epithelial cells, subbasal nerve plexus, stromal keratocytes, and endothelium, while also reporting limited information regarding DCs,^{1,3-5} despite the DC density correlates with corneal inflammation; and the corneal inflammatory status plays a primary role in glaucoma-related OSD.^{11,23,24} In histology, DCs were observed within the limbus and conjunctiva of patients with glaucoma, expressing proinflammatory cytokines and showing the mature phenotype.^{2,25} Using confocal microscopy of DCs was described within the epithelium and the basement membrane of the conjunctiva and within the limbal and central epithelia of the cornea.^{3,4,8,26,27}

In our study, DCs were much more common in MCGP than in healthy eyes and, in line with the DCs distribution in normal and under inflammatory conditions, they were represented more highly at the limbus than at the central cornea.^{11,12,15,20,28}

Interestingly, in glaucomatous patients receiving multitreatment therapy and in patients with dry eye, DCs were observed in a similar percentage of individuals, suggesting that glaucoma medications and dry eye may have a similar impact in terms of corneal inflammation occurrence.

Overall, in patients with glaucoma, the DC density was 2 to 3 times higher at the limbus, and more than 10 times higher in the central cornea than that in healthy controls. In more detail, a 2- to 3-fold higher limbal and central DC density were found in the multitreatment regimen than in the monotherapy regimen, with several cells presenting the mature phenotype.

Patients with DED showed higher DC density than the glaucomatous patients receiving multitreatment, with almost similar morphologic features of DCs. Despite the significant differences between these groups, probably due to the greater inflammation induced by autoimmune disorders (such as Sjögren syndrome), the high DC density values also in group 2 suggest the presence of a similar immunoinflammatory microenvironment in DED and glaucoma therapy-related OSD. Other studies confirm this hypothesis, because in patients with Sjögren syndrome, DC densities were similar to those observed in glaucoma treated with multitreatment in our study (127.9 ± 23.7 cells/mm² and 157.2 ± 29.7 cells/mm² in the central and peripheral cornea, respectively).²⁰ These findings appear to be confirmed further by the fact that, in our study, the corneal staining was markedly increased in both group 2 and DED, with values not significantly different. Although with mild differences, these results were also in line with those reported in the corneoscleral limbus, in which DC density, OSDI, and corneal staining were found similarly increased in multitreated glaucoma and dry eye.⁸

However, given the retrospective nature of the study, whether the DC density increase depends on the primary toxicity of medications^{1,3-5,8} or is a consequence of the iatrogenic dry eye cannot be determined.

Conversely, our findings appear in contrast with the results of a recent study of Villani et al.,²⁶ who reported that, in stable medically controlled primary open-angle glaucoma, the ocular surface changes due to the therapy are mostly subclinical.²⁶ This could depend on different variables, such as the duration of the disease and therapy (which were not reported in that study), the concomitant (or past) use of lubricants and/or anti-inflammatory agents to contain the OSD, or an inter-individual variability in the response to the drug-mediated toxicity and inflammation.

When we focused on monotherapies, we observed preserved medications induced higher DC density than the corresponding PF formulations, due to the ability of BAK to increase inflammatory mediators and, thus, to promote maturation and recruitment of DCs.^{8,15,26}

Zhivov et al.²¹ confirmed this hypothesis as reported that after 12 weeks of administration of BAK 0.01% eye drops in healthy volunteers, the Langerhans cells density significantly increased in the central and limbal corneal epithelia. Similar findings were observed in patients with glaucoma, where high levels of activated Langerhans cells were found in 100% of eyes after 12 months of therapy with preserved medications (Zhivov A, et al. *IOVS* 2007;48:ARVO E-Abstract 4303). The deep stimulating effect of BAK on DCs was further supported by a recent confocal study in which BAK-preserved travoprost induced a higher corneal DC density than polyquad-preserved travoprost.²⁹

Because we did not find significant differences between preserved PGA and preserved β -blockers or between PF PGA and PF β -blockers, we cannot determine whether the preservative or the active compound played the main role in the final DC increase. However, because preserved PGA produced the highest degree of DCs stimulation, one may hypothesize that, even though both preservative and active compound are required to recruit DCs, PGA appear more triggering than β -blockers. This is in agreement with previous studies, which documented the high inflammatory effect of this class of medication also on other ocular surface structures.^{3,6,8}

One of the most remarkable considerations is that DC density steeply increases when patients move from a mono- to a multitreatment. Thus, besides the duration of therapy, the number of daily instillations and the cumulative exposure to BAK appear as the most important factors leading to the burst of the corneal inflammation.

Comparing our results with those reported in different immune-mediated inflammatory corneal diseases, the data were conflicting. On one hand, in patients with keratitis or graft rejection after keratoplasty, Mayer et al.²⁸ found central DC density values very similar to those we found in multitreated glaucoma patients. On the other hand, in analogous conditions, Mastropasqua et al.¹¹ reported DC density markedly higher.

These differences could depend on the high interindividual variability of DCs, the different immunogenicity of antigens, the nature of the immune disorders, and the stage of the disease, which may affect the intensity of the corneal response to the inflammatory triggers. Nevertheless, despite certain differences, our results may imply that the corneal microenvironment in glaucoma could be similar to an immune-mediated condition, even though with a less intense inflammatory component.

Some limitations need to be pointed out. First, this is a retrospective study; thus, we cannot establish whether DCs increase first at the limbus or at the central cornea, although Zhivov et al.²¹ reported that Langerhans cells increase more rapidly in the center than in the periphery after BAK exposure. It may be hypothesized that the iatrogenic stimulation first leads DCs to migrate from the limbus (where more of these cells are found) toward the central cornea, with a concomitant or subsequent activation of resident central stroma DCs. To clarify this point, prospective studies in patients naïve to therapy are required. Second, IVCM provides only morphologic and morphometric data for DCs; therefore, other cell phenotypes may be included in error in this cell population. Third, we did not investigate other corneal features, that is, we cannot state whether the DC density correlates with other crucial corneal changes such as those affecting the subbasal nerve plexus or the superficial epithelial layers.

In conclusion, IOP-lowering medications deeply trigger corneal DCs, which convert to their mature form and populate the entire cornea widely. The presence of BAK and the number of medications daily used represent the most important

contributing factors for the DCs increase. Moreover, the strong correlation between DC density and OSDI score supports the hypothesis of a role for DCs in glaucoma-related OSD, giving a clinical weight to these findings. This is in agreement with the recent interpretation of the glaucoma-related OSD as a neuro-inflammatory process, in which corneal nerves alterations and the DCs increase were the most important modifications.²⁶ Further dedicated studies are needed to define the exact role of corneal DCs in the development and maintenance of glaucoma-related OSD.

Acknowledgments

Supported by Fondazione Roma and by the Italian Ministry of Health (FO).

Disclosure: **R. Mastropasqua**, None; **L. Agnifili**, None; **V. Fasanella**, None; **A. Lappa**, None; **L. Brescia**, None; **M. Lanzini**, None; **F. Oddone**, None; **P. Perri**, None; **L. Mastropasqua**, None

References

- Baudouin C, Labbè A, Liang H, Pauly A, Brignole-Baudouin F. Preservatives in eyedrops: the good, the bad and the ugly. *Prog Retin Eye Res.* 2010;29:312-334.
- Baudouin C, Pisella PJ, Fillacier K, et al. Ocular surface inflammatory changes induced by topical anti-glaucoma drugs: human and animal studies. *Ophthalmology.* 1999;106:556-563.
- Mastropasqua L, Agnifili L, Mastropasqua R, Fasanella V. Conjunctival modifications induced by medical and surgical therapies in patients with glaucoma. *Curr Opin Pharmacol.* 2013;13:56-64.
- Mastropasqua L, Agnifili L, Mastropasqua R, et al. In vivo laser scanning confocal microscopy of the ocular surface in glaucoma. *Microsc Microanal.* 2014;20:879-894.
- Martone G, Frezzotti P, Tosi GM, et al. An in vivo confocal microscopy analysis of effects of topical antiglaucoma therapy with preservative on corneal innervation and morphology. *Am J Ophthalmol.* 2009;147:725-735.
- Agnifili L, Fasanella V, Costagliola C, et al. In vivo confocal microscopy of meibomian glands in glaucoma. *Br J Ophthalmol.* 2013;97:343-349.
- Mastropasqua L, Agnifili L, Fasanella V, et al. Conjunctival goblet cells density and preservative-free tafluprost therapy for glaucoma: an in vivo confocal microscopy and impression cytology study. *Acta Ophthalmol.* 2013;91:e397-e405.
- Mastropasqua R, Agnifili L, Fasanella V, et al. Corneoscleral limbus in glaucoma patients: in vivo confocal microscopy and immunocytological study. *Invest Ophthalmol Vis Sci.* 2015;56:2050-2058.
- Ciancaglini M, Carpineto P, Agnifili L, et al. Conjunctival modifications in ocular hypertension and primary open angle glaucoma: an in vivo confocal microscopy study. *Invest Ophthalmol Vis Sci.* 2008;49:3042-3048.
- Hamrah P, Liu Y, Zhang Q, Dana MR. The corneal stroma is endowed with significant numbers of resident dendritic cells. *Invest Ophthalmol Vis Sci.* 2003;44:581-589.
- Mastropasqua L, Nubile M, Lanzini M, et al. Epithelial dendritic cell distribution in normal and inflamed human cornea: in vivo confocal microscopy study. *Am J Ophthalmol.* 2006;142:736-744.
- Kheirkhah A, Rahimi Darabad R, Cruzat A, et al. Corneal epithelial immune dendritic cell alterations in subtypes of dry eye disease: a pilot in vivo confocal microscopic study. *Invest Ophthalmol Vis Sci.* 2015;56:7179-7185.
- Postole AS, Knoll AB, Auffarth GU, Mackensen F. In vivo confocal microscopy of inflammatory cells in the corneal sub-basal nerve plexus in patients with different subtypes of anterior uveitis [published online ahead of print January 28, 2016]. *Br J Ophthalmol.* doi:10.1136/bjophthalmol-2015-307429.
- Niederer RL, McGhee CN. Clinical in vivo confocal microscopy of the human cornea in health and disease. *Prog Retin Eye Res.* 2010;29:30-58.
- Zhivov A, Stave J, Vollmar B, et al. In vivo confocal microscopic evaluation of Langerhans cell density and distribution in the normal human corneal epithelium. *Graefes Arch Clin Exp Ophthalmol.* 2005;243:1056-1061.
- Rosenberg ME, Tervo TM, Müller LJ, et al. In vivo confocal microscopy after herpes keratitis. *Cornea.* 2002;21:265-269.
- Lemp MA, Baudouin C, Baum J, et al. The definition and classification of dry eye disease: report of the Definition and Classification subcommittee of the International Dry Eye Workshop. *Ocul Surf.* 2007;5:75-92. Available at: <http://www.tearfilm.org/dewsreport/pdfs/TOS-0502-DEWS-noAds.pdf>.
- Bron AJ, Abelson MB, Ousler G, et al. Methodologies to diagnose and monitor dry eye disease: report of the Diagnostic Methodology subcommittee of the International Dry Eye Workshop (2007). *Ocul Surf.* 2007;5:108-152. Available at: <http://www.tearfilm.org/dewsreport/pdfs/TOS-0502-DEWS-noAds.pdf>.
- Van Bijsterveld OP. Diagnostic tests in the sicca syndrome. *Arch Ophthalmol.* 1969;82:10-14.
- Lin H, Li W, Dong N, et al. Changes in corneal epithelial layer inflammatory cells in aqueous tear-deficient dry eye. *Invest Ophthalmol Vis Sci.* 2010;51:122-128.
- Zhivov A, Kraak R, Bergter H, Kundt G, Beck R, Guthoff RE. Influence of benzalkonium chloride on langerhans cells in corneal epithelium and development of dry eye in healthy volunteers. *Curr Eye Res.* 2010;35:762-769.
- Steinman RM. The dendritic cell system and its role in immunogenicity. *Annu Rev Immunol.* 1991;9:271-296.
- Ramli N, Supramaniam G, Samsudin A, Juana A, Zahari M, Choo MM. Ocular surface disease in glaucoma: effect of polypharmacy and preservatives. *Optom Vis Sci.* 2015;92:e222-e226.
- Leung EW, Medeiros FA, Weinreb RN. Prevalence of ocular surface disease in glaucoma patients. *J Glaucoma.* 2008;17:3550-3555.
- Baudouin C, Hamard P, Liang H, Creuzot-Garcher C, Bensoussan L, Brignole F. Conjunctival epithelial cell expression of interleukins and inflammatory markers in glaucoma patients treated over the long term. *Ophthalmology.* 2004;111:2186-2192.
- Villani E, Sacchi M, Magnani F, et al. The ocular surface in medically controlled glaucoma: an in vivo confocal study. *Invest Ophthalmol Vis Sci.* 2016;57:1003-1010.
- Carpineto P, Agnifili L, Nubile M, et al. Conjunctival and corneal findings in bleb-associated endophthalmitis: an in vivo confocal microscopy study. *Acta Ophthalmol.* 2011;89:388-395.
- Mayer WJ, Mackert MJ, Kranebitter N, et al. Distribution of antigen presenting cells in the human cornea: correlation of in vivo confocal microscopy and immunohistochemistry in different pathologic entities. *Curr Eye Res.* 2012;37:1012-1018.
- Marsovszky L, Resch MD, Visontai Z, Németh J. Confocal microscopy of epithelial and Langerhans cells of the cornea in patients using travoprost drops containing two different preservatives. *Pathol Oncol Res.* 2014;20:741-746.