



Invited Review

# Arthroscopic treatment of tibial eminence fracture: a systematic review of different fixation methods

Leonardo Osti<sup>†</sup>, Matteo Buda<sup>‡</sup>, Francesco Soldati<sup>‡</sup>, Angelo Del Buono<sup>§</sup>, Raffaella Osti<sup>‡</sup>, and Nicola Maffulli<sup>\*\*††,\*</sup>

<sup>†</sup>Unit of Arthroscopy and Sports Medicine, Hesperia Hospital, Via Arquá, Modena, Italy, <sup>‡</sup>Department of Orthopedic and Traumatology, University of Ferrara, Via Aldo Moro, Italy, <sup>§</sup>Department of Orthopedic and Trauma Surgery, Ospedale Vaio, Fidenza, Italy, <sup>\*\*</sup>Department of Trauma and Orthopaedic Surgery, University of Salerno, Italy, and <sup>††</sup>Centre for Sports and Exercise Medicine Queen Mary University of London Barts and The London School of Medicine and Dentistry, Mile End Hospital London, UK

\*Correspondence address. Department of Trauma and Orthopaedic Surgery, University of Salerno, Italy. E-mail: n.maffulli@qmul.ac.uk

Accepted 28 March 2016

## Abstract

**Introduction:** Arthroscopy procedures are the gold standard for the management of tibial spine avulsion. This review evaluates and compares different arthroscopic treatment options for tibial spine fractures.

**Source of data:** PubMed, Medline, Ovid, Google Scholar and Embase databases were systematically searched with no limit regarding the year of publication.

**Areas of agreement:** An arthroscopic approach compared with arthrotomy reduces complications such as soft-tissue lesions, post-operative pain and length of hospitalization.

**Areas of controversy:** The use of suture techniques, compared to cannulated screw technique, avoids a second surgery for removal of the screws, but requires longer immobilization and partial weight bearing.

**Growing points:** Clinical outcomes and radiographic results do not seem to differ in relation to the chosen method of fixation.

**Areas timely for developing research:** Further studies are needed to produce clear guidelines to define the best choice in terms of clinical outcomes, function and complications.

**Key words:** arthroscopic treatment, avulsion, fracture, tibial eminence, tibial spine

## Introduction

Avulsion fractures of the tibial spine, first described by Poncet in 1875,<sup>1</sup> are a major intra-articular injury in the paediatric knee<sup>2</sup> and considered equivalent to tears of the anterior cruciate ligament (ACL) in adults.<sup>3</sup>

The most common mechanism of trauma, which leads to a disruption of the not completely ossified tibial spine rather than to failure of the ACL,<sup>4,5</sup> is a trauma forcing the knee in hyperextension combined with valgus-external rotation.<sup>6</sup> At times, these lesions can occur in adults; in this instance, the main cause is high-energy trauma, such as road accidents.<sup>7-9</sup> This specific etiology explains the higher incidence of associated lesions to the menisci or capsulo-ligamentous structures in adults.<sup>1,10,11</sup>

The most common classification for these fractures was developed by Meyers and Mc Keever,<sup>12</sup> and it is reliable for decision-making in diagnosis and treatment. Type I lesions are undisplaced or minimally displaced fractures involving the anterior margin of the spine; Type II fractures present a superior displacement of the anterior part of the fragment, with the posterior portion still attached to the rest of the proximal tibia ('bird's beak' pattern); in Type III lesions the fragment is completely detached. Type III fractures can be further divided into Type IIIA, in which only the ACL insertion is involved, and Type IIIB, in which the whole tibial eminence is involved. Other authors described a Type IV, including comminuted fractures.<sup>13</sup>

The literature supports conservative management with a knee cast or splint in extension or mild flexion (20°–30°) for 6–12 weeks for Type I undisplaced tibial spine fractures<sup>14,15</sup> and surgical treatment for Type II, if reduction is not anatomical,<sup>14,16</sup> and Type III and IV fractures.<sup>17,18</sup> Open surgical techniques have several disadvantages and more complications (soft-tissue damage, higher post-operative pain, longer hospital stay, and delay in rehabilitation). For this reason, arthroscopic techniques are considered the gold standard for the treatment of these lesions: they allow direct visualization of intra-articular injuries, simplified diagnosis, accurate reduction of fracture fragments, treatment of

associated soft-tissue injuries and removal of loose fragments.<sup>9,19,20</sup>

The present study reviews different arthroscopic techniques and methods of fixation of these fractures reported in current literature, describing the state of art for the treatment of this pathology.

## Methods

### Search strategy

In September 2015, a systematic search was conducted in the online PubMed, Google Scholar, CINAHL, Cochrane Central and Embase Biomedical databases using the isolated or combined keyword 'arthroscopic treatment and tibial eminence', 'arthroscopic treatment and tibial spine', 'tibial eminence avulsion', 'tibial spine fracture'; with no limits regarding the year of publication. Articles were included if they reported data on clinical and functional outcomes, complications and radiographic evaluation in series of patients who had undergone arthroscopic treatment for tibial spine avulsion. Two authors (Matteo Buda and Francesco Soldati) screened the selected articles for title, abstract and full text in accordance with predefined inclusion and exclusion criteria. The articles were accurately analysed focusing on objective rating scores, clinical and radiographic assessment and complications reported.

### Criteria for consideration

Given our language capabilities, we considered publications in Italian and English. Two authors (M.B. and S.F.) independently reviewed the content of each abstract. Once an article was identified as likely to be included, full-text versions were obtained to evaluate the exact content of the study. The reference lists of the selected articles were then examined by hand to identify articles not identified at the electronic search. All journals were considered and all relevant articles were retrieved. Studies focusing on clinical outcomes of patients who had undergone arthroscopic treatment of tibial eminences with any device were selected. Biomechanical reports, studies on animals, cadavers, *in vitro* studies, case reports,

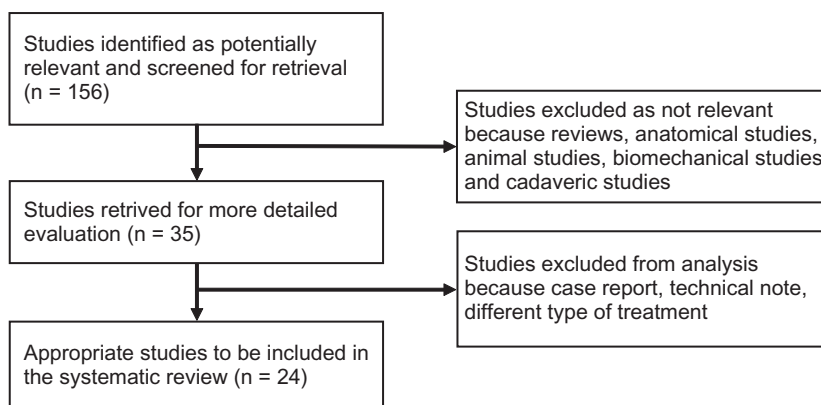


Fig. 1 Study flow chart.

literature reviews, technical notes, letters to editors, instructional course and studies focusing only on complications were excluded. A final article analysis was made by all the authors, and a fully trained orthopaedic surgeon with a special interest in knee surgery and sports medicine (L.O.) made the final decision in cases of doubt (Fig. 1).

## Results

### Literature review

At the first electronic search, we identified 156 relevant publications. After application of the inclusion criteria, 35 studies remained. Of these, 11 studies were excluded because they were case report, technical notes, and described different types of treatment. Twenty-four studies ultimately met the inclusion criteria, 13 were retrospective<sup>20–32</sup> and 11 prospective.<sup>7,33–42</sup> Each study described a different arthroscopic treatment of tibial eminence fracture, reporting also post-operative protocol (Table 1).

### Surgical technique

Different arthroscopic surgical techniques were used in the articles analysed. Arthroscopic reduction and internal fixation (ARIF) with Kirschner wires,<sup>21</sup> cannulated screws,<sup>20,21,23,24,27,31</sup> a Meniscus Arrow device,<sup>33</sup> pull-out sutures,<sup>7,22</sup> suture with anchors,<sup>34,37</sup> metallic suture,<sup>35</sup> transosseous sutures,<sup>24,27–31,38,39,42</sup> intra-articular button,<sup>32</sup> bioabsorbable nail,<sup>36</sup> Herbert screw,<sup>40</sup> Tight-rope fixation,<sup>26</sup> rotator cuff guide

(RCG) device/suture or the RCG device/T-Fix (Acufex) methods,<sup>25</sup> and Meniscal Viper Repair System (Arthrex, Naples, FL)<sup>41</sup> were used.

### Outcome measures

The criteria used for the evaluation of the outcomes were bone union of the fracture on standard AP and lateral views, range of motion (ROM), and specific tests for instability such as the Lachman, pivot shift and drawer test measured by KT-1000 Arthrometer or similar devices. Outcome scores used were Lysholm Knee Score (LKS),<sup>7,20,22–24,27,30,32,34,36,38–41</sup> the Hospital for Special Surgery (HSS) knee score,<sup>22</sup> the International Knee Documentation Committee (IKDC),<sup>7,24,26,27,29,32,34,37,38</sup> Marshal,<sup>20,39</sup> Tegner<sup>7,20,24,27</sup> and VAS scores.<sup>38</sup>

### Rehabilitation protocol

Different rehabilitation protocols were used (Table 2). The length of immobilization and weight-bearing was different in each of the reviewed studies. In summary, rehabilitation depends on the type of fracture, the quality of fixation and patient compliance. Stiffness after surgical procedure is considerably increased compared with conservative treatment, thus early mobilization was recommended. Isometric exercises are usually performed to improve the strength of the quadriceps during the period of immobilization to reduce muscular atrophy.

**Table 1** Type of management, rehabilitation protocol and study population

Author	Study	Technique	Inclusion criteria	Exclusion criteria	Post-operative treatment	Rehabilitation	Post-operative evaluation	Patients, Age; M/F	Type of lesion
Sommerfeldt, 2008 <sup>21</sup>	Retrospective	Arthroscopic reduction and internal fixation (ARIF) with K-wires or cannulated screws	Type II, III and IV	ACL tears and tibial plateau growth plate fracture	Full W-B, in 20° of knee flexion with knee brace	Passive and active ext-flexion without W-B at 3-4 w (week), full W-B and stairs at 6-8 w	Rx, ROM and Lachman test	9 pts (patients), 10,2 y(7-14)	4 Type II, 4 pt Type III, 1 pt Type IV
Wouters, 2011 <sup>33</sup>	Prospective	Meniscus Arrows(11) and ACL-simring device(1)	Type II and III	None	5 w plaster	Progressive W-B, closed-chain exercise and proprioception	Rx, ROM, Lachman test, ADS and KT-1000	11 pts, 12 y (6-15); 4/7	Not indicated
Ahn, 2005 <sup>22</sup>	Retrospective	Pull-out suture	Type III and IV	None	2 w long leg splint and partial W-B until union	Limited motion brace gradually increased ROM	Rx, ROM, Lachman test, ADS, KT-2000, Lysholm	14 pts, 29.7 y (6-47); 3/7	4 Type IIIA, 3 Type IIIB, 3 Type IV; 4 nonunion
Huang, 2008 <sup>7</sup>	Prospective	Pull-out suture	Type II or higher, Lachman and ADS 2+, and acute fractures	None	1 w full-ext brace	Full W-B, isom. ex., 2-4 w ROM 0-60, at 8 w ROM 0-120, 10-12 w cycling, at 6 m sports	Rx, ROM, Lachman, ADS, KT-1000, Lysholm score, Tegner Activity Level, and IKDC	36 pts, 37 y (17-73); 14/22	6 Type II, 16 Type III and 14 Type IV
Vega, 2008 <sup>34</sup>	Prospective	Fixation with suture-anchor	Type III and IV, skeletal immature patient (open physes), and acute (<12 days after trauma)	Follow-up < 6 months	Full-ext brace for 2-3 w, partial W-B	Gradual flexion of the knee	Rx, ROM, Lachman, KT-1000, IKDC and Lysholm	7 pts, 11.8 y (7-20); 5/2	5 Type III, and 2 Type IV
Reynders, 2002 <sup>23</sup>	Retrospective	Cannulated screw fixation with	Type II and III, and acute fractures	Type I	Knee plaster cast for 1 w, WB at 6 w	Not indicated		26 pts, Type II: 15 y(13-17);	16 Type II, 10 Type III

Koehler, 2003 <sup>20</sup>	Retrospective	spiked washer (screw removal within 6 m) Cannulated screw fixation (screw removal after 8–12 m)	Type III skeleton Type III skeleton Type III skeleton	Skeletal mature patient (4 cases) and other methods (15 pt)	Long-leg cast flexed 30° and touch-down W-B for 4 w	Not indicated	Rx, ROM, Lachman, ADS, Pivot-shift and Lysholm Rx, ROM, Lachman and Pivot-shift, IKDC, KT-1000, Lysholm, Tegner, and Marshall knee score	11/5; Type III; 17 y (16–18); 5/5 6 pts, 12.0 y (7.9–16.1); 4/2	6 Type III
Osti, 2000 <sup>35</sup>	Prospective	Reduction and fixation with metallic suture; removal after union	Type III	None	Partial W-B, hinged brace locked 0° for 1 month	0–30 days: CPM, isom. ex. stretchings; 30–60 d: full W-B; 60–90 d: swim and cycling; 120 d: return to sports	Rx at 6/8 w, ROM, Lachman, ADS, Pivot shift, KT-1000, quadriceps atrophy and swelling	10 pts, 26.7 y (17–41); 7/3	All Type III
May, 2011 <sup>24</sup>	Retrospective	Screws (15 pt:68%)/sutures (7 pt:32%) ARIF (18 pt:82%)/ORIF (4 pt:18%)	Type II and III, acute fractures	Ipsilat. lower limb fractures, multiligam. inj., non-op. treat.	Immobil. in brace for 5.5 w (72%) or cast for 4 w (28%)	ROM initiated immediately in 11 pts (50%) and beyond the second w in 11 pts (50%). W-B initially toe-touch or not WB in 19 patients (86%) and W-B as tolerated in 3 pts (14%).	Rx, ROM, Lachman, ADS, Pivot-shift, Biodex testing, Lysholm, IKDC and Tegner	22 pts, 17 y (7–39); 12/10 14 pt (64%) skelt imm	12 Type II (55%) and 10 Type III (45%)
Liljeros, 2009 <sup>36</sup>	Prospective	Bioabsorbable nails	Type II and III, skeleton immature patient, and	None	Cast in slight flex for 5 w and full W-B with crutches	FKT for 2 months	Rx, ROM, Lachman-KT-1000, Lysholm knee scoring scale and activity	13(16) pts: 11 y (7–15); 8/8; 3 pt no follow-up	2 Type II and 14 Type III

Continued

Table 1 Continued

Author	Study	Technique	Inclusion criteria	Exclusion criteria	Post-operative treatment	Rehabilitation	Post-operative evaluation	Patients, Age; M/F	Type of lesion
In Y, 2008 <sup>37</sup>	Prospective	Fixation of the fragment using bioabsorbable suture anchors	acute fractures (<72 h) None	None	Limited-motion brace in full-ext. and no W-B for 2 w	After 2 w ROM exercises and partial W-B, at 6 w brace removal	Rx, ROM, Lachman and Pivot-shift IKDC, and KT-2000	5 pts; 4 adults (28–48 y) 1 child (8 y); 4/1	2 Type II, 2 Type III and 1 Type IV
Abdelkafy, 2014 <sup>38</sup>	Prospective	FiberWire <sup>®</sup> or Orthocord <sup>®</sup> suture fixation	Type III, skeletally immature patients and fracture untreated for >6 w	Multiligamentous injury, chondral or osteochondral injury, skeletal maturity and Type I and II	Long-leg, hinged knee brace	Muscle contractions, straight-leg raises, passive ROM using a continuous passive motion (CPM) machine limited to 90° for one min and the gradually increased, toe-touch W-B with crutches immediately postoperatively. Progression to full W-B began 6 w after surgery.	Rx, IKDC, modified Lysholm knee score, VAS pain and patient satisfaction.	13 pts, 10 y (7–14); 9/4	Type III
Verdano, 2013 <sup>39</sup>	Prospective	Absorbable suture fixation	Type II, III and IV	None	Not indicated	Not indicated	Rx, Lysholm knee scoring and Marshall scoring system	21 pts, 28 y (9–60)	9 Type II, 8 Type III and 5 Type IV
Wiegand, 2013 <sup>40</sup>	Prospective	Herbert-screw fixation	Type II and III skeleton	None	Long plaster splint was applied in the position of a	Active and passive exercises 2–3 times a week	Rx, Lysholm functional scale, anterior drawer,	8 pts, 12.5 y; 6/2	3 Type II and 5 Type III

Kluemper, 2013 <sup>25</sup>	Retrospective	RCG device/suture or the RCG device/T-Fix (Acufex) methods	Type II, III and IV	inmature patient	20°flexion until wound healing	and partial W-B after 4 w. Full W-B after the 6 w.	Lachmann and Pivot shift	17 pts, 16.8 y (13–37 y); 16/1	15 (88%) Type III, 1 Type II fracture and 1 patient Type IV.	
Faivre, 2014 <sup>26</sup>	Retrospective	Tightrope fixation	Type II or III acute fractures	Type II or III acute fractures	Screw fixation, damage to the ACL exceeding 50% of substance, previous knee surgery and concomitant injuries	Brace locked in extension for weight bearing.	Physical therapy and quadriceps activation at 2 w, with flex limited to 90° for the first 6 w. Then full ROM and W-B with the brace. At 3 m (if anatomic fracture healing) brace was discontinued and return to sports at 4 m.	ROM, Lachman stability, varus/valgus stress test, pain, anterior and posterior drawer tests, resumption of preinjury activity levels and integrity of the ACL.	8 pts, 34.2 y (± 12.5); 2/6	5 Type II, 2 Type IIIa and 1 Type IIIb
Pan, 2012 <sup>27</sup>	Retrospective	Cannulated screws (SF) or Ethibond sutures (ES)	Type II, III and IV fractures and skeletally mature	Type II, III and IV fractures and skeletally mature	Tibial plateau fracture, nerve or vessel damage, multiligament injury or knee dislocation	Brace for 8 w	Knee motion exercises to prevent flexion deformity were started immediately without any limitation, W-B as tolerated.	R,x, post-operative knee laxity measured by Rolimeter® and IKDC scores, the knee mobility, and the Lachman test	48 pts: 2.5 SF (18–52 y); 4/11; 2.3 ES (17–50 y); 16/7	SF: 9 Type II, 15 Type III and 1 Type IV fracture. EF: 8 Type II, 14 Type III

Continued

Table 1 Continued

Author	Study	Technique	Inclusion criteria	Exclusion criteria	Post-operative treatment	Rehabilitation	Post-operative evaluation	Patients, Age; M/F	Type of lesion
Ochiai, 2011 <sup>41</sup>	Prospective	Meniscal Viper Repair System (Arthrex, Naples and FL)	Type II, III and IV fractures	None	Cast for 2 w.	Brace and ROM training from 2 w. Partial W-B from 5 and full W-B from 8 w after surgery	Rx, ROM, side-to-side differences measured by Telos SE and Lysholm scores	5 pts, 28.8 y (7–55); 4/1	1 Type II, 3 Type III and 1 Type IV
Tudisco, 2010 <sup>28</sup>	Retrospective	Conservative management (4 Type I, 2 Type II and 1 Type III), ORIF(1 Type III) and ARIF with suture (1 Type II and 5 Type III)	Type I, II, III and IV fractures	None	Long-leg brace for 6 w unlocked for 6–10 h a day for 3 w	Physical therapy with flex limited to 90° for the first 2 w. Full ROM by 6 w.	Rx, pain, ROM, clinical test, KT-1000 and IKDC	14 pts, 12.3 y (7–16); 12/2	4 Type I, 3 Type II and 7 Type III
Mathews, 1994 <sup>42</sup>	Prospective	Suture fixation and 1 conservative management (Type II)	Type II and III	None	Knee immobilizer for 3 w in full extension	ROM, quadriceps strengthening started at 3 w and W-B at 6 w	Rx, ROM, lachman and pivot shift test	6 pts, 24 (16–36); 5/1	5 Type III and 1 Type II
Wagih, 2015 <sup>29</sup>	Retrospective	Transosseous suture	Type III	None	Extension for 4–6 w	Partial W-B for the first 2–4 w with ROM exercises	Rx, ROM, lachman test and IKDC	11 pts, 8 (6–11); 8/3	Type III



and active hamstring flexion exercises. Active open chain quadriceps contractions are not allowed for 6 w. Full W-B at 4-6 w.

Author, Year	Study Design	Sample Size	Fracture Type	Management	Follow-up	Outcomes
Edmonds, 2014 <sup>30</sup>	Retrospective	Suture fixation: ARIF 28 pts ORIF 29 pts Conservative management 19 pts (CM)	Type II and III	Type I and no post-operative Xray	Immobilization in brace: ARIF: 5.1 w ORIF: 4.4 w CM: 5.4 w	Not indicated Rx, Pain, Lysholm score and treatment satisfaction 76 pts, ARIF: 12.4 ± 2.7; 12.4 ± 2.7; 64%/36% ORIF: 12.2 ± 3.7; 83%/17% CM: 12.4 ± 4.7; 79%/21%
Watts, 2015 <sup>31</sup>	Retrospective	ARIF: 18 pts (suture: 9, screw: 8 and both: 1) ORIF: 13 pts (suture: 2, screw: 9 and both: 2)	Type II and III	None	Immobilization: ARIF: 16.6d (2-36) ORIF: 21.8d (7-44)	Not indicated Type II: ARIF: 13, ORIF: 9 Type III: ARIF: 5, ORIF: 4
Memisoglu, 2015 <sup>32</sup>	Retrospective	Intra-articular button	Not indicated	Not indicated	Brace (0°-30°) for 3 w and increased 10°-20° per week. Full weightbearing with a locking knee brace in 0° extension.	Patellar mobilizations, quadriceps isometric strengthening exercises and ROM exercises using a CPM machine Rx, objective and subjective IKDC score, Lysholm knee score, KT-1000 arthrometer, ROM, Anterior drawer, Lachman and pivot-shift tests 11 pts, 12.2 (10-16); 11/0 9 Type IIIA, 1 Type IIIB, 1 Type IV

**Table 2** Outcomes and complications

Author	Results		RX	SCORE	Follow-up	Complications
	ROM	TEST				
Sommerfeldt, 2008 <sup>21</sup>	Normal (100%)	Lachmann+ in 3 pts without subjective instability	Slight dislocation without impingement	Not indicated	12 m	10 converted in mini-arthrotomy (6 Type IV)
Wouters, 2011 <sup>33</sup>	Normal (100%) at 9 w	Mild laxity in 2 pts: KT-1000 < = 3 mm (diff. both sides)	100% union	Not indicated	4 y(3–10)	1 refracture: retreated and healed
Ahn, 2005 <sup>22</sup>	Normal (100%)	13pts (Lachman-, ADS- and KT-2000 < 3 mm), 1 pt F (Lachman and ADS 2+, KT-2000 5 mm)	Acute cases: union 10.8 w (8–12) and nonunion 15 w (12–16)	LKS 95.6 (92–100), HSS 96.4 (91–100); no preop (pre-operative)	51 m (30–80); acute 53 m	Limb leg discrepancy 1 cm (affected longer) in 2 pts
Huang, 2008 <sup>7</sup>	16 pts (44,4%) normal ROM; 2 pts (5.5%) abnormal flex (16–25°) (1 Type I and 1 Type IV)	Lachman and ADS -(100%), KT-1000 <3 mm (100%)	100% union after 3 m, 2 pts (10%) Stage I degen. sec. Ahlback	LKS: preop 38, postop 98. TEL: preop 3 postop 7.3. IKDC: preop light to sedentary activity level, postop 94,5% strenuous-to-moderate activity level (= preinjury level).	34.4 m (24–91)	None
Vega, 2008 <sup>34</sup>	4 normal, 3 nearly n.	KT-1000 2 mm(1–3); Lachman and ADS and Pivot shift – (100%)	100% union	Lysholm: preop 29 postop 94 IKDC: post 92 (86–98)	6–24 m	Not reported
Reynders, 2002 <sup>23</sup>	22 normal, 4 ext nearly n.	Type II: 3 pt no laxity, 13 pt Lach. + without giving way; Type III: 100% ADS + in 4 pt, +++ in 4 pt, +++ in 2 pt.	4 pts with Type III: improper reduction	Lysholm: Type II 95.25 and Type III 89.70	2–8 y	Ledging (shelf-like projection of bone due to improper reduction) in 4 pts (1 second-look for impingement) and ACL insufficiency in 2 pts with Type III

Kocher, 2003 <sup>20</sup>	Normal (100%)	Lachman: 1 pt normal, 3 nearly normal, 2 abnormal Pivot-shift: 4 normal, 2 n. normal. KT-1000 >3 mm in 4/6 pts.	No malunion	Lysholm: 99.5 (98–100) Marshall: 49.0 (47–50) Tegner: 8.7 (7–9)	3.2 y (2–6.3)	Not noted
Osti, 2000 <sup>35</sup>	Full ext. /flex. 12.5–13.5°	Lachman and Pivot-shift —and KT-1000<3 mm (80%), Lachman + and KT-1000>3 mm (20%)	100% union after 6–8 w	No patients complain residual pain/instability	1 year (13–74 m)	Recurrent swelling after sport in 1 pt
May, 2011 <sup>24</sup>	Mean knee extension: -1° (-7°/-10°) and mean knee flexion: 133° (90°/150°)	Lachman- (80%), 1+ (15%) and 2+ (5%). All + had Type III.	17 pts (72%) 100% union; 5 pts (28%) gap 2–5 mm (2 ARIF + suture, 2 ARIF + screw, and 1 ORIF + screw)	LKS: pre 43 post 93 IKDC: pre 45 post 91 Tegner: preop 6.6 postop 6.4. Age has negative impact on LKS (-7 x ogni decade increase), IKDC (-7) and Tegner (-1)	7 y (2–15)	6 pts (27%): 4 pts (57%) screw fixation required symptomatic hardware removal. 2 pts (13%) with suture fixation: 1 manipulation and 1 arthroscopic scar tissue debridement.
Liljeros, 2009 <sup>36</sup>	3 pts 5–10° flex. def.; 4 pts 5° ext.def.	1 pt con KT-1000 = 3 mm, 100% normal at single-leg hop test, and 1 pt abnormal side-hop test	100% union (3 pts 2 mm frag. elevation)	Lysholm score: 11 pts excellent, 1 pt good and 1 pt poor.	3, 9 y (2–5)	1 conversion to OPEN for technical problems
In Y, 2008 <sup>37</sup>	Full ROM	Lachmann & Pivot-shift -, KT-2000 <3 mm	100% union	IKDC: normal in 2 pts, nearly normal in 3 pts.	1 y	None
Abdelkafy, 2014 <sup>38</sup>	Full ROM	11 pts Lachman, anterior drawer and pivot shift tests -, 2 pts Lachman test +, anterior drawer and pivot shift tests -, All pts return to their preinjury level of activity and recreational sports	Few mm of superior displacement of the anterior end of the fracture fragment	IKDC: 12 A and 1 B Lysholm score: 91.2 Subjective IKDC: 80.5 VAS pain: 0.4 VAS operation satisfaction: 9.6	10.8 m (SD 6.8; 4–24)	One case of superficial wound infection (successfully treated with antibiotics)

Continued

Table 2 Continued

Author	Results	TEST	RX	SCORE	Follow-up	Complications
Verdano, 2013 <sup>39</sup>	Not indicated	Not indicated	100% union at 8 w (6–10)	Lysholm knee score: 60% good results and 40% very good results Marshall scoring system: 20% good results and 80% very good results	24 m (12–33)	None
Wiegand, 2013 <sup>40</sup>	Full ROM	No instability in any pts. Lachman and anterior drawer + in one case	100% union	Lysholm functional scale: 94.97 in Type II and 94.20 in Type III	1 y	Incipient arthritis 5 years after primary treatment.
Kluemper, 2013 <sup>25</sup>	2 pts lost 3° of ext, and 1 pt lost more than 10° of flex (On average lost 5.5°)	All pts Lachman-, good stability, anterior and posterior drawer tests, varus/valgus stress test, and resumed their prep level of activity	100% union	9 (53%) pts no pain and 8 pts mild intermittent pain associated with strenuous activity.	25.3 m (2 m–13 y)	None
Faivre, 2014 <sup>26</sup>	3 pts severe difficulties regaining motion	One significant anterior laxity with a side-to-side Rolimeter difference of 4 mm and Lachman test+,	100% union	3 pts IKDC A, 2 B, 1 C and 1 D	10 m	3 pts motion complications and 2 required an arthroscopic arthrolysis.
Pan, 2012 <sup>27</sup>	Extension deficit > 2° in 3 SF (12%) and in 6 ES (27%). Flexion deficit > 5° in 2 SF (8%) and in 5 ES (22%).	KT-1000 side-to-side difference > 5 mm in 2 pts (8%) in SF group and in 3 pts (13%) in the ES group. SF: 2 (8%) pt pivot shift + and 2 (8%) 2 pivot shift ++.	100% union	SF group: Lysholm: 95, IKDC subjective: 93, Tegner activity: 8, and IKDC objective evaluation (%): 23 A (92%), 2 B (8%), and C0 (0%) ES group: Lysholm: 90, IKDC subjective: 90, Tegner activity: 7, and	SF: 58 m (24–100) ES: 47 m (24–93)	One joint stiffness approximately 3 months after surgery (EF group)

Ochiai, 2011 <sup>41</sup>	ROM side-to-side difference(°): ext: 2.0 (0-8) and flx: 0.8 (0-4)	ES: 5 (22%) pivot shift +, 3 (13%) pivot shift ++ and 1 (9%) pivot shift +++ Telos SE/the side-to-side difference (mm): 3.6 (2.4-3.9)	100% union	IKDC objective evaluation (%): 16 A (70%), 4B (17%), and 3 C (13%) Lysholm score: 90.7 (90-100)	16 m (8-24)	None
Tudisco, 2010 <sup>28</sup>	Complete	13 pt: returned to the same sport activity level 4 pt: Lachman + and KT- 1000 difference >5 mm but not subjective instability	Good reduction in five cases and sufficient in two cases	Seven treated nonoperatively: normal results in six cases and abnormal in one (Type III). ORIF: nearly normal results ARIF: 2 normal (1 Type II e 1 Type III) and 4 nearly normal (Type III)	29 y (12-42) end of skeletal growt (mean age: 41 y)	Degenerative arthrosis in 2 pts
Matthews, 1994 <sup>42</sup>	2-135° (range 0-140°)	No instability in any of the pts. Lachman and pivot shift -	100% union	None	1 y	None
Wagih, 2015 <sup>29</sup>	1 pt: 5° extension deficit	1 pt: Lachman 1+	100% union	IKDC: 9A and 2 B	16.3 (11-21) m	None
Edmonds, 2014 <sup>30</sup>	Not indicated	Not indicated	100% union	Pain: ARIF: 0.2, ORIF: 0.7 and C.m.: 2.7 Lysholm: ARIF: 95, ORIF: 97.4 and CM: 86 Treatment satisfaction: ARIF: 9.6, ORIF: 9.9 and CM: 9	5 ARIF: 5.6 ± 2 y 7 ORIF: 6.8 ± 2 y	Arthrofibrosis: ARIF:12% and ORIF: 11.1% CM: 16.7% subsequent operation

Continued

Table 2 Continued

Author	Results	TEST	RX	SCORE	Follow-up	Complications
Watts, 2015 <sup>31</sup>	Not indicated	None	Not indicated	Not indicated	ARIF: 13.9 ± 10.5 m ORIF: 12.7 ± 14.3 m	Arthrofibrosis: ARIF: 7 pts (38.9%) and ORIF: 1 pt (14.3%)
Memisoglu, 2015 <sup>32</sup>	Active extension: -1.8° ± 3.4 (-10° to 0°) Active flexion: 135.5° ± 6.1° (125°–145°)	Anterior drawer, Lachman and pivot-shift tests -	100% union	Lysholm score: 95.7 ± 6.6 (84–100) IKDC subjective score: 94.3 (85–100). Global IKDC scores: 7 normal (A) and 4 nearly normal (B)	69 m (60–84)	None

## Study population

The total number of patients was 384 (235 males and 142 females). Two studies<sup>21,39</sup> did not report gender. Fifteen studies<sup>20,21,23–25,28–34,36,38,40</sup> had an average age of less than 18 years (skeletally immature patients) while 9 studies<sup>7,22,26,27,35,37,39,41,42</sup> reported data about adult patients.

Using Meyers and McKeever classification, 104 Type II, 202 Type III and 31 Type IV lesions were reported. One study<sup>33</sup> did not describe the types of lesion.

## Clinical outcomes

The clinical results overall were excellent. Regarding ROM, 263 patients achieved complete ROM (100%), and 7 patients achieved a nearly normal ROM.<sup>23,34</sup> Eighteen patients exhibited a flexion deficit (5–10°),<sup>7,25,27,36,41</sup> and an extension deficit was found in 21 patients.<sup>25,27,29,36,41</sup> Three patients had severe difficulties regaining complete ROM.<sup>26</sup>

Clinical evaluation was based on the Lachman test, pivot shift test and anterior drawer sign (ADS), in some studies the KT-1000 or similar was used. A Lachman + was found in 36 patients,<sup>20–24,26,28,29,33,35,36,38,40</sup> a Lachman 2+ in 3 patients.<sup>20,24</sup> Anterior knee laxity measured with ADS and KT-1000 was found in 31 patients.<sup>20,22,23,26–28,33,35,36,40</sup> Pivot shift test when used as a rotational instability test was found + in 4 patients.<sup>20,27</sup> Details from the included articles are provided in Table 2.

## Radiographic evaluation

In 16 publications<sup>7,24–27,29,30,32–35,37,39–42</sup> there was a 100% bone union, an acceptable reduction was achieved in two patients (2/7) treated with ARIF in one study,<sup>28</sup> and a mild superior displacement of the anterior end of the fracture fragment was found in patients treated with FiberWire® or Orthocord® suture fixation<sup>38</sup> and in three (3/16) patients treated with bioabsorbable nails.<sup>36</sup> In four patients with a Type III lesion treated with cannulated screw an improper reduction was achieved.<sup>23</sup> One study used Kirschner wires or cannulated

screws; it evidenced a slight dislocation without impingement<sup>21</sup> in five patients (28%) treated with different techniques, and a 2–5 mm gap.<sup>24</sup>

## Complications

Different complications occurred: 1 patient refractured,<sup>33</sup> a limb leg discrepancy of 1 cm (with the affected leg longer) was reported in 2 patients,<sup>22</sup> ledging (shelf-like projection of bone due to improper reduction) in 4 patients,<sup>23</sup> partial ACL lesion in 3 patients, recurrent swelling after sport in 1 patients,<sup>35</sup> and arthrofibrosis in 19 patients.<sup>24,26,29,30</sup> In one patient, conversion to open surgery was necessary for technical problem<sup>36</sup>; there was one case of superficial wound infection,<sup>38</sup> an incipient arthritis 5 years after primary treatment,<sup>40</sup> one joint stiffness at 3 months after surgery,<sup>27</sup> and degenerative arthrosis in two patients.<sup>28</sup>

## Discussion

Surgical treatment is indicated for Type II fractures, when attempt at the reduction has failed, and for Type III and IV fractures.<sup>8,9,22–24,33,34,37</sup>

Different surgical options have been proposed, including open reduction and internal fixation (ORIF),<sup>14,17,43</sup> arthroscopic reduction and immobilization, and ARIF.<sup>8,9,22–24,33,34,37</sup> Open surgical techniques have several disadvantages and more complications, including soft-tissue damage during arthrotomy, higher postoperative pain causing delay in physical therapy and a longer hospital stay. On the other hand, arthroscopic techniques are considered the gold standard for these lesions since they allow to better visualize intra-articular injuries, simplify the diagnosis, reduce accurately the fracture, remove loose fragments and manage associated soft-tissue injuries.<sup>9,19,20</sup> Among associated injuries, tears to the anterior root of both menisci and interstitial tears of the ACL may frequently occur.<sup>9,19,20</sup> Meniscal tears may be repaired arthroscopically after reduction and fixation of the fracture; the interstitial tears of the ACL may not be diagnosed and, after surgery, cause ACL laxity,

which is often not relevant from a clinical view point.<sup>9,19,20</sup>

Arthroscopic management consists first in the debridement of the bony bed of the avulsion fragment and the removal of the soft tissue interposed, which might prevent anatomical reduction. Each part of meniscus or intermeniscal ligament entrapped in the fracture site must be carefully removed without damaging these structures or altering their function.<sup>44</sup>

Methods of arthroscopic fixation of these fractures include Kirschner wires,<sup>21,44</sup> staples,<sup>45</sup> absorbable nails,<sup>33,36</sup> metallic screws,<sup>21,23,45</sup> fixation with non-absorbable sutures<sup>1,9,22,24,46</sup> or metallic wire,<sup>35</sup> reinsertion of the fragment with a metallic<sup>34</sup> or absorbable<sup>37</sup> anchor-screw. Screws and suture fixation are currently the most used and reliable surgical techniques reported in the literature.<sup>1,9,21–24,45,46</sup>

Fracture fixation can be achieved with either antegrade or retrograde screw insertion. Cannulated screws are often used to optimize the entry point of the screw in the fragment and to insert it in a more accurate direction. Antegrade screw insertion is performed inserting an aiming guide through the superior anteromedial portal and the direction of the screw is from superoanterior to inferoposterior, keeping the knee at 90 degrees of flexion. In the retrograde fashion, the screw is inserted from the anterior cortex of the proximal tibia through the tibial eminence fracture.<sup>47</sup>

The screw technique is therefore simple and reproducible, allows early mobilization and weight-bearing, but has some contraindications and disadvantages. Removal of the screw can be necessary in case of persistent discomfort at the site of fixation after fracture healing. Thus, some authors reported good results and high patients satisfaction with this further procedure. Nevertheless, incorrect position of the screw can also cause impingement and cartilage damage.<sup>48</sup> Growth disturbance and leg-length discrepancy might occur in patients with open physis, but the screw can be inserted with a physeal-sparing technique providing excellent radiographic and clinical outcomes.<sup>3</sup> Screw fixation is contraindicated in case of small size or comminution of the fragment, and thus its insertion can lead to further displacement.<sup>5,12,22</sup>

Different devices, such as Tightrope,<sup>26</sup> meniscal viper repair system,<sup>41</sup> RCG,<sup>25</sup> Meniscus arrows or ACL-aiming device<sup>33</sup> or simple sutures, can be used to achieve the same clinical and radiographic results. One of the advantages of these techniques is the possibility to use it to treat fractures with small or comminuted fragments, providing a stable fixation with no need for further intervention to remove those devices. On the other hand, the passage of the bone tunnels through growth plates could cause bone growth disorders.<sup>13</sup> Matthews and Geissler<sup>42</sup> developed a technique of arthroscopic reduction and fixation using sutures with multiple PDS wires in five patients with tibial eminence fractures. No patients complained of subjective instability at 1 year, and only one patient had a deficit of 2° to full extension at latest follow-up.

Huang *et al.*<sup>7</sup> reported 36 patients (average age: 37, range 17–73) with Type II, III and IV fractures treated with multiple sutures and pull-out (No. 5 Ethibond wires). This method provided good functional results (LKS, Tegner Activity Level, IKDC): only one patient had residual pain during moderate-intense exercise, and two patients (one Type III and one Type IV) showed a significant flexion deficit of 16–25°.

Ahn and Yoo<sup>22</sup> used a similar technique of fixation with multiple sutures and pull-out (No. 0 PDS) to treat 10 acute fractures (Type III and IV) and 4 non-unions, reporting excellent functional results with fracture healing after a mean of 12.3 months and full ROM in all patients, and only one patient with laxity at Lachman and drawer tests and instrumental tests (KT-2000 arthrometer >5 mm of difference with contralateral knee) without subjective instability. The authors reported two patients who experienced growth disturbance with the affected limb 1 cm longer than the contralateral, and a genu recurvatum in one of the two patients; they suggest, in patients with open growth plates, to use alternative methods or to prevent the passage of tunnels for the pull-out through the anterior side of cartilage growth.

Osti *et al.*<sup>35</sup> reported a series of 10 adult patients (mean age 26.7 years) with a Type III fracture treated arthroscopically with metallic suture removed

after complete fragment union: all patients showed radiographic healing in 6–8 weeks with full ROM and stability (two patients had a KT-1000 > 3 mm, without symptomatic instability).

Using absorbable suture fixation, Verdano *et al.*<sup>39</sup> also showed good and very good results in 21 patients with complete union of the avulsed fragment at 2 years of follow-up without complications and similar results were reported by Pan *et al.*<sup>27</sup> However, ARIF with sutures requires a longer immobilization and partial weight-bearing, resulting in a higher risk of joint stiffness and arthrofibrosis.<sup>35</sup>

## Conclusions

Arthroscopy provides a less invasive method to approach these lesions, reducing the risks related to open technique such as soft-tissue damage, post-operative pain, infection and longer period of hospital stay. Furthermore, arthroscopic reduction and suture fixation do not require further surgery to remove fixation devices, but longer period of immobilization and partial weight-bearing. Nevertheless, clinical and radiographic results do not differ in relation to the chosen method of fixation. We suggest that the choice of the fixation technique should rely mainly on the experience of the surgeon.

## Conflict of Interest statement

The authors have no potential conflicts of interest.

## References

1. Kendall NS, Hsu SY, Chan KM. Fracture of the tibial spine in adults and children. A review of 31 cases. *J Bone Joint Surg Br* 1992;74:848–52.
2. Andersen JW, Mejdahl S. Bilateral fracture of the tibial spine. *Acta Orthop Belg* 1993;59:394–7.
3. Kocher MS, Micheli LJ. The pediatric knee: Evaluation and treatment. In: Insall JN, Scott WN (eds). *Surgery of the Knee*, 3rd ed. New York: Churchill-Livingstone, 2001, 1356–97.
4. Reynders P, Reynders K, Broos P. Pediatric and adolescent tibial eminence fractures: arthroscopic cannulated screw fixation. *J Trauma* 2002;53:49–54.
5. Woo SL, Hollis JM, Adams DJ, et al. Tensile properties of the human femur-anterior cruciate ligament-tibia



- complex. The effects of specimen age and orientation. *Am J Sports Med* 1991;19:217–25.
6. Rockwood CA, Green DP. *Fractures in Adults*. Philadelphia, etc: JB Lippincott Co, 1984.
  7. Huang TW, Hsu KY, Cheng CY, et al. Arthroscopic suture fixation of tibial eminence avulsion fractures. *Arthroscopy* 2008;24:1232–8.
  8. Shelbourne KD, Urch SE, Freeman H. Outcomes after arthroscopic excision of the bony prominence in the treatment of tibial spine avulsion fractures. *Arthroscopy* 2011;27:784–91.
  9. Vargas B, Lutz N, Dutoit M, Zambelli PY. Nonunion after fracture of the anterior tibial spine: case report and review of the literature. *J Pediatr Orthop B* 2009;18:90–2.
  10. Liljedahl S-O, Lindvall N, Wetterfors J. Early diagnosis and treatment of acute ruptures of the anterior cruciate ligament: a clinical and arthrographic study of forty-eight cases. *J Bone Joint Surg [Am]* 1965;47-A:1503–13.
  11. Falstie-Jensen S, Sondergard Petersen PE. Incarceration of the meniscus in fractures of the intercondylar eminence of the tibia in children. *Injury* 1984;15:236–8.
  12. Meyers MH, McKeever FM. Fracture of the intercondylar eminence of the tibia. *J Bone Joint Surg Am* 1959;41:209–22.
  13. Zaricznyj B. Avulsion fracture of the tibial eminence: treatment by open reduction and pinning. *J Bone Joint Surg Am* 1977;59:1111–4.
  14. Kocher MS. Lesioni intra-articolari del ginocchio. Rockwood e Wilkins – Traumatologia Pediatrica. In: Beaty JH, Kasser JR (eds). 6° Edizione Verduci Editore. Vol. 2. 2008, 987–97.
  15. Meyers MH, McKeever FM. Follow-up notes: fracture of the intercondylar eminence of the tibia. *J Bone Joint Surg Am* 1970;52:1677–83.
  16. Bakalim G, Wilppula E. Closed treatment of fracture of the tibial spines. *Injury* 1973;5:210–212.
  17. Molander ML, Wallin G, Wikstad I. Fracture of the intercondylar eminence of the tibia: a review of 35 patients. *J Bone Joint Surg Br* 1981;63-B:89–91.
  18. Bakalim G, Wilppula E. Closed treatment of fracture of the tibial spines. *Injury* 1974;5:210–2.
  19. Lubowitz JH, Elson WS, Guttmann D. Part II: Arthroscopic treatment of tibial plateau fractures. *Arthroscopy* 2005;21: 86–92.
  20. Kocher MS, Foreman ES, Micheli LJ. Laxity and functional outcome after arthroscopic reduction and internal fixation of displaced tibial spine fractures in children. *Arthroscopy* 2003;19:1085–90.
  21. Sommerfeldt DW. Arthroscopically assisted internal fixation of avulsion fractures of the anterior cruciate ligament during childhood and adolescence. *Oper Orthop Traumatol* 2008;20:310–20.
  22. Ahn JH, Yoo JC. Clinical outcome of arthroscopic reduction and suture for displaced acute and chronic tibial spine fractures. *Knee Surg Sports Traumatol Arthrosc* 2005;13:116–21.
  23. Reynders P, Reynders K, Broos P. Pediatric and adolescent tibial eminence fractures: arthroscopic cannulated screw fixation. *J Trauma* 2002;53:49–54.
  24. May JH, Levy BA, Guse D, et al. ACL tibial spine avulsion: mid-term outcomes and rehabilitation. *Orthopedics* 2011;34:89.
  25. Kluemper CT, Snyder GM, Coats AC, et al. Arthroscopic suture fixation of tibial eminence fractures. *Orthopedics* 2013;36:e1401–6.
  26. Faivre B, Benea H, Klouche S, et al. An original arthroscopic fixation of adult's tibial eminence fractures using the Tightrope® device: a report of 8 cases and review of literature. *Knee* 2014;21:833–9.
  27. Pan RY, Yang JJ, Chang JH, et al. Clinical outcome of arthroscopic fixation of anterior tibial eminence avulsion fractures in skeletally mature patients: a comparison of suture and screw fixation technique. *J Trauma Acute Care Surg* 2012;72:E88–93.
  28. Tudisco C, Giovarruscio R, Febo A, et al. Intercondylar eminence avulsion fracture in children: long-term follow-up of 14 cases at the end of skeletal growth. *J Pediatr Orthop B* 2010;19:403–8.
  29. Wagih AM. Arthroscopic treatment of avulsed tibial spine fractures using a transosseous sutures technique. *Acta Orthop Belg* 2015;81:141–6.
  30. Edmonds EW, Fornari ED, Dashe J, et al. Results of displaced pediatric tibial spine fractures: a comparison between open, arthroscopic, and closed management. *J Pediatr Orthop* 2015;35:651–6.
  31. Watts CD, Larson AN, Milbrandt TA. Open versus arthroscopic reduction for tibial eminence fracture fixation in children. *J Pediatr Orthop* 2015. [Epub ahead of print]
  32. Memisoglu K, Muezzinoglu US, Atmaca H, et al. Arthroscopic fixation with intra-articular button for tibial intercondylar eminence fractures in skeletally immature patients. *J Pediatr Orthop B* 2016;25:31–6.
  33. Wouters DB, de Graaf JS, Hemmer PH, et al. The arthroscopic treatment of displaced tibial spine fractures in children and adolescents using Meniscus Arrows. *Knee Surg Sports Traumatol Arthrosc* 2011;19:736–9.
  34. Vega JR, Irribarra LA, Baar AK, et al. Arthroscopic fixation of displaced tibial eminence fractures: a new growth plate-sparing method. *Arthroscopy* 2008;24: 1239–43.

35. Osti L, Merlo F, Liu H, Bocchi L. A Simple modified arthroscopic procedure for fixation of displaced tibial eminence fractures. *Arthroscopy* 2000;16:379–82.
36. Liljeros K RPT, Werner S RPT, Janarv P-M. Arthroscopic fixation of anterior tibial spine fractures with bioabsorbable nails in skeletally immature patients. *Am J Sports Med* 2009;37:923–8.
37. In Y, Kim JM, Woo YK, et al. Arthroscopic fixation of anterior cruciate ligament tibial avulsion fractures using bioabsorbable suture anchors. *Knee Surg Sports Traumatol Arthrosc* 2008;16:286–9.
38. Abdelkafy A, Said HG. Neglected ununited tibial eminence fractures in the skeletally immature: arthroscopic management. *Int Orthop* 2014.
39. Verdano MA, Pellegrini A, Lunini E, et al. Arthroscopic absorbable suture fixation for tibial spine fractures. *Arthrosc Tech*. 2013;3:e45–8.
40. Wiegand N, Naumov I, Vámhidy L, Nöt LG. Arthroscopic treatment of tibial spine fracture in children with a cannulated Herbert screw. *Knee* 2014;21:481–5.
41. Ochiai S, Hagino T, Watanabe Y, et al. One strategy for arthroscopic suture fixation of tibial intercondylar eminence fractures using the Meniscal Viper Repair System. *Sports Med Arthrosc Rehabil Ther Technol*. 2011;3:17.
42. Matthews DE, Geissler WB. Arthroscopic suture fixation of displaced tibial eminence fractures. *Arthroscopy* 1994;10:418–23.
43. Oostvogel HJ, Klasen HJ, Reddingius RE. Fractures of the intercondylar eminence in children and adolescents. *Arch Orthop Trauma Surg* 1988;107:242–7.
44. Lowe J, Chaimsky G, Freedman A, et al. The anatomy of tibial eminence fractures: Arthroscopic observations following failed closed reduction. *J Bone Joint Surg Am* 2002; 84:1933–38.
45. Kobayashi S, Terayama K. Arthroscopic reduction and fixation of a completely displaced fracture of the intercondylar eminence of the tibia. *Arthroscopy* 1994;10:231–35.
46. Lehman RA Jr, Murphy KP, Machen MS, Kuklo TR. Modified arthroscopic suture fixation of a displaced tibial eminence fracture. *Arthroscopy* 2003;19:E6.
47. Ando T, Nishihara K. Arthroscopic internal fixation of fractures of the intercondylar eminence of the tibia. *Arthroscopy* 2003; 19:54–61.
48. Senekovic V, Veselko M. Anterograde arthroscopic fixation of avulsion fractures of the tibial eminence with a cannulated screw: five-year results. *Arthroscopy* 2003; 19:54–61.