

STATE-OF-THE-ART REVIEW

Screening for Transthyretin Amyloid Cardiomyopathy in Everyday Practice



Ronald M. Witteles, MD,^a Sabahat Bokhari, MD,^b Thibaud Damy, MD, PhD,^c Perry M. Elliott, MBBS, MD,^d Rodney H. Falk, MD,^e Nowell M. Fine, MD, SM,^f Mariana Gospodinova, MD,^g Laura Obici, MD,^h Claudio Rapezzi, MD,ⁱ Pablo Garcia-Pavia, MD, PhD^{j,k}

HIGHLIGHTS

- ATTR-CM is a life-threatening, progressive disease that is often underdiagnosed and misdiagnosed.
- Certain clinical scenarios have been identified that now warrant screening for ATTR-CM.
- Once ATTR-CM is suspected, a definitive diagnosis can usually be achieved noninvasively.
- Accurate, early diagnosis of ATTR-CM is key to enabling appropriate patient care.

ABSTRACT

Transthyretin amyloid cardiomyopathy (ATTR-CM) is a life-threatening, progressive, infiltrative disease caused by the deposition of transthyretin amyloid fibrils in the heart, and can often be overlooked as a common cause of heart failure. Delayed diagnosis due to lack of disease awareness and misdiagnosis results in a poorer prognosis. Early accurate diagnosis is therefore key to improving patient outcomes, particularly in the context of both the recent approval of tafamidis in some countries (including the United States) for the treatment of ATTR-CM, and of other promising therapies under development. With the availability of scintigraphy as an inexpensive, noninvasive diagnostic tool, the rationale to screen for ATTR-CM in high-risk populations of patients is increasingly warranted. Here the authors propose a framework of clinical scenarios in which screening for ATTR-CM is recommended, as well as diagnostic “red flags” that can assist in its diagnosis among the wider population of patients with heart failure. (J Am Coll Cardiol HF 2019;7:709–16) © 2019 The Authors. Published by Elsevier on behalf of the American College of Cardiology Foundation. This is an open access article under the CC BY-NC-ND license (<http://creativecommons.org/licenses/by-nc-nd/4.0/>).

From the ^aStanford Amyloid Center, Division of Cardiovascular Medicine, Stanford University School of Medicine, Stanford, California; ^bColumbia University Medical Center & New York Presbyterian Hospital, College of Physicians and Surgeons, Columbia University, New York, New York; ^cDepartment of Cardiology, Centre Hospitalier Universitaire Henri Mondor, Créteil, France; ^dThe Inherited Cardiac Diseases Unit, Bart’s Heart Centre, St. Bartholomew’s Hospital & UCL Centre for Heart Muscle Disease, Institute of Cardiovascular Science, University College London, London, United Kingdom; ^eDivision of Cardiovascular Medicine, Brigham and Women’s Hospital, Boston, Massachusetts; ^fLibin Cardiovascular Institute of Alberta, University of Calgary, Calgary, Alberta, Canada; ^gIntensive Care Unit, Clinic of Cardiology, Medical Institute, Ministry of Interior, Sofia, Bulgaria; ^hAmyloidosis Research and Treatment Centre, Fondazione IRCCS Policlinico San Matteo, Pavia, Italy; ⁱDepartment of Experimental, Diagnostic and Specialty Medicine, University of Bologna, Bologna, Italy; ^jHeart Failure and Inherited Cardiac Diseases Unit, Department of Cardiology, Hospital Universitario Puerta de Hierro Majadahonda, CIBERCV, Madrid, Spain; and the ^kUniversity Francisco de Vitoria (UFV), Pozuelo de Alarcón, Madrid, Spain. Dr. Witteles has received grants from Pfizer, Alnylam, and Eidos; and has received personal fees from Pfizer and Alnylam. Dr. Bokhari has received personal fees from Pfizer. Dr. Damy has received grants from Pfizer and Akcea; and has received personal fees from Pfizer, Alnylam, Ionis, Akcea, Prothena, and Neurimmune. Dr. Elliott has received grants from Pfizer; and has received personal fees from Pfizer and Alnylam. Dr. Falk has received personal fees from Alnylam, Ionis, Pfizer, Akcea, and Caelum. Dr. Fine has received grants and personal fees from Pfizer, Alnylam, and Akcea.

**ABBREVIATIONS
AND ACRONYMS****AL** = light-chain amyloidosis**ATTR-CM** = transthyretin amyloid cardiomyopathy**ATTRm** = hereditary transthyretin amyloidosis**ATTRwt** = wild-type transthyretin amyloidosis**CMR** = cardiac magnetic resonance**EKG** = electrocardiogram**HFpEF** = heart failure with preserved ejection fraction**Tc** = technetium**TTR** = transthyretin protein**TTR** = transthyretin gene

Transthyretin amyloid cardiomyopathy (ATTR-CM) represents 1 of the 2 most common types of cardiac amyloidosis, an infiltrative heart muscle disease caused by extracellular deposition of misfolded proteins which form insoluble amyloid fibrils (1,2). ATTR-CM is a life-threatening, progressive disease that can affect the heart in isolation or as part of a systemic disorder (2-4). The other main type of cardiac amyloidosis is light-chain (AL) amyloidosis, which arises from overproduction and misfolding of monoclonal immunoglobulin light chains (2). AL amyloidosis is a relatively rare disease, characterized by a rapidly progressive clinical course which, if untreated, has a median survival of <6 months (5).

ATTR-CM is caused by deposition of transthyretin (TTR), a plasma protein predominantly produced in the liver, which is responsible for transporting thyroxine and retinol (1,6). TTR mainly exists in a tetrameric state, but destabilizing mutations in the transthyretin gene (*TTR*) and/or aging promote its proteolytic remodeling and dissociation into monomers which subsequently misfold and aggregate to form amyloid fibrils that deposit in tissues (1,2,4,6). In the case of ATTR-CM, amyloid fibrils mainly deposit in the interstitial space of the myocardium leading to increased wall thickness and diastolic dysfunction that can result in heart failure (HF) and arrhythmias (2).

ATTR-CM exists as 1 of 2 subtypes, defined by the precursor TTR protein. Hereditary, or mutant, ATTR (ATTRm) amyloidosis is caused by the presence of *TTR* mutations, resulting in a less stable TTR protein (1). Wild-type ATTR (ATTRwt) amyloidosis, previously referred to as “senile systemic amyloidosis,” is a result of age-related changes in wild-type TTR stability (1,4,7).

EPIDEMIOLOGY OF ATTRm. The prevalence of ATTRm is difficult to establish due to the variable geographical distribution of *TTR* mutations. Some mutations are endemic in certain regions, but recent estimates suggest that the prevalence in Europe is <1 in 100,000 (8). Conversely, although endemic in

some areas of Japan, the overall prevalence in Japan is thought to be much lower, approximately 1 in 1,000,000 (9). The valine 122 isoleucine substitution *TTR* mutation most commonly affects individuals of Sub-Saharan African ancestry and has an allele prevalence of 3% to 4% within the African-American population (10).

EPIDEMIOLOGY OF ATTRwt. Recent data suggest that ATTR-CM is overlooked as a cause of common cardiovascular conditions in older people, with relatively high rates among individuals diagnosed with HF with preserved ejection fraction (HFpEF) (11), low-flow aortic stenosis, and settings of increased wall thickness (3). Additionally, autopsy data have shown that among adults 80 years of age or older, 25% have significant TTR amyloid deposits in the myocardium (12). Despite being historically considered a disease of older age, there have been reports of diagnosis of ATTRwt in patients as young as 47 years (13). Although the exact prevalence of ATTRwt is unknown, it is almost certainly the most common cause of cardiac amyloidosis, particularly in the elderly, potentially accounting for up to 10% of elderly patients with HF (1,4). With a convenient and relatively inexpensive imaging modality, bone scintigraphy, having strong evidence as an accurate, noninvasive approach to diagnosing ATTR-CM (14,15), the number of patients identified as having this condition will undoubtedly increase in the future.

**ATTR-CM MANIFESTATIONS
AND MANAGEMENT**

Although ATTR-CM commonly presents with symptoms of HF or arrhythmias, amyloidosis is a systemic disease and can cause various noncardiac symptoms (3,16). Ophthalmological, neurological, and gastrointestinal symptoms can all be extracardiac signs of cardiac amyloidosis, particularly in ATTRm (1,16). Medical management of ATTR-CM remains a significant unmet need, with treatments for ATTR-CM currently being limited to the alleviation of HF symptoms, including sodium restriction or aldosterone antagonists in combination with loop diuretics (2,4). Heart transplantation alone or, in some ATTRm patients, in combination with liver transplantation, is

Dr. Gospodinova has received personal fees from Pfizer. Dr. Obici has received personal fees from Pfizer, Alnylam, and Akcea. Dr. Rapezzi has received grants from Pfizer; and has received personal fees from Pfizer, Alnylam, and Prothena. Dr. Garcia-Pavia has received grants from Pfizer, Alnylam, and Prothena; and has received personal fees from Pfizer, Eidos, Alnylam, Prothena, Neuroimmune, and Akcea.

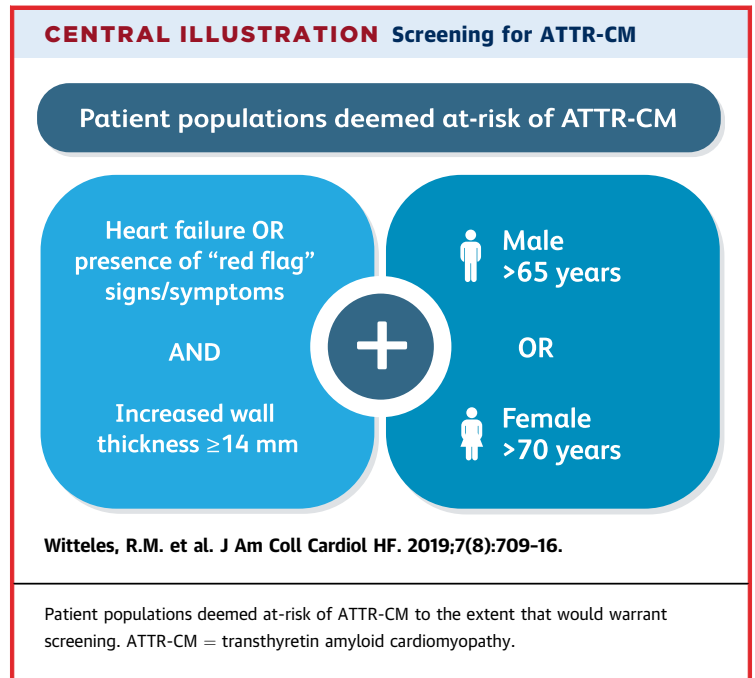
Manuscript received January 25, 2019; revised manuscript received April 15, 2019, accepted April 16, 2019.

an option for selected patients, but there are major limitations to these approaches, including transplantation eligibility, extracardiac organ involvement, limited organ supply, and post-transplantation complications (1,3,4,17). Until recently, there were no approved pharmacological therapies for use in patients with ATTR-CM. Based on positive phase III clinical trial results, tafamidis, a TTR stabilizer, has been approved in some countries for the treatment of hereditary and wild-type forms of ATTR-CM (18,19). Another TTR stabilizer has shown promising results in a recent phase II trial (20), and favorable results in clinical trials testing gene silencing compounds for neurologic dysfunction in ATTRm (21,22) suggest that other pharmacologic approaches may also be effective in managing ATTR-CM in the future.

DELAY TO DIAGNOSIS AND MISDIAGNOSIS OF ATTR-CM

Early diagnosis of ATTR-CM is key, as prognosis worsens rapidly with continued amyloid deposition and subsequent advancing organ dysfunction (3). However, diagnosis is often delayed owing to low disease awareness or misdiagnosis, which can be attributed to the previously perceived rarity of the disease, fragmented knowledge, erroneous beliefs around diagnosis and treatment, the heterogenic and multisystemic nature of the disease, and symptom overlap with other conditions (1,3,7). As a result, a high index of clinical suspicion is paramount to facilitate early and accurate diagnosis (7,23). Typically, a patient's cardiac disease progresses during the period of unidentified ATTR-CM, which is most often unrecognized during its early symptomatic stage. Diagnosis mostly occurs in the later stages of disease following the manifestation of serious cardiac symptoms (23,24).

The impact of ATTR-CM symptoms on a patient's quality of life can be significant, and the disease is associated with financial burden and professional difficulties (25). In a survey of ATTR-CM patients, 17% of all respondents reported visiting 5 different physicians before receiving the correct diagnosis. More than 50% of ATTRm and 39% of ATTRwt patients received a misdiagnosis; of those 76% and 75%, respectively, received treatment for the misdiagnosed condition (26). Additionally, a recent study from 2 European amyloidosis centers showed that 35% of ATTRwt patients had been previously misdiagnosed with other conditions, with hypertensive heart disease being the most frequent misdiagnosis (27). The result of misdiagnosis is, therefore, not only a prolonged time to appropriate patient management



strategies, but also the risk of inappropriate treatments (28). Typical antihypertensive and HF treatments such as beta blockers, angiotensin-converting enzyme inhibitors, or angiotensin II receptor antagonists are ineffective in cardiac amyloidosis patients, and often lead to clinical worsening (1,29). Moreover, other drugs such as digoxin and calcium channel blockers are relatively contraindicated in cardiac amyloidosis patients (1).









It is therefore crucial that physicians are aware, not only of ATTR-CM, but also of appropriate assessments, diagnostic tools, and clues within the patient's medical and family history that can help to elucidate etiology; this is of particular importance in light of the approval of tafamidis by the United States Food and Drug Administration (FDA) and in other countries (19), and of several emerging therapies which offer future treatment options for a disease which previously had none (13).

A clear framework of possible clinical scenarios and subsequent assessments is needed to aid in the identification of those at risk of having undetected ATTR-CM.

CLINICAL SCENARIOS AND "RED FLAGS" FOR ATTR-CM

A proposed disease identification framework, established by an international panel of 11 amyloidosis experts, is presented here. A list of clinical scenarios and red flags were proposed and considered by a working group of experts in the field. Their

FIGURE 1 Further Evidence to Support a Suspicion of ATTR-CM**“Red flags” for ATTR-CM**

-  Reduction in longitudinal strain with apical sparing
-  Discrepancy between left ventricular thickness and QRS voltage (with a lack of left ventricular hypertrophy on EKG)
-  Atrioventricular block, in the presence of increased left ventricular wall thickness
-  Echocardiographic hypertrophic phenotype with associated infiltrative features, including increased thickness of the atrioventricular valves, interatrial septum and right ventricular free wall
-  Marked extracellular volume expansion, abnormal nulling time for the myocardium or diffuse late gadolinium enhancement on CMR
-  Symptoms of polyneuropathy and / or dysautonomia
-  History of bilateral carpal tunnel syndrome
-  Mild increase in troponin levels on repeated occasions

“Red flags” that further support the possibility of an underlying ATTR-CM. ATTR-CM = transthyretin amyloid cardiomyopathy; CMR = cardiac magnetic resonance imaging; EKG = electrocardiogram.

subsequent discussions evaluated the language used to describe the clinical scenarios, their suitability for reflecting an underlying ATTR-CM, and usefulness to raise suspicion to define patient characteristics that would warrant screening for ATTR-CM (**Central Illustration**), and additional red flags that may help to further heighten suspicion or support the possibility of an underlying ATTR-CM as part of general clinical practice (**Figure 1**).

When developing a screening tool to aid in the recognition of a disease, one should consider the disease prevalence; the ease, impact, and accuracy of diagnostic testing; and the potential for effective treatment. In the case of ATTR-CM, prevalence is

likely higher than initially thought (15), bone scintigraphy represents a low-cost, low-impact diagnostic test (14), and there is now a drug approved by the FDA and in other countries with proven efficacy and safety in a phase III clinical trial (18,19), with others in development (1). Therefore, a broad screening approach to identify ATTR-CM is recommended within certain clinical scenarios (**Central Illustration**).

CLINICAL SCENARIOS THAT WOULD WARRANT SCREENING FOR ATTR-CM

The most common symptom of ATTR-CM is HF (1). Increased wall thickness caused by amyloid fibril deposition is a prominent characteristic of ATTR-CM (4) and can lead to ventricular stiffening and left ventricle diastolic dysfunction. One study showed that, in a cohort of 120 Caucasian patients aged ≥ 60 years with increased left ventricular wall thickness ≥ 12 mm admitted for HFpEF, 13.3% suffered from ATTRwt (11).

A significant male predominance has been reported in both ATTRwt (approximately 85% to 95%) and ATTRm, with a clear association between increased age and both ATTRwt and the most common types of ATTRm mutations (23,30,31). More recent findings have also suggested that a wider age range might be affected, as well as a higher proportion of female patients than previously recognized (13,27). As an example of the recently recognized increased involvement among women is that in the above-mentioned HFpEF cohort, 50% of identified ATTRwt patients were female (11).

Furthermore, in a cohort of predominantly male Caucasian patients (76%) with increased left ventricular wall thickness ≥ 15 mm, ATTRm was found in 7.6% of patients older than 55 years, including only 1.6% of patients aged 55 to 64 years, but 11.1% and 11.3% of patients aged 65 to 74 years and 75 to 84 years, respectively (32). Therefore, screening suspected individuals older than the age of 65 years with increased left ventricular wall thickness is particularly recommended.

Based on these values, the expert panel believe that the clinical scenarios of increased wall thickness with either HF or red flag signs/symptoms (see below) in men older than 65 years or women older than 70 years are expected to represent a significant rate of diagnosis, supporting the investigation of disease etiology through screening of these patients.

RED FLAGS FOR ATTR-CM

Clinical clues or red flags that should further heighten suspicion or alert clinicians to the possibility of

ATTR-CM as an underlying condition are listed in **Figure 1**. The presence of any of these red flags together with increased left ventricular wall thickness should lead to screening as described in **Figure 2**.

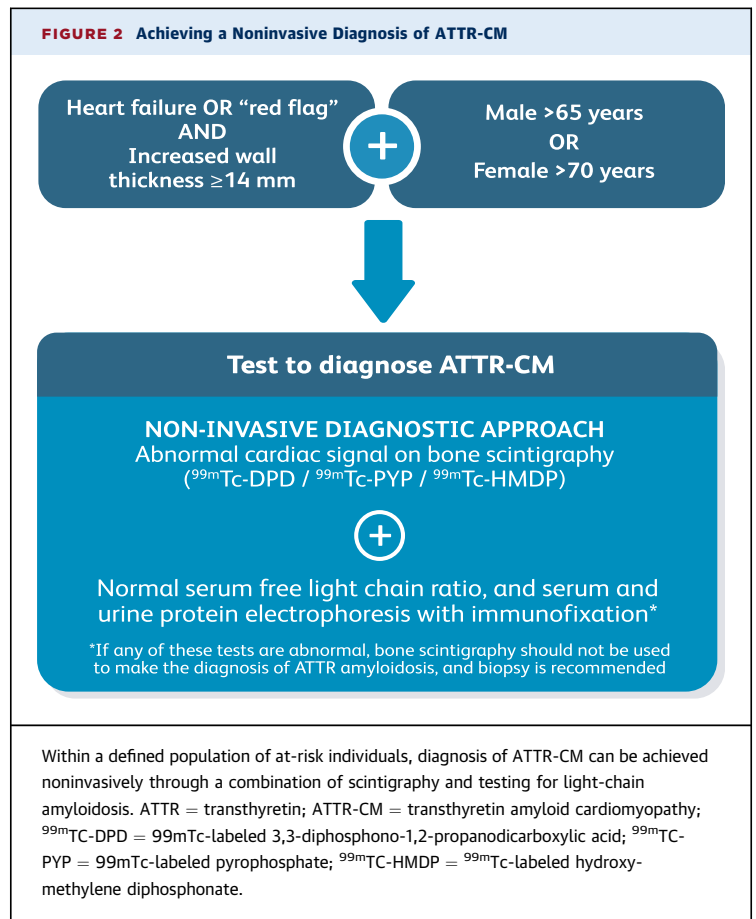
ECHOCARDIOGRAPHY. Echocardiography revealing a reduction in longitudinal strain with relative apical sparing can help to distinguish cardiac amyloidosis from other causes of increased left ventricular wall thickness (33).

ELECTROCARDIOGRAPHY. Another clue to cardiac amyloidosis is the discrepancy between left ventricular wall thickness and QRS voltages on a standard 12-lead electrocardiogram (EKG); although low voltages on an EKG in the setting of increased left ventricular wall thickness is a classic feature of cardiac amyloidosis, many ATTR-CM patients do not have frankly low voltages, but instead have a discrepancy between the presence of left ventricular hypertrophy on imaging with normal, or low-normal, voltages on EKG (3,4).

Atrioventricular block is another indicative feature of ATTR-CM and may be seen in up to 22% of patients with cardiac amyloidosis (34). Cardiac conduction abnormalities may be the first manifestation of ATTR-CM, and amyloid infiltration of the sinus and atrioventricular nodes may necessitate pacemaker implantation (1). A recent referral for a pacemaker for atrioventricular block, in the presence of left ventricular hypertrophy, should therefore raise clinical suspicion of ATTR-CM.

CARDIAC MAGNETIC RESONANCE. Suspicion for hypertrophic cardiomyopathy with evidence of infiltrative features, such as pericardial effusion, atrioventricular block, interatrial septal and valvular thickening, and apical sparing of longitudinal strain are all suggestive of ATTR-CM (3). Myocardial deposition of amyloid fibrils increases the extracellular volume and results in the accumulation of exogenous gadolinium contrast, seen with cardiac magnetic resonance (CMR) (3,4). Marked extracellular volume expansion, abnormal nulling time for the myocardium, and diffuse late gadolinium enhancement on CMR are, especially in combination, highly suspicious of ATTR-CM.

SYSTEMIC SYMPTOMS. The coexistence of systemic symptoms involving the peripheral and/or autonomic nervous system along with cardiac dysfunction are important clues to the presence of ATTR-CM (17) – although this is less common in ATTRm patients with the valine 122 isoleucine mutation (7), which is prevalent in the United States (35). Bilateral sensory-motor polyneuropathy that begins in the lower limbs and follows an ascending pattern, dysautonomia in



the form of orthostatic hypotension, diarrhea/constipation and erectile dysfunction, and eye involvement such as glaucoma, intravitreal deposition, and scalloped pupils, may be present in ATTRm (1). Carpal tunnel syndrome, lumbar spinal stenosis, and bicep tendon rupture are all common extracardiac manifestations in wild-type ATTR-CM. Bilateral carpal tunnel syndrome is often 1 of the earliest indicators of ATTR-CM, is the most common noncardiac manifestation (1,17,24), and can precede clinical HF by several years (2). A recent study found it present in approximately 50% of individuals with ATTRwt 5 to 7 years before diagnosis (36). Lumbar spinal stenosis and traumatic bicep tendon rupture have also been identified as clinical manifestations of extracardiac amyloid deposition in ATTRwt (1,37,38).

BIOMARKERS. Serum troponin levels are often persistently elevated (2), and, in the absence of an apparently severe cardiomyopathy on echocardiogram, should raise suspicion of ATTR-CM. N-terminal pro-B-type natriuretic peptide is also nearly always elevated in cases of cardiac amyloidosis (1,2), often disproportionately for the degree of HF.

TABLE 1 Serum and Urine Tests to Rule Out AL Amyloidosis*

Test	What Does it Detect?	Most Sensitive Test for:	Normal Range
SPIE†	Clonal immunoglobulin and/or clonal light chain	Confirming clonal immunoglobulin production	No M-spike present
UPIE†	Clonal immunoglobulin and/or clonal light chain	Confirming clonal light chain production	No M-spike present
Serum free light chain assay	Ratio of serum kappa:lambda light chains	Detecting low-level clonal light chain production; clonality assumed if ratio is far from 1:1	Kappa:lambda ratio = 0.26-1.65‡

*If any of these tests are abnormal, bone scintigraphy should not be used to make the diagnosis of ATTR amyloidosis, and biopsy is recommended. †SPIE and UPIE are more sensitive than protein electrophoresis without immunofixation and should be ordered as the preferred tests. ‡In patients with kidney disease, mild elevations in the kappa:lambda ratio are frequently encountered. In the setting of a normal SPIE/UIPE, a kappa:lambda ratio up to 2.5 can typically be considered normal.

AL = light-chain; ATTR = transthyretin amyloidosis; SPIE = serum protein electrophoresis with immunofixation; UPIE = urine protein electrophoresis with immunofixation.

ACHIEVING A DEFINITIVE DIAGNOSIS OF ATTR-CM

Once ATTR-CM is suspected, a timely, definitive diagnosis is recommended. On average, ATTR-CM patients have an approximate survival of 3 to 5 years from diagnosis (39), with the median survival time in ATTRm ranging from 26 to 62 months (35,40,41), and the median survival time in ATTRwt ranging from 43 to 67 months from diagnosis (13,30,31,35,40) and 73 months from symptom onset (31). Features ascertained from electrocardiography, echocardiography, CMR, and cardiac biomarkers are routinely used to identify cardiac abnormalities (3), and neurologic, ophthalmologic, and gastrointestinal assessments can help to identify noncardiac symptoms (7). A diagnosis can and should be achieved as soon as possible once suspicion has been raised, and noninvasive approaches to definitively diagnose ATTR-CM are available (Figure 2).

BONE SCINTIGRAPHY. Bone scintigraphy is a highly sensitive imaging technique that is used to evaluate the distribution of active bone formation in the body (42). Scintigraphy with technetium (Tc)-labelled bisphosphonates localizes to TTR cardiac amyloid deposits, although the molecular basis for this remains unknown (15). 99mTc-labeled 3,3-diphosphono-1,2-propanodicarboxylic acid, 99mTc-labeled pyrophosphate, and 99mTc-labeled hydroxymethylene diphosphonate have all shown high sensitivity and specificity for imaging cardiac TTR amyloid (15). The sensitivity of a positive scan alone for detecting TTR amyloid deposits was >99%, with a specificity of 86% in a large international study with more than 1,200 individuals. False-positive results were found mostly in AL amyloidosis patients (15).

RULING OUT AL AMYLOIDOSIS. Gillmore *et al.* (15) have shown that cardiac localization of radiotracer

in bone scintigraphy can occur in approximately 30% of patients with AL amyloidosis, which can confound the distinction between cardiac amyloidosis etiologies. As the survival of untreated patients with AL amyloidosis with cardiac involvement may be <6 months (5), and given the availability of disease modifying therapies for AL amyloidosis (2), ruling out this disease should be considered a clinical priority. This can be achieved through measuring the proportion of kappa:lambda light chains with the serum free light chain assay, and testing for immunofixation electrophoresis of serum and urine. The combination of serum and urine immunofixation and quantification of serum free light chains has a 99% sensitivity for identifying AL amyloidosis (3). Serum and urine protein electrophoresis should always be performed with immunofixation to increase the sensitivity of the assays for detecting low-level monoclonal proteins (Table 1). In the absence of a detectable monoclonal protein or an abnormal serum free light chain ratio, the specificity of bone scintigraphy for ATTR-CM is 100% (15).

BIOPSY. Traditionally, a definitive diagnosis of amyloidosis has been obtained through tissue biopsy stained with Congo red, which shows pathognomonic green birefringence of amyloid deposits when viewed under polarized light (3,15). Although the historic gold standard for diagnosis of cardiac amyloidosis was through endomyocardial biopsy (4,7), this invasive approach requires expertise and carries potential risks (43). Extracardiac biopsy specimens, such as abdominal fat pad, can yield a diagnosis in some patients, but the diagnostic accuracy can be particularly low in ATTR amyloidosis due to a high false-negative rate (3,44). Currently, histologic confirmation is still needed in cases where both bone scintigraphy and tests for monoclonal protein (suggestive of possible AL amyloidosis) are abnormal, to confirm and type amyloid deposits by immunohistochemistry or mass spectrometry. Given that between approximately 2% to 8% of the general population older than 65 years of age exhibit findings compatible with monoclonal gammopathy of undetermined significance (45), this is not a rare scenario in the evaluation of a patient with suspected ATTRwt amyloidosis. We recommend mass spectrometry as the preferred method for amyloid typing in most cases, as immunohistochemistry findings are often subtle and can be misinterpreted if not in very experienced hands (46).

GENETIC TESTING. Given that it is not possible to reliably distinguish between ATTRm and ATTRwt by clinical or histologic techniques, TTR gene

sequencing is recommended for the definitive diagnosis in all forms of confirmed ATTR-CM (1).

CONCLUSIONS

ATTR-CM represents a significant burden to patients and health care systems alike, particularly as it is associated with protracted diagnosis, or misdiagnosis, leading to delays in the application of appropriate management strategies. Generally low levels of disease awareness coupled with heterogeneity of clinical manifestations have resulted in suboptimal recognition and identification of ATTR-CM. Traditional, invasive diagnostic tools are no longer deemed necessary to achieve definitive diagnosis for most patients, owing to the diagnostic accuracy of bone scintigraphy. Given the recent approval of tafamidis by the FDA and in other countries based on a positive ATTR-CM phase III trial, with further promising therapies in development, it is important to correctly identify patients. Within this current framework, a

series of clinical scenarios and clues that should raise suspicion of ATTR-CM, and diagnostic approaches, have been outlined.

ACKNOWLEDGMENTS The authors thank Dr. Arthur Pollak for his contribution. Medical writing support was provided by Ivan Rattray of Synergy Medical Communications UK and was funded by Pfizer. This manuscript was developed based on discussions at an expert scientific meeting. Each author of this manuscript received an honorarium from Pfizer for their participation in this scientific meeting; however, the authors were not paid for their work developing the manuscript and views and opinions expressed are solely those of the authors.

ADDRESS FOR CORRESPONDENCE: Dr. Pablo Garcia-Pavia, Department of Cardiology, Hospital Universitario Puerta de Hierro, Manuel de Falla, 2. Majadahonda, Madrid 28222, Spain. E-mail: pablogpavia@yahoo.es.

REFERENCES

- González-López E, López-Sainz Á, Garcia-Pavia P. Diagnosis and treatment of transthyretin cardiac amyloidosis. Progress and hope. *Rev Esp Cardiol (Engl Ed)* 2017;70:991-1004.
- Donnelly JP, Hanna M. Cardiac amyloidosis: an update on diagnosis and treatment. *Cleve Clin J Med* 2017;84:12-26.
- Maurer MS, Elliott P, Comenzo R, Semigran M, Rapezzi C. Addressing common questions encountered in the diagnosis and management of cardiac amyloidosis. *Circulation* 2017;135:1357-77.
- Siddiqi OK, Ruberg FL. Cardiac amyloidosis: an update on pathophysiology, diagnosis, and treatment. *Trends Cardiovasc Med* 2018;28:10-21.
- Sperry BW, Ikram A, Hachamovitch R, et al. Efficacy of chemotherapy for light-chain amyloidosis in patients presenting with symptomatic heart failure. *J Am Coll Cardiol* 2016;67:2941-8.
- Arbustini E, Merlini G. Early identification of transthyretin-related hereditary cardiac amyloidosis. *J Am Coll Cardiol Cardiovasc Img* 2014;7:511-4.
- Rapezzi C, Lorenzini M, Longhi S, et al. Cardiac amyloidosis: the great pretender. *Heart Fail Rev* 2015;20:117-24.
- Ando Y, Coeltho T, Berk JL, et al. Guideline of transthyretin-related hereditary amyloidosis for clinicians. *Orphanet J Rare Dis* 2013;8:31.
- Kato-Motozaki Y, Ono K, Shima K, et al. Epidemiology of familial amyloid polyneuropathy in Japan: identification of a novel endemic focus. *J Neurol Sci* 2008;270:133-40.
- Jacobsen DR, Alexander AA, Tagoe C, Buxbaum JN. Prevalence of the amyloidogenic transthyretin (TTR) V122I allele in 14333 African-Americans. *Amyloid* 2015;22:171-4.
- González-López E, Gallego-Delgado M, Guzzo-Merello G, et al. Wild-type transthyretin amyloidosis as a cause of heart failure with preserved ejection fraction. *Eur Heart J* 2015;36:2585-94.
- Tanskanen M, Peuralinna T, Polvikoski T, et al. Senile systemic amyloidosis affects 25% of the very aged and associates with genetic variation in alpha2-macroglobulin and tau: a population-based autopsy study. *Ann Med* 2008;40:232-9.
- Grogan M, Scott CG, Kyle RA, et al. Natural history of wild-type transthyretin cardiac amyloidosis and risk stratification using a novel staging system. *J Am Coll Cardiol* 2016;68:1014-20.
- Papantoniou V, Valsamaki P, Kastritis S, et al. Imaging of cardiac amyloidosis by 99mTc-PYP scintigraphy. *Hell J Nucl Med* 2015;18:42-50.
- Gillmore JD, Maurer MS, Falk RH, et al. Non-biopsy diagnosis of cardiac transthyretin amyloidosis. *Circulation* 2016;133:2404-12.
- Mohty D, Damy T, Cosnay P, et al. Cardiac amyloidosis: updates in diagnosis and management. *Arch Cardiovasc Dis* 2013;106:528-40.
- Gertz MA, Benson MD, Dyck PJ, et al. Diagnosis, prognosis, and therapy of transthyretin amyloidosis. *J Am Coll Cardiol* 2015;66:2451-66.
- Maurer MS, Schwartz JH, Gundapaneni B, et al. Tafamidis treatment for patients with transthyretin amyloid cardiomyopathy. *N Engl J Med* 2018;379:1007-16.
- U.S. Food and Drug Administration. FDA approves new treatments for heart disease caused by a serious rare disease, transthyretin mediated amyloidosis. FDA News Release May 06, 2019. Available at: <https://www.fda.gov/news-events/press-announcements/fda-approves-new-treatments-heart-disease-caused-serious-rare-disease-transthyretin-mediated>. Accessed May 10, 2019.
- Judge DP, Falk RH, Maurer MS, et al. Transthyretin stabilization by AG10 in symptomatic transthyretin amyloid cardiomyopathy. *J Am Coll Cardiol* 2019 Mar 12 [E-pub ahead of print].
- Adams D, Gonzalez-Duarte A, O'Riordan WD, et al. Patisiran, an RNAi therapeutic, for hereditary transthyretin amyloidosis. *N Engl J Med* 2018;379:11-21.
- Solomon SD, Adams D, Kristen A, et al. Effects of patisiran, an RNA interference therapeutic, on cardiac parameters in patients with hereditary transthyretin-mediated amyloidosis: an analysis of the APOLLO study. *Circulation* 2019;139:431-43.
- Maurer MS, Hanna M, Grogan M, et al. Genotype and phenotype of transthyretin cardiac amyloidosis: THAOS (Transthyretin Amyloid Outcome Survey). *J Am Coll Cardiol* 2016;68:161-72.
- Papoutsidakis N, Miller EJ, Rodonski A, Jacoby D. Time course of common clinical manifestations in patients with transthyretin cardiac amyloidosis: delay from symptom onset to diagnosis. *J Card Fail* 2018;24:131-3.
- Amyloidosis Research Consortium. Voice of the Patient. Available at: <https://www.arci.org/voice-of-the-patient/>. Accessed November 2018.
- Lousada I, Maurer M, Warner M, Guthrie S, Hsu K, Grogan M. Amyloidosis research consortium cardiac amyloidosis survey: results from patients with ATTR amyloidosis and their caregivers. *Orphanet J Rare Dis* 2017;2 suppl 1:P7.

- 27.** González-López E, Gagliardi C, Dominguez F, et al. Clinical characteristics of wild-type transthyretin cardiac amyloidosis: disproving myths. *Eur Heart J* 2017;38:1895-904.
- 28.** Medscape. Transthyretin-Related Amyloidosis. Available at: <https://emedicine.medscape.com/article/335301>. Accessed November 2018.
- 29.** Aus dem Siepen F, Hein S, Bauer R, et al. Standard heart failure medication in cardiac transthyretin amyloidosis: useful or harmful? *Amyloid* 2017;24:132-3.
- 30.** Connors LH, Sam F, Skinner M, et al. Heart failure resulting from age-related cardiac amyloid disease associated with wild-type transthyretin: a prospective, observational cohort study. *Circulation* 2016;133:282-90.
- 31.** Pinney JH, Whelan CJ, Petrie A, et al. Senile systemic amyloidosis: clinical features at presentation and outcome. *J Am Heart Assoc* 2013;2:e000098.
- 32.** Damy T, Costes B, Hagège AA, et al. Prevalence and clinical phenotype of hereditary transthyretin amyloid cardiomyopathy in patients with increased left ventricular wall thickness. *Eur Heart J* 2016;37:1826-34.
- 33.** Phelan D, Collier P, Thavendiranathan P, et al. Relative apical sparing of longitudinal strain using two-dimensional speckle-tracking echocardiography is both sensitive and specific for the diagnosis of cardiac amyloidosis. *Heart* 2012;98:1442-8.
- 34.** Huang J, Zhao S, Chen Z, et al. Contribution of electrocardiogram in the differentiation of cardiac amyloidosis and nonobstructive hypertrophic cardiomyopathy. *Int Heart J* 2015;56:522-6.
- 35.** Ruberg FL, Berk JL. Transthyretin (TTR) cardiac amyloidosis. *Circulation* 2012;126:1286-300.
- 36.** Nakagawa M, Sekijima Y, Yazaki M, et al. Carpal tunnel syndrome: a common initial symptom of systemic wild-type ATTR (ATTRwt) amyloidosis. *Amyloid* 2016;23:58-63.
- 37.** Geller HI, Singh A, Alexander KM, Mirto TM, Falk RH. Association between ruptured distal biceps tendon and wild-type transthyretin cardiac amyloidosis. *JAMA* 2017;318:962-3.
- 38.** Westermark P, Westermark GT, Suhr OB, Berg S. Transthyretin-derived amyloidosis: probably a common cause of lumbar spinal stenosis. *Ups J Med Sci* 2014;119:223-8.
- 39.** Dungu JN, Anderson LJ, Whelan CJ, Hawkins PN. Cardiac transthyretin amyloidosis. *Heart* 2012;98:1546-54.
- 40.** Connors LH, Doros G, Sam F, Badiee A, Seldin DC, Skinner M. Clinical features and survival in senile systemic amyloidosis: comparison to familial transthyretin cardiomyopathy. *Amyloid* 2011;18:157-9.
- 41.** Givens RC, Russo C, Green P, Maurer MS. Comparison of cardiac amyloidosis due to wild-type and V122I transthyretin in older adults referred to an academic medical center. *Aging Health* 2013;9:229-35.
- 42.** Van den Wyngaert T, Strobel K, Kampen WU, et al. The EANM practice guidelines for bone scintigraphy. *Eur J Nucl Med Mol Imaging* 2016;43:1723-38.
- 43.** Stawek S, Araszkievicz A, Gaczkowska A, et al. Endomyocardial biopsy via the femoral access – still safe and valuable diagnostic tool. *BMC Cardiovasc Disord* 2016;16:222.
- 44.** Quarta CC, Gonzalez-Lopez E, Gilbertson JA, et al. Diagnostic sensitivity of abdominal fat aspiration in cardiac amyloidosis. *Eur Heart J* 2017;38:1905-8.
- 45.** Kyle RA, Therneau TM, Rajkumar SV, et al. Prevalence of monoclonal gammopathy of undetermined significance. *N Engl J Med* 2006;354:1362-9.
- 46.** Rezk T, Gilbertson JA, Mangione PP, et al. The complementary role of histology and proteomics for diagnosis and typing of systemic amyloidosis. *J Pathol Clin Res* 2019 Feb 11 [E-pub ahead of print].

KEY WORDS amyloidosis, cardiomyopathy, diagnosis, identification, transthyretin amyloid