



Current concepts in ablative procedures for primary benign liver lesions: a step forward to minimize the invasiveness of treatment when deemed necessary

Aldo Carnevale¹ · Fabio Pellegrino² · Alberto Cossu¹ · Anna Maria Ierardi³ · Gian Carlo Parenti⁴ · Gianpaolo Carrafiello³ · Melchiorre Giganti²

Received: 13 December 2019 / Accepted: 28 February 2020
© Springer Science+Business Media, LLC, part of Springer Nature 2020

Abstract

With increased use of medical imaging, the incidental detection of benign solid liver tumors has become more frequent. Facing with benign disease, the indications for surgery are still object of discussion in light of the stable natural course of most lesions and obvious drawbacks of any surgical intervention; therefore, in most situations, a conservative approach is recommended, and surgery is mainly reserved for those cases with persistent or worsening symptoms, or who are at risk for complications as malignant transformation. The advent of ablative techniques has widened the range of treatment options available to these patients, presenting as a valid alternative to resection in terms of safety and efficacy in selected cases, particularly in patients who are considered poor surgical candidates and with smaller lesions. This review outlines the role of percutaneous ablative methods for benign solid liver tumors that are encountered in adults, providing a per histology analysis of the existing evidence. The up-to-date strategies for management of the most common benign solid tumors are recapitulated.

Keywords Benign tumors · Liver · Ablation · Hepatic hemangioma · Hepatocellular adenoma

Introduction

Over the past decades, the dramatic rise in abdominal imaging has led to a steady increase in the incidental detection of asymptomatic lesions, including benign liver tumors (BLT). BLT are a diverse group of lesions with different cellular origins, in which clonal analysis has shown a spectrum of regenerative and neoplastic features [1]. They are relatively frequent, since autopsy series have reported incidences up to 50% [2]. BLT are generally classified into solid and

cystic based on imaging characteristics; among them, cystic tumors probably occur more frequently than solid ones [3]. Hemangiomas (HH), focal nodular hyperplasia (FNH) and hepatocellular adenoma (HCA) are the most common solid BLT [4].

With the increasing detection of BLT during cross-sectional imaging obtained for other reasons, it is quite clear that clinicians are more frequently faced with the dilemma regarding the management of these findings. The trend toward a conservative approach for accidentally discovered

✉ Melchiorre Giganti
melchiorre.giganti@unife.it

Aldo Carnevale
aldocarnevale@hotmail.it

Fabio Pellegrino
fabio.pellegrino@unife.it

Alberto Cossu
alberto.cossu@unife.it

Anna Maria Ierardi
amierardi@yahoo.it

Gian Carlo Parenti
parentigiancarlo@libero.it

Gianpaolo Carrafiello
gcarraf@gmail.com

¹ University Radiology Unit, Radiology Department, Arcispedale Sant'Anna, Via A. Moro 8, Ferrara 44123, Italy

² Department of Morphology, Surgery and Experimental Medicine, Radiology Section, University of Ferrara, Via L. Ariosto 35, Ferrara 44121, Italy

³ Diagnostic and Interventional Radiology Department, ASST Santi Paolo E Carlo, San Paolo Hospital, University of Milan, Via A di Rudini 8, Milan 20142, Italy

⁴ Department of Diagnostic Imaging of Romagna, Ospedale Civile Santa Maria Delle Croci, Ravenna 48100, Italy

liver lesions entails an accurate diagnosis to reassure both the patient and the clinician regarding the specific type of lesion and, consequently, its natural history. Thanks to the constant improvement of imaging modalities and better understanding of complications related to different histologies, most BLT can be managed safely with observation alone [4]. Therefore, radiological data are crucial for restricting the number of percutaneous biopsies and the resections performed for final diagnosis [5].

Some of these lesions, however, are of greater clinical relevance than others, because of risks of complications including significant clinical symptoms and potential malignant change [2, 4, 6].

Facing with benign disease, the indications for surgery may be variable and somewhat subjective, mainly reserved for those cases with persistent or worsening symptoms and suspicion of malignant transformation [2, 3], in light of the obvious drawbacks of almost any surgical intervention.

In the last decades, percutaneous minimally invasive procedures have advanced considerably, and this widespread use represents the result of a varied combination of factors including the reduction of peri-operative complications and postoperative recovery time, the development and refinement of new technologies, and patient awareness of emerging therapeutic approaches [7]. These therapies have therefore gained great attention and widespread clinical acceptance as valuable methods for treating focal malignancies in a diverse spectrum of tumor types and tissues.

Even in the setting of BLT, percutaneous ablative procedures may represent a possible alternative.

This review describes the existing evidence about the use of percutaneous ablative procedures for the treatment of solid benign liver lesions.

Materials and methods

In this study, we adhered to the standard guidelines of Preferred Reporting Items for Systematic Reviews and Meta-Analyses (PRISMA) [8].

An extended systematic search in Medline database (via PubMed) including articles related to human medicine was performed by two independent physicians (FP and ACo) with experience in literature search strategies and data extraction.

On the basis of the PICO methodology, articles were selected according a priori inclusion criteria: (a) population was identified as subjects aged > 18 years with an established BLT diagnosis; (b) intervention as percutaneous ablation through different techniques; (c) outcome as feasibility, safety, clinical outcomes or prognosis for this kind of intervention; (d) type of study as controlled or comparative, randomized or nonrandomized experimental studies, prospective

or retrospective observational studies, including also case series (> 3 patients); (e) works written in English.

The search strategy was elaborated to include the greatest number of references dealing with the populations and the interventions object of the study by using the following keywords in combination with the Boolean operators AND and OR: “ablation”, “hemangioma”, “hepatic adenomas”, “liver neoplasms”; studies regarding the treatment of hepatocellular carcinoma or liver metastases were excluded by using the keywords “hepatocellular carcinoma”, “metastasis” with the Boolean operators NOT.

The literature search was not restricted to any publication date.

At first, the reviewers checked the results at both the title and abstract level. Then, the full texts of the selected studies were retrieved and reference lists were manually cross-checked to find any relevant study that was missed with our search strategy but met the prespecified PICOS criteria. In case of disagreement between the two reviewers, a further author (ACa) was consulted to achieve a consensus.

Data from the selected studies were collected into a standardized form.

Results

The search strategy provided 2096 potentially relevant citations. After removal of case reports, case series (≤ 3 patients), reviews, guidelines, and original articles not in the field of interest, and after accurate check of reference lists of the full-text articles retrieved, there were finally 22 studies which fulfilled the inclusion and exclusion criteria (Fig. 1). The characteristics of the original articles included are summarized in Table 1.

We provide below a per histology analysis of the results.

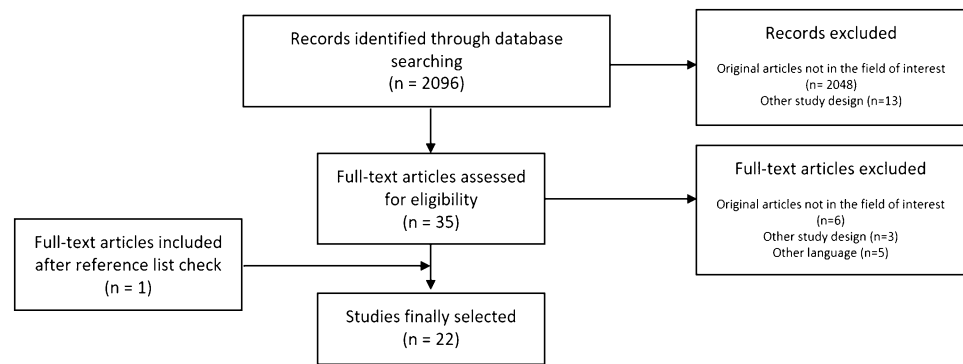
Adenoma

Seven retrospective studies dealing with percutaneous ablation of BLTs including HCAs were selected in the present work.

Patient characteristics

Rhim et al. [9] treated eight asymptomatic patients and two patients with recurrent tumor after surgical resection who refused to undergo any further surgical procedure or conservative management by imaging follow-up. Two patients presented with liver cirrhosis related to virus B infection or alcoholic abuse, while no patient had predisposing factors for HCA, such as history of oral contraceptives or steroid therapy. No signs of cirrhosis were reported in other studies [10–13]. The patients treated in the other series were mostly

Fig. 1 Flow chart shows summary of the literature review process



asymptomatic except for a declared history of HCA-related hemorrhage present only in 11% and 22% of cases [10, 12]. The use of oral contraceptives was the main predisposing factor [10–12].

The decision to pursue percutaneous ablation therapy was based on a multidisciplinary discussion [12, 13], or established considering multiple factors. Ablation was performed in patients not amenable to surgery in view of comorbidities, location or number of the lesions, or in cases otherwise requiring large liver resections [10, 13], owing to an expected lower rate of procedural complications compared with surgery [13]. Van Vledder et al. treated 18 women with HCAs and, in this population, the desire to become pregnant was a relevant motivation to consider the intervention [10].

General contraindications were: severe blood coagulation dysfunction, active inflammatory or infectious process, acute or severe renal insufficiency, pulmonary or cardiac dysfunction [14]. If the lesion was uncertain for malignancy based on radiologic examination alone, surgery was considered the treatment of choice [10].

In most patients the diagnosis was confirmed by biopsy after imaging evaluation and prior to ablation, except for one patient [13] in which clinical and imaging findings were highly suggestive for HCA and biopsy was not obtained, and a series [10] in which the diagnosis was based on radiology data alone, including contrast-enhanced magnetic resonance (MR) and multiphasic computed tomography (CT) imaging.

Ablation procedures

Percutaneous radiofrequency (RF) or microwave (MW) ablation were used for all patients under US, CT, or combined guidance. RF or MW ablation (RFA, MWA) time varies among the series, with total procedure times ranging from averages of 3 to 22 min depending on the different series and techniques employed [9–12]. Van Vledder et al. compared the use of a CT-guided percutaneous approach to an open approach in which US-guided RF ablation was combined

with resection, strategy applied also in some patients with liver adenomatosis (i.e., ≥ 10 nodules) [10].

Procedural and clinical outcomes

Rhim et al. reported 100% primary efficacy rate with complete ablation without any residual viable tumor at post-procedural imaging [9]. Comparing percutaneous to open ablation, Van Vledder and colleagues found a significant difference in primary efficacy, with a higher percentage in the open ablation group than in the percutaneous ablation group (79% and 31%, respectively; $p=0.013$). The rate of local technical failures reported in this study is relatively high, with 50% of patients requiring more than one RF ablation sessions to obtain a satisfactory treatment of all HCAs [10]. According to the data reported by Costa et al., only one out of 26 (4%) ablated HCAs showed evidence of residual disease at the first follow-up imaging with nodular or irregular enhancement, subsequently treated to complete ablation after a repeated session [11]. Moreover, they showed that fat tissue found in the ablation zone did not seem to be related to the residual tumor but was associated with significant steatosis and/or intratumoral fat [11]. Mironov et al. described complete ablation after the first treatment session in 88% of cases with total response with further ablative sessions [12]. Smolock et al. successfully treated 12 HCAs of which only one lesion of 8.3 cm diameter underwent two planned ablation sessions, therefore with a primary efficacy of 100% [13]. No local tumor progression, malignant transformation, hemorrhage or death were reported in these studies during follow-up periods [9, 12, 13].

Complications

The complication rate for the procedures reported among the selected studies is low. Two immediate post-procedural hemorrhages (4.5% per procedure) were described [12]: in one patient treated with MWA and in a patient who underwent

Table 1 Characteristics of the studies fulfilling the inclusion criteria of the review

Author	Year	Study design	Patient number	Median age (y)	Tumor number	Tumor histology	Tumor size
Tang X	2019	Retrospective comparative study	112: 44 via MWA and 68 via surgery	40/4 (<60/>60) (MWA group)	44; 68	HHs	6.9 ± 1.5 cm (MWA group)
Wang S	2019	Experimental study	32	52.97 ± 9.04 (35–79)	32	HHs	8.49 ± 2.49 cm (5.00–14.10)
Li X	2019	Retrospective comparative study	58; 3D group: 25 patients and 2D group: 33 patients	43.5 ± 8.2 (28–60)	58	HHs	7.4 ± 1.5 cm (5–12.6); 3D group: 7.5 ± 1.7, 2D group: 7.2 ± 1.3
Wang Z	2018	Retrospective study	12	41 ± 6 (31–67)	13	HHs	11.7 ± 1.6 cm (10–14.5)
Li D	2018	Retrospective study	n.a	n.a	123	HHs, HCAs, FNHs	n.a
Mironov H	2018	Retrospective study	36	35 (19–76)	58	HCAs	2.1 cm (0.6–6.0)
Liu F	2017	Retrospective study	40	43.25 ± 7.65	42	HHs	7.02 ± 1.55 cm (4.1–10.8)
Liu F	2018	Retrospective study	49	43.20 ± 8.22	51	HHs	7.45 ± 1.78 cm (4.1–12.6)
Yang X	2017	Retrospective study	22	n.a	n.a	angiomyolipoma	<5 cm
Cheng Z	2017	Retrospective study	37	43.6 ± 10.6 (23–70)	44	14 HH, 5 FNHs, 6 inflammatory pseudotumor, 5 solitary necrotic nodules, 3 HCAs, 3 angiomyolipomas, 1 epithelioid hemangioma, 1 endothelioma	33.0 ± 19.1 mm
Costa AF	2017	Retrospective study	16	18–56	26	HCAs	2.6 ± 0.9 cm (1.1–4.8)
Ji J	2016	Retrospective study	15	43.5 ± 7.5 (29–54)	15	HHs	13.0 ± 2.2 cm (10.0–16.0)
Smolock A	2016	Retrospective study	6	39.6	12	HCAs	2.7 ± 2.0 cm (0.8–8.3)
Gao J	2015	Retrospective comparative study	51	Percutaneous CT-guided: 50.0 ± 14.5; laparoscopic: 49.5 ± 8.27	51 (percutaneous CT-guided: 24; laparoscopic: 27)	HHs (abutting the diaphragm)	9.6 ± 1.8 cm (6.0–12.0)
Tang XY	2015	Retrospective study	46	46 ± 11 (25–65)	47	HHs	6.3 ± 1.4 cm (5.0–9.6)
Ziemlewicz J	2014	Retrospective study	7	44	8	HHs	7.3 cm (3.4–12.2)
Gao J	2013	Retrospective comparative study	42	Multitined electrodes (n=21): 53.6 ± 12.0; internally cooled electrodes (n=21): 51.3 ± 9.7	43 (22 in 21 patients; 21 in 21 patients, respectively)	HHs	12.5 ± 1.6 cm (10.0–16.0)
Gao J	2013	Retrospective comparative study	36	50.12 (27–76)	41 (15 via percutaneous approach, 26 via laparoscopic approach)	HHs	10 ± 4 cm (5–22)
Van Vledder MG	2011	Retrospective study	18	29.5 (21–37)	45	HCAs	3.0 cm (0.8–7.3)
Park SY	2011	Retrospective study	24	49.5 ± 2.2 (37–73)	25	HHs	7.2 ± 0.7 cm (4.0–15.0)
Rhim H	2007	Retrospective study	10	39.2 (19–54)	12	HCAs	2.25 ± 0.76 cm (1.5–4.5)
Cui Y	2003	Retrospective study	12	41.7 (33–56)	15	HHs	6 ± 3.5 cm (2.5–9.5)

Table 1 (continued)

Author	Year	Ablation technique	Follow-up duration	Residual/recurrence	Outcomes	Complications
Tang X	2019	MWA (US-guided)	44 months	Complete ablation in 41 patients (93.2%); the remaining were not re-treated	Symptoms disappeared in both groups	Minor complications in both groups, with acute kidney injury in 3 patients in the MWA group; major complications (grade III Clavien–Dindo) in 1 case (diaphragmatic hernia requiring surgical repair) in the MWA group, in 5 patients who underwent surgery
Wang S	2019	RF (laparoscopic; 26; CT-guided percutaneous; 6)	3 days (clinical examination, blood test analysis)	n.a	n.a	22 complications in 16 patients; 16 patients (50.0%) experienced SIR syndrome within one day after ablation. No major complications (grade I Dindo–Clavien)
Li X	2019	MWA (US-guided)	n.a	Complete ablation rate: 3D group 97.7 ± 2.4 (93–100); 2D group 94.5 ± 3.7 (90–100)	n.a	1 case of acute renal failure resolved after medical treatment and 12 hemodialysis sessions; no other severe complications. Hemoglobinuria: 3D group 8/17; 2D group 19/14
Wang Z	2018	MWA (US-guided)	7–38 months	Complete ablation in 10 lesions in 9 patients (76.9%, 10/13); total complete ablation rate was 84.6% (11/13). One patient underwent a second session of MWA	n.a	2 patients had acute postoperative nonoliguric renal insufficiency that required medical treatment; liver function test abnormalities that recovered within 7 days, with no irreversible liver failure
Li D	2018	MWA (US-guided)	n.a	n.a	n.a	Hemoglobinuria in 17/123 cases (all HHs; 17/57, 29.8%); only one patient progressed to acute kidney injury requiring medical treatment, dialysis 8 times and plasmapheresis 5 times
Mironov H	2018	RFA (36/44), MWA (8/44) under CT, US or combined guidance	1.7 years	Complete ablation	No cases of malignant transformation or further HCA-related hemorrhages	2 major complications of immediate post-procedural hemorrhages (4.5% per procedure); 1 case was treated conservatively, the other by transarterial embolization

Table 1 (continued)

Author	Year	Ablation technique	Follow-up duration	Residual/recurrence	Outcomes	Complications
Liu F	2017	MWA (US-guided)	24 months (6–60)	38 lesions were completely necrotic, 4 lesions were more than 90% necrotic (dangerous location) within 3 days after ablation	38/40 patients had complete pain relief or improvement of pain and nausea, abdominal fullness following the procedure	1 major complication (acute kidney injury); renal function gradually recovered after hemodialysis. Minor complications included fever, transient elevation of transaminase, pleura effusion, and hemoglobinuria
Liu F	2018	MWA (US-guided)	n.a	44 lesions were completely necrotic, 5 lesions were more than 90% necrotic (dangerous location) within 3 days after ablation	n.a	20 cases of hemoglobinuria; 1 case of acute kidney injury requiring 12 hemodialysis sessions
Yang X	2017	RFA (US-guided)	n.a	Complete ablation; 2 cases or recurrence after partial hepatectomy	No cases of malignant change	Minor complications in all patients (grade I, Clavien–Dindo), including low serum albumin, pleural effusion, mild pulmonary infection, short-term intestinal obstruction and bile leakage
Cheng Z	2017	MWA (US-guided)	27 months (6–73)	40 nodules (90.9%) were completely ablated; no evidence of recurrence. 4 nodules (9.1%) were partially ablated due to the proximity of adjacent vital organs	In 5 cases symptoms completely recovered or were alleviated; in 12 cases psychological pressure was relieved	Minor complications without sequelae, including local pain and transient hemoglobinuria; no major complications
Costa AF	2017	RFA (US or CT-guided)	27 months (2–84)	Only 1/26 (4%) ablated nodule showed frank nodular or irregular enhancement along the ablation zone margin, which increased over time in keeping with residual tumor, successfully reablated	n.a	n.a
Ji J	2016	RFA (CT-guided) + TAE	2 years	14/15 (93.3%) were completely ablated; one HH was incompletely ablated	n.a	6 complications in 4 patients, including transient liver function test abnormalities and fever; all the complications were minor (grade I, Clavien–Dindo),
Smoock A	2016	MWA (US-guided)	12.6 ± 7.1 months	Complete ablation (a 8.3-cm HCA underwent two planned ablation sessions); no recurrence	No malignant transformation or new hepatic tumors	No major complications (Society of Interventional Radiology); 1 patient required a overnight readmission for pain control

Table 1 (continued)

Author	Year	Ablation technique	Follow-up duration	Residual/recurrence	Outcomes	Complications
Gao J	2015	RFA (CT and US-guided, respectively)	6 months	Complete ablation in 91.7% (22/24) and 96.3% (26/27) in the CT-guided and the laparoscopic ablation groups, respectively	28/31 patients with symptoms experienced complete resolution; 3/31 reported improvement of symptoms	23 thoracic complications in 17 patients, including 15 (62.5%) in the CT-guided group and 2 (7.4%, 2/27) in the laparoscopic approach group (Dindo–Clavien classification), 2 complications (pleural effusion and diaphragmatic rupture) were major in 2 patients
Tang XY	2015	MWA (US-guided)	18.2 months (4–40)	Initial complete ablation rate 91.5% (43/47). Total complete ablation rate was 95.7% (45/47), since one patient with two residual lesions received a second successful MWA	3 patients developed new HHs	Major complications (5/46 patients) included 2 cases of acute renal failure, 1 case of hyperbilirubinemia and 2 cases of pleural effusion
Ziemiiewicz J	2014	MWA (US-guided)	18 months (1–33)	Complete ablation in 2 tumors; in 3 tumors 90% of ablation volume due to unfavorable location; in 3 tumors minimal residual enhancement	In 6/7 patients symptoms disappeared or improved	No complications
Gao J	2013	RFA (US-guided laparoscopic, CT-guided percutaneous approach (n = 16))	6 months	Complete ablation in 81.8% (multitined electrodes) and 90.5% (internally cooled electrodes); no recurrence	35/38 patients with symptoms reported complete relief; 3/38 reported symptom improvement	79 complications (2 major and 77 minor) in 31 patients; major complications (grade III and IV, Dindo–Clavien classification; details below)
Gao J	2013	RFA (US-guided in the laparoscopic approach, CT-guided in the percutaneous approach)	1.5 ± 6 months (6–24)	Complete ablation in 38/41 (93%), including 100% of lesions < 10 cm	22/26 patients with symptoms reported complete relief; 4/26 reported symptom improvement	62 complications in 22 patients: 2 major complications (grade III and IV, Dindo–Clavien classification) in 2 patients (lower esophageal fistula and ARDS, respectively)
Van Vledder MG	2011	RFA (US or CT-guided with surgical or percutaneous approach, respectively)	440 days (41–1,35)	Complete ablation after the first session in 26 HCAs (57.8%), in 9 cases after a second session (20%); the majority underwent multiple RFA sessions. Residual disease in 7 lesions in 5 patients	n.a	2 major procedure-related complications (class D, Society of Interventional Radiology): 1 severe intraoperative bleeding with consequent cerebral ischemia, 1 liver abscess in the site of ethanol injection

Table 1 (continued)

Author	Year	Ablation technique	Follow-up duration	Residual/recurrence	Outcomes	Complications
Park SY	2011	RFA (US-guided)	23 ± 3.8 months (23–114)	Complete ablation in 23 cases (92%), in 5 requiring more than one session	In 10/14 symptomatic patients, symptoms disappeared after treatment; in 2/14 the discomfort was mild, tolerated well without any treatment; in 1 case the residual vital tissue was resected	14 adverse events in 10 patients including abdominal pain, indirect hyperbilirubinemia, fever, anemia, and ascites, which were managed conservatively
Rhim H	2007	RFA (US-guided)	17.5 months (2–35)	Complete ablation; no recurrence	n.a	No complications
Cui Y	2003	RFA (US-guided)	21.5 ± 12.5 months (9–34)	One patient treated in a single session; the others required more sessions (2–7) to achieve complete ablation	In 9 patients symptoms were ameliorated, in 7 patients symptoms disappeared or were significantly reduced for a mean of 2 months (range 1–4 months)	No complications

MWA microwave ablation, RFA radiofrequency ablation, HCA hepatocellular adenoma, HH hepatic hemangioma, FNH focal nodular hyperplasia, US ultrasounds, CT computed tomography, ARDS acute respiratory distress syndrome

overlapped ablation and subsequent arterial embolization with absorbable gelatin sponge. Van Vledder et al. described two main complications related to the procedure (class D as defined by the Society of Interventional Radiology (SIR) classification system): in a patient who underwent an open RFA with persistent oval foramen and consequent cerebral ischemia, and in another patient who developed an hepatic abscess in the site of ethanol injection performed after percutaneous RFA for two HCAs [10].

Hemangioma

Patient characteristics

In all the 17 studies, reviewed diagnosis of HH was confirmed by imaging based on the typical enhancement pattern on contrast-enhanced CT, MR or contrast-enhanced ultrasound (CEUS). In one study by Wang et al., preprocedural blood tests were performed to exclude malignant neoplasm (AFP, CEA and CA19-9) [15]. Indication to resort to ablative percutaneous strategies were mostly homogeneous among the considered studies, including the presence of “large/giant” HH associated to persistent-related symptoms in patients refusing open or laparoscopic surgical resection. Only discrepancy, though minor, was found in the definition for “large” HHs. Specifically, both Liu and Ziemlewick considered for treatment lesions greater than 4 cm, while all other studies referred to a cut-off of 5 cm [16, 17]. Reported symptoms included abdominal pain or distension, anemia, portal hypertension, obstructive jaundice, coagulopathy (Kasabach–Merritt syndrome) or serious psychological effects consequent to the diagnosis. Also, most of the authors considered the tendency to enlarge of an imaging proved HH as an inclusion criterion (more than 0.5 cm within one year; more than 1 cm after 2-year follow-up). Most common exclusion criteria comprised the presence of severe blood coagulation dysfunction, active inflammation or infection in any organ, acute or severe renal failure and cardio-pulmonary insufficiency. A distance lesser than 0.5 cm between the HH and hollow viscera (especially the gastrointestinal tract and gallbladder) and, by extension, large subcapsular HHs, were in some of the studies included among the reasons for surgery.

Ablation procedures

Percutaneous RFA or MWA were used for all patients under US, CT or combined guidance.

Ji and colleagues [18] evaluated the feasibility and efficacy of *transarterial* embolization (TAE) combined with subsequent CT-guided RFA in the treatment of HHs larger than 10 cm. The authors found that TAE may facilitate the

ablation by reducing the vascular supply and the volume of the lesion.

Both Wang and Gao in their series compared CT-guided percutaneous RFA to RFA via laparoscopy, with the latter author using US as intra-surgical guidance for ablation.

Tang and colleagues compared different surgical techniques, both laparotomic and laparoscopic, with percutaneous MWA [19–22].

A 3D visualization operative planning system revealed to be a valuable tool in providing detailed anatomical data and, therefore, individualized therapy for HHs by US-guided MWA [23].

In 4 out of 17 studies, authors performed preprocedural peritoneal saline infusion (hydrodissection) to provide a satisfactory sonographic window and to protect nontarget structures (diaphragm, abdominal wall, colon, gallbladder) while ablating lesions abutting the Glisson capsule or the diaphragm [15, 17, 23–25].

Procedural time varies among the series and in accordance to the specific percutaneous ablation techniques proposed, ranging from 11,6 to 117 min. Significant shorter procedural time was observed for percutaneous MWA ($22,40 \pm 8,45$ min) compared to percutaneous RFA techniques ($74,64 \pm 29,87$ min). However, ablation time varied conspicuously within each series depending on the size of the treated lesion.

Procedural and clinical outcomes

While no technical failure was reported among the studies evaluated, procedure effectiveness rate varied with the specific ablation technique considered. Li and Wang, which used MW energy under US guidance, reported a rate of complete tumoral ablation of 95.9% and 84.6%, respectively [19, 23]. In the study by Liu F and colleagues the mean tumoral volume shrinkage rate was 59.67% within three days after US-guided MW ablation [16]. A complete ablation rate of 93.3% after combined application of percutaneous RF and TAE was reported by Ji et al. in their retrospective series [18]. In the comparison of percutaneous MWA and surgical resection described by Tang and colleagues no statistically significant difference in effectiveness was noted between the two groups (p 0.58), with the latter entailing higher hospitalization length and overall worse patient performance [26]. Despite the differences in the follow-up times and protocols, the majority of the studies reported an overall clinical effectiveness of the procedures, with pain relief or improvement of symptoms. In the 2014 study by Ziemlewicz et al., pain score evaluated on the visual analogue scale at 1- to 6-month follow-up decreased from an average of 4.6–0.9 (p 0.05), with patients able to return to their pre-procedure level of activity within a week after percutaneous MWA [17].

Complications

Wang and Cheng described the development of post-ablation systemic inflammatory response (SIR) in 50% and 75.7% of patients, respectively, within two days after intervention [14, 19]. Wang and colleagues reported low fever, constipation, slight wound pain, stomach discomfort and other MWA minor postoperative reactions in 11 out of 12 treated patients [15]. Transient and rapidly resolving liver dysfunction, manifesting as elevation of serum alanine transaminase and aspartate transaminase (> 80 U/L) and jaundice do to indirect hyperbilirubinemia over 3 mg/dl were described in three studies [18, 23, 25]. Acute kidney insufficiency (AKI) was an infrequent complication among the studies considered. Notably, Li et al. [24] investigated the risks factors for hemoglobinuria following liver ablation, including both malignant (primary or metastatic) and benign tumors; they showed that 17 out of 57 patients (29.8%) diagnosed with HHs and treated via MWA developed haemoglobinuria, which was higher than the incidence in primary liver cancer (5.4%) and in metastatic disease cases (3.3%). Moreover, the only patient who progressed to acute renal failure was diagnosed with HH.

Minor chest and abdominal complications, such as transient pleural effusion and ascites, were not uncommon among the selected articles.

Gao and colleagues described two cases of post-ablative diaphragmatic rupture (grade III of Clavien–Dindo classification), while Tang and colleagues reported the development of diaphragmatic hernia in one patient [22, 26].

Apparently no permanent sequelae or other severe complications, including abscesses, major bile duct injury, gastrointestinal tract perforation and hemorrhage requiring surgery or embolization, did occur in the periprocedural and follow-up periods.

Other histologies

A few studies [14, 24, 27] dealt with the percutaneous ablation of BLTs different from HHs and HCAs. These series were mostly heterogeneous in terms of tumor histology and treatment strategy.

Yang and colleagues [27] treated 92 hepatic angiomyolipomas; 22 lesions were approached using US-guided RFA after biopsy in case of tumor size less than 5 cm and lesions highly suspected for angiomyolipomas after imaging evaluation. No major complications were reported.

MWA under US guidance was employed by Cheng et al. [14] to treat diverse BLT subtypes, including 5 FNHs, 6 inflammatory pseudotumors, 5 solitary necrotic nodules, 3 angiomyolipomas, and 1 epithelioid hemangioendothelioma. The patients selected to undergo ablation had an indeterminate diagnosis on the basis of imaging features, an enlarging

benign nodule (greater than 1 cm within one year); were at risk of malignant evolution; had symptoms supposed to be associated with the BFL presence; or heavy psychological pressure for the detection of an hepatic neoplasm, despite a definite diagnosis of a benign condition. Biopsy was routinely performed prior to ablation, and, in case of nodules that were indeterminate for malignancy, the ablation volume included 5–10 mm of normal liver tissue surrounding the target lesion. Residual disease was found in one FNH, completely re-treated with a second ablative session for rapid tumor growth. No major complications were registered.

In their aforementioned work, Li et al. [24] investigated the risks factors for hemoglobinuria following liver ablation, including both malignant and benign tumors, the latter including FNH cases.

Discussion

Adenoma

HCA is a rare solid BLT with a prevalence reported between 0.001 and 0.004%, being more commonly encountered in females of childbearing age [2]. Use of oral contraceptives, anabolic steroids and glycogen storage disease are known factors associated with the onset of this subtype of BLT. The risk of hemorrhage, rupture and malignant transformation into hepatocellular carcinoma, particularly in the β -catenin-mutated subtype, makes recognition and management crucial [28]. A systematic review has reported an overall risk of rupture and subsequent hemorrhage of 27.2% among patients, and 15.8% of HCA lesions [29]. Even though the risk of malignant change seems rarer (4.2%) [6], this is a serious complication which cannot be neglected.

Several approaches are available for the management of HCAs. A conservative strategy using imaging follow-up is preferred for smaller HCAs with a low risk of hemorrhage [30]. Albeit surgical resection is considered the standard treatment reserved for tumors greater than 5 cm, due to concerns about surgical morbidity and prolonged recovery time there is interest in treating these benign lesions with percutaneous ablation [30]. Several studies have, therefore, described the successful application of minimally invasive strategies in the treatment of HCAs [9–13].

Beyond the lesion size, other baseline diagnostic imaging features are relevant, as an exophytic protrusion may warn against the risk of rupture [2]. Conservative management generally consists in imaging follow-up and lifestyle change, and is recommended in women with single or multiple HCA < 5 cm [31]. Surgery instead is required in male patients regardless of tumor dimension due to the risk of malignant transformation, and is recommended in women

with nodules with diameter > 5 cm [32]. It should be recalled that surgery for HCAs is not devoid of risks: Dokmak et al. reported a post-surgical major complications rate of 15%, with need for blood transfusions in 13% of patients [32]. No cases of death or malignant mutation over a median follow-up of 70 months were, however, registered [32].

It is now well established that the initial management should be as conservative as possible, and aggressive management should be selectively limited to HCAs at early risk of complications [32, 33]. Data collected on the results of minimally invasive treatments for HCAs are limited, but the current evidence demonstrates a primary efficacy rate ranging from 58 to 100% [9–13]. The local technical failure rate seems to be proportional to the increasing lesion size: RFA of 45 HCAs with median size of 3.0 cm (range, 0.8–7.3 cm) resulted in a relatively low primary efficacy rate of 58% [10]. Van Vledder and colleagues have hypothesized that, in addition to the larger tumor size, the lack of cirrhosis and tumor capsule could also contribute to the lower effectiveness of RFA [10]. On the contrary, the good results of ablation using MWA technology could be justified by the greater volume of necrosis produced, by the relative insensitivity to the properties of the background tissue, and to the greater ability to overcome the macro and micro-perfusion conditions [7, 13].

Percutaneous procedures for HCA treatment are generally safe, and few complications have been reported. However, the limit of such studies is that a comparison with surgical or conservative techniques could not be made, in terms of safety and efficacy, for the lack of a comparison arm. Future research on larger cohorts is warranted to explore the advantages of minimally invasive techniques compared with conservative and surgical approach.

Although further studies are still necessary, we suggest that thermal ablation for HCAs should be recommended in selected patients, particularly for poor surgical candidates and in smaller tumors (< 5 cm), in patients who would require otherwise large liver resections, or in which complete surgical removal would not be achievable given the multiplicity of HCAs.

Hemangioma

HH is the commonest benign tumor in human liver, with a reported incidence rate of 3–20% in the general population and of 0.4%–7.3% at autopsy [34, 35]. The pathogenesis of HH is poorly understood, possibly reflecting hormonal congenital disorders [2]. HHs may have the tendency to enlarge over the time, probably due to progressive vascular ectasia rather than true neoplastic proliferation or neovascularization [36]. Usually detected incidentally during abdominal imaging performed for other indications, the vast majority of HHs are asymptomatic lesions with no need for clinical intervention. HH are frequently

small (< 4 cm) and solitary, although “giant” lesions may reach 10 cm or more in diameter [2]. “Large” (> 4–5 cm) and especially “giant” HH may sometimes be symptomatic, with pain and bowel discomfort being the most frequently complained symptoms. SIR and coagulopathy such as Kasabach–Merritt syndrome (KMS) represent rarer manifestations [37]. Although no clear consensus has been reached regarding which kind of lesion may be susceptible of treatment, therapeutic approach is usually proposed for tumors that are significantly growing, causing abdominal symptoms or entailing high risk of spontaneous or traumatic rupture. A wide spectrum of treatment strategies for HHs have been suggested over time. Surgical resection and tumor enucleation are used to be the first choices for enlarging and symptomatic cases. Although surgery can achieve complete removal of the tumor, this invasive approach involves relatively long hospitalization and periprocedural morbidity and mortality reported up to 31.5% and 3%, respectively [38, 39]. Furthermore, there is no clear established consensus, either on general management or on the most appropriate timing to resort to elective surgery, and decision-making is often based on the experience of the individual physician and local production volume. In recent years, imaging guided minimally invasive approaches have been proposed for the treatment of benign liver lesions, including TAE, radiation therapy and different ablation techniques involving various types of energy delivery systems. Both RFA and MWA have been performed during laparoscopy or percutaneously under CT or US guidance. Compared with other therapies, percutaneous ablation techniques have been increasingly used for the treatment of HHs, having the unique advantages of minimal invasiveness, low cost and incidence of complications, short hospitalization length and increased patient compliance. However, to the best of authors’ knowledge, only one consensus attempt was made concerning the application of percutaneous ablative techniques in the treatment of these lesions, however, limited to RFA application. TAE and radiation therapy have not been considered curative therapies for HHs because of their poor results and serious complications, although TAE has been considered to manage the KMS, as well as medical therapy with corticosteroids or vincristine [37, 40]. Therefore, ablation therapies are a safe, feasible, and effective approach to HHs, even for greater lesions.

Other histologies

FNH is a relatively frequent benign condition of the liver, representing the second most common solid BLT with an estimated prevalence of 1% [1, 41]. FNH is considered a hyperplastic reaction originating from an arterial malformation, and no instances of malignant transformation have

been reported in the literature [42]. Most cases are incidentally discovered in asymptomatic subjects; however, albeit rarely in patients with large nodules or close to surrounding structures abdominal pain or discomfort might be reported.

There is insufficient evidence to support or refute ablation therapies for FNH, given that reassurance regarding the stable nature of the lesion and the lack of complications is given to patients and constitutes the only suggested management strategy in most cases [1, 2]. Moreover, the correlation between the presence of FNH and symptoms is poor, and treatment is rarely indicated even in symptomatic subjects [2], limiting the choice to treat only for exceptional cases [14]. At present, there are no published randomized controlled trials comparing the outcomes of TAE or RFA with those of either surgery or conservative management.

Hepatic angiomyolipomas are rare mesenchymal neoplasms which most commonly arise in the kidney and only sporadically develop in the liver parenchyma. They may present as solitary mass or as multiple lesions when associated with tuberous sclerosis and entail a very small malignant potential [1, 27, 42]. Liver biopsy is warranted in most patients presenting with lesions suspected for angiomyolipomas, since imaging may be inconclusive due to the rarity of the condition and the frequent resemblance to HCA and hepatic carcinoma, especially when the fat component is small or unapparent [1, 5]. Conservative management is generally recommended for asymptomatic patients who agree with follow-up strategy, whereas surgery is reserved for larger nodules (greater than 5 cm). RFA may be a valid alternative in certain cases, since it has shown to be safe and effective in the treatment of smaller lesions; in most of these patients with small angiomyolipomas, the drive behind the choice of a different approach was psychological pressure and consequent strong wish to intervene [27].

Conclusion and outlook

With widespread use of advanced imaging techniques, the incidental detection of solid BLTs is constantly increasing, thus the physician is more frequently faced with the decision regarding the management of such conditions. Imaging is crucial in the precise definition of histology and natural history of the tumor.

The advent of ablative techniques has widened the range of treatment options available to these patients, if conservative approach is not viable and the patient is not eligible for surgery. The advantages of ablative procedures compared to extirpative surgery include reduced morbidity and faster recovery time. Although image-guided percutaneous ablation methods have proved to be safe and effective for treatment of benign liver lesions in selected cases, the current evidence is insufficient to make a recommendation, and

the decision to pursue ablation rather than surgery requires careful consideration: percutaneous ablation may be considered a valid alternative in patients who are poor surgical candidates for comorbidities or multiple lesions, who have smaller tumors, BLT-related symptoms or are at risk of complications, or for those who desire to intervene despite the reassurance by the physician regarding the benign origin and stable natural history of the tumor.

Author contributions FB, AC: Material preparation, data collection and analysis were performed. AC, GCP: The first draft of the manuscript was written. AC, GCP, AMI, GC, and MG: Critically revised the manuscript and supervised the project. All authors contributed to the study conception, design, read and approved the final manuscript.

Funding This research received no specific grant from any funding agency in the public, commercial or not-for-profit sectors.

Compliance with ethical standards

Conflict of interest None.

References

- Belghiti J, Cauchy F, Paradis V, Vilgrain V. Diagnosis and management of solid benign liver lesions. *Nat Rev Gastroenterol Hepatol*. 2014;11:737–49.
- Colombo M, Forner A, Ijzermans J, Paradis V, Reeves H, Vilgrain V, et al. EASL clinical practice guidelines on the management of benign liver tumours. *J Hepatol*. 2016;65:386–98.
- Kim Y, Amini N, He J, Margonis GA, Weiss M, Wolfgang CL, et al. National trends in the use of surgery for benign hepatic tumors in the United States. *Surg Mosby Inc.*; 2015;157:1055–64.
- Fodor M, Primavesi F, Braunwarth E, Cardini B, Resch T, Bale R, et al. Indications for liver surgery in benign tumours. *Eur Surg—Acta Chir Austriaca*. 2018;50:125–31.
- Grazioli L, Ambrosini R, Frittoli B, Grazioli M, Morone M. Primary benign liver lesions. *Eur J Radiol Elsevier Ireland Ltd*. 2017;95:378–98.
- Stoot JHMB, Coelen RJS, De Jong MC, Dejong CHC. Malignant transformation of hepatocellular adenomas into hepatocellular carcinomas: a systematic review including more than 1600 adenoma cases. *HPB (Oxford)*. 2010;12:509–22.
- Seror O. Percutaneous hepatic ablation: what needs to be known in 2014. *Diagn Interv Imaging*. 2014;95:665–75.
- Moher D, Liberati A, Tetzlaff J, Altman DG. Preferred reporting items for systematic reviews and meta-analyses: the PRISMA statement. *Int J Surg*. 2010;8:336–41.
- Rhim H, Lim HK, Kim Y, Choi D. Percutaneous radiofrequency ablation of hepatocellular adenoma: Initial experience in 10 patients. *J Gastroenterol Hepatol*. 2008;23:e422–e427427.
- Van Vledder MG, Van Aalten SM, Terkivatan T, De Man RA, Leertouwer T, Ijzermans JNM. Safety and efficacy of radiofrequency ablation for hepatocellular adenoma. *J Vasc Interv Radiol*. 2011;22:787–93.
- Costa AF, Kajal D, Pereira A, Atri M. Should fat in the radiofrequency ablation zone of hepatocellular adenomas raise suspicion for residual tumour? *Eur Radiol*. 2017;27:1704–12.
- Mironov O, Jaber A, Beecroft R, Kachura JR. Retrospective single-arm cohort study of patients with hepatocellular adenomas treated with percutaneous thermal ablation. *Cardiovasc Intervent Radiol*. 2018;41:935–41.
- Smolock AR, Cristescu MM, Potretzke TA, Ziemlewicz TJ, Lubner MG, Hinshaw JL, et al. Microwave ablation for the treatment of hepatic adenomas. *J Vasc Interv Radiol*. 2016;27:244–9.
- Cheng Z, Liang P, Yu X, Han Z, Liu F, Yu J, et al. Percutaneous microwave ablation for benign focal liver lesions: initial clinical results. *Oncol Lett*. 2017;13:429–34.
- Wang Z, Tang X, Qi X, Shi Y, Chi J, Li P, et al. Feasibility, safety, and efficacy of ultrasound-guided percutaneous microwave ablation for giant hepatic hemangioma. *Int J Hypertherm Taylor & Francis*. 2018;35:246–52.
- Liu F, Yu X, Liang P, Cheng Z, Han Z, Yu J. Ultrasonography-guided percutaneous microwave ablation for large hepatic cavernous haemangiomas. *Int J Hypertherm Informa UK Ltd*. 2018;34:1061–6.
- Ziemlewicz TJ, Wells SA, Lubner MA, Musat AI, Hinshaw JL, Cohn AR, et al. Microwave ablation of giant hepatic cavernous hemangiomas. *Cardiovasc Intervent Radiol*. 2014;37:1299–305.
- Ji J, Gao J, Zhao L, Tu J, Song J, Sun W. Computed tomography-guided radiofrequency ablation following transcatheter arterial embolization in treatment of large hepatic hemangiomas. *Med (United States)*. 2016;95:1–5.
- Wang S, Yang M, Yang X, Xu L, Ke S, Ding X, et al. Endothelial pyroptosis underlies systemic inflammatory response following radiofrequency ablation of hepatic hemangiomas. *Scand J Clin Lab Invest*. 2019;79:619–28.
- Gao J, Ding X, Ke S, Xin Z, Ning C, Sha Q, et al. Radiofrequency ablation in the treatment of large hepatic hemangiomas: a comparison of multitined and internally cooled electrodes. *J Clin Gastroenterol*. 2014;48:540–7.
- Gao J, Ke S, Ding XM, Zhou YM, Qian XJ, Sun WB. Radiofrequency ablation for large hepatic hemangiomas: Initial experience and lessons. *Surg (United States)*. 2013;153:78–85.
- Gao J, Kong J, Ding XM, Ke S, Niu HG, Xin ZH, et al. Laparoscopic vs computerized tomography-guided radiofrequency ablation for large hepatic hemangiomas abutting the diaphragm. *World J Gastroenterol*. 2015;21:5941–9.
- Li X, An C, Liu F, Cheng Z, Han Z, Yu X, et al. The value of 3D visualization operative planning system in ultrasound-guided percutaneous microwave ablation for large hepatic hemangiomas: a clinical comparative study. *BMC Cancer BMC Cancer*. 2019;19:1–9.
- Li D, Yu J, Han Z, Cheng Z, Liu F, Dou J, et al. Risk factors of haemoglobinuria after microwave ablation of liver tumours. *Clin Radiol*. 2018;73:982.e9–982.e15.
- Park SY, Tak WY, Jung MK, Jeon SW, Cho CM, Kweon YO, et al. Symptomatic-enlarging hepatic hemangiomas are effectively treated by percutaneous ultrasonography-guided radiofrequency ablation. *J Hepatol*. 2011;54:559–65.
- Tang X, Ding M, Lu B, Chi J, Wang T, Shi Y, et al. Outcomes of ultrasound-guided percutaneous microwave ablation versus surgical resection for symptomatic large hepatic hemangiomas. *Int J Hyperthermia Taylor & Francis*. 2019;36:632–9.
- Yang X, Lei C, Qiu Y, Shen S, Lu C, Yan L, et al. Selecting a suitable surgical treatment for hepatic angiomyolipoma: a retrospective analysis of 92 cases. *ANZ J Surg*. 2018;88:E664–E66969.
- Pilati C, Letouzé E, Nault J-C, Imbeaud S, Boulai A, Calderaro J, et al. Genomic profiling of hepatocellular adenomas reveals recurrent FRK-activating mutations and the mechanisms of malignant transformation. *Cancer Cell*. 2014;25:428–41.
- Van Aalten SM, De Man RA, Ijzermans JNM, Terkivatan T. Systematic review of haemorrhage and rupture of hepatocellular adenomas. *Br J Surg*. 2012;99:911–6.

30. Agrawal S, Agarwal S, Arnason T, Saini S, Belghiti J. Management of hepatocellular adenoma: recent advances. *Clin Gastroenterol Hepatol*. 2015;13:1221–300.
31. Dokmak S, Cauchy F, Belghiti J. Resection, transplantation and local regional therapies for liver adenomas. *Expert Rev Gastroenterol Hepatol*. 2014;8:803–10.
32. Dokmak S, Paradis V, Vilgrain V, Sauvanet A, Farges O, Valla D, et al. A single-center surgical experience of 122 patients with single and multiple hepatocellular adenomas. *Gastroenterology*. 2009;137:1698–705.
33. van Aalten SM, Terkivatan T, de Man RA, van der Windt DJ, Kok NFM, Dwarkasing R, et al. Diagnosis and treatment of hepatocellular adenoma in the Netherlands: similarities and differences. *Dig Surg*. 2010;27:61–7.
34. Benign tumors of the liver—PubMed.
35. Toro A, Mahfouz A-E, Ardiri A, Malaguarnera M, Malaguarnera G, Loria F, et al. What is changing in indications and treatment of hepatic hemangiomas: a review. *Ann Hepatol*. 2014;13:327–39.
36. Trastek VF, van Heerden JA, Sheedy PF, Adson MA. Cavernous hemangiomas of the liver: resect or observe? *Am J Surg*. 1983;145:49–53.
37. Hall GW. Kasabach-Merritt syndrome: pathogenesis and management. *Br. J. Haematol*. 2001. 112:851–62.
38. Miura JT, Amini A, Schmocker R, Nichols S, Sukato D, Winslow ER, et al. Surgical management of hepatic hemangiomas: a multi-institutional experience. *HPB*. 2014;16:924–8.
39. Zhang W, Huang ZY, Ke CS, Wu C, Zhang ZW, Zhang BX, et al. Surgical Treatment of Giant Liver Hemangioma Larger Than 10cm: A Single Center's Experience with 86 Patients. *Med (United States)*. Lippincott Williams and Wilkins; 2015;94:e1420.
40. O'Rafferty C, O'Regan GM, Irvine AD, Smith OP. Recent advances in the pathobiology and management of Kasabach-Merritt phenomenon. *Br J Haematol*. 2015;171:38–51.
41. Navarro AP, Gomez D, Lamb CM, Brooks A, Cameron IC. Focal nodular hyperplasia: a review of current indications for and outcomes of hepatic resection. *HPB*. 2014;16:503–11.
42. Zhou YM, Li B, Xu F, Wang B, Li DQ, Zhang XF, et al. Clinical features of hepatic angiomyolipoma. *Hepatobiliary Pancreat Dis Int*. 2008;7:284–7.

Publisher's Note Springer Nature remains neutral with regard to jurisdictional claims in published maps and institutional affiliations.