European Heart Journal (2017) **38**, 1895–1904
doi:10.1093/eurheartj/ehx043

CLINICAL RESEARCH
Heart failure/cardiomyopathy

Clinical characteristics of wild-type transthyretin cardiac amyloidosis: disproving myths

Esther González-López[1,2,3], Christian Gagliardi[4], Fernando Dominguez[1,3], Cristina Candida Quarta[4], F. Javier de Haro-del Moral[5], Agnese Milandri[4], Clara Salas[3,6], Mario Cinelli[4], Marta Cobo-Marcos[1,3], Massimiliano Lorenzini[4], Enrique Lara-Pezzi[2,3], Serena Foffi[4], Luis Alonso-Pulpon[1,3], Claudio Rapezzi[4], and Pablo Garcia-Pavia[1,3,7]*

[1]Heart Failure and Inherited Cardiac Diseases Unit, Department of Cardiology, Hospital Universitario Puerta de Hierro, Madrid, Spain; [2]Myocardial Biology Programme, Centro Nacional de Investigaciones Cardiovasculares (CNIC), Madrid, Spain; [3]Centro de Investigación Biomédica en Red en Enfermedades Cardiovasculares (CIBERCV); [4]Institute of Cardiology, University of Bologna and S Orsola-Malpighi Hospital, Bologna, Italy; [5]Department of Nuclear Medicine, Hospital Universitario Puerta de Hierro, Madrid, Spain; [6]Department of Pathology, Hospital Universitario Puerta de Hierro, Madrid, Spain; and [7]Medical School, Francisco de Vitoria University, Madrid, Spain

Received 18 July 2016; revised 22 October 2016; editorial decision 20 January 2017; accepted 24 January 2017; online publish-ahead-of-print 1 March 2017

See page 1909 for the editorial comment on this article (doi: 10.1093/eurheartj/ehx210)

Aims Wild-type transthyretin amyloidosis (ATTRwt) is mostly considered a disease predominantly of elderly male, characterized by concentric LV hypertrophy, preserved LVEF, and low QRS voltages. We sought to describe the characteristics of a large cohort of ATTRwt patients to better define the disease.

Methods and results Clinical findings of consecutive ATTRwt patients diagnosed at 2 centres were reviewed. ATTRwt was diagnosed histologically or non-invasively (LV hypertrophy ≥12 mm, intense cardiac uptake at ^{99m}Tc-DPD scintigraphy and AL exclusion). Mutations in TTR were excluded in all cases. The study cohort comprised 108 patients (78.6 ± 8 years); 67 (62%) diagnosed invasively and 41 (38%) non-invasively. Twenty patients (19%) were females. An asymmetric hypertrophy pattern was observed in 25 (23%) patients. Mean LVEF was 52 ± 14%, with 39 patients (37%) showing a LVEF < 50%. Atrial fibrillation (56%) and a pseudo-infarct pattern (63%) were the commonest ECG findings. Only 22 patients fulfilled QRS low-voltage criteria while 10 showed LV hypertrophy on ECG. Although heart failure was the most frequent profile leading to diagnosis (68%), 7% of individuals presented with atrioventricular block and 11% were diagnosed incidentally. Almost one third (35; 32%) were previously misdiagnosed.

Conclusion The clinical spectrum of ATTRwt is heterogeneous and differs from the classic phenotype: women are affected in a significant proportion; asymmetric LV hypertrophy and impaired LVEF are not rare and only a minority have low QRS voltages. Clinicians should be aware of the broad clinical spectrum of ATTRwt to correctly identify an entity for which a number of disease-modifying treatments are under investigation.

Keywords Cardiac amyloidosis • Transthyretin • Wild-type • 99mTc-DPD • Scintigraphy

Introduction

Small amyloid deposits of structurally unstable transthyretin (TTR) fibrils have been found in autopsies of 14 to 25% of elderly individuals depending on patient selection and amyloid detection methodology employed.[1,2] When wild-type TTR (TTRwt) is deposited in greater amounts in the heart leading to clinical manifestation, wild-type transthyretin amyloidosis (ATTRwt), also known as senile systemic amyloidosis, is said to be present.[3]

In contrast to other forms of amyloidosis, ATTRwt almost exclusively affects the heart, with the exception of carpal tunnel syndrome (CTS)[3,4] and lumbar spinal canal stenosis.[5] Patients affected by ATTRwt can suffer from heart failure (HF), arrhythmias[6] and other common cardiac manifestations including angina.[3,4] The first series of

* Corresponding author. Tel: +34 911917297, Fax: +34 911917718, Email: pablogpavia@yahoo.es
Published on behalf of the European Society of Cardiology. All rights reserved. © The Author 2017. For permissions, please email: journals.permissions@oup.com.

Downloaded from https://academic.oup.com/eurheartj/article-abstract/38/24/1895/3059372 by biblioteca biomedica centrale universita di bologna user on 18 February 2020

ATTRwt with clinical manifestations was published in 1987.[7] Since then, however, studies describing the natural history and clinical characteristics of the condition have been few and included limited number of patients, from a small number of referral centres.[8,9]

Based on the available case series, ATTRwt has been traditionally considered a remarkably sex-specific disease[3,4] with a very strong male predominance affecting only patients over 60 years old.[3,4] The accepted ATTRwt clinical phenotype also includes concentric left ventricle (LV) hypertrophy, preserved left ventricular ejection fraction (LVEF)[3,4,9] and normal or low QRS voltages on ECG.[3,4]

Although the demonstration of TTR amyloid deposits on endomyocardial biopsy (EMB) plus the absence of mutations in the TTR gene remains the gold standard for the diagnosis of ATTRwt,[3,4] in recent years, cardiac magnetic resonance (CMR) has been shown to be helpful in the work-up for cardiac amyloidosis[10] and scintigraphy with diphosphonate agents has been proven very useful in identifying patients with cardiac amyloidosis.[10,11] Furthermore, non-invasive diagnostic criteria for cardiac ATTR amyloidosis based on technetium-labelled bone scintigraphy and absence of a monoclonal protein in serum or urine have been proposed very recently.[12]

Although the true prevalence of ATTRwt in the general population remains unknown,[4] we are witnessing a significant increase in the number of referred patients with the suspicion of ATTRwt and several recent reports suggest that ATTRwt could be the most frequent form of cardiac amyloidosis.[4,13,14]

The need for a better delineation of ATTRwt clinical characteristics is stressed by the fact that diagnosing this disease should lead clinicians to avoid certain drugs and to screen patients for possible complications such as atrial arrhythmias and conduction disorders.[3,4] Furthermore, several new therapies are under development for this condition,[4,15,16] some of which have shown promising preliminary results.[16,17]

In the context that ATTRwt diagnosis has clinical implications and that ATTRwt could soon be treatable, cardiologists should be familiar with the broad clinical spectrum of the disease in order to correctly identify it.

The purpose of this study was to describe the main clinical characteristics of a large cohort of patients with ATTRwt to better define the disease.

Methods

We conducted a descriptive study at two tertiary university hospitals in Bologna (Italy) and Madrid (Spain). Information from prospective local databases and clinical charts of all patients diagnosed with ATTRwt at both centres over a 16-year period (Bologna) and a 6-year period (Madrid) were reviewed.

Study patients

ATTRwt was diagnosed in the presence of (1) cardiac involvement and TTR deposits on tissue biopsy or (2) non-invasively, in the presence of: cardiac involvement defined as maximal left ventricular wall thickness ≥12 mm, intense biventricular uptake (Perugini Score 2–3) on ^{99m}Tc-DPD scintigraphy[18] and AL exclusion by serum and urine protein electrophoresis by immunofixation electrophoresis plus serum free light chain assay.[4,12] In all cases, genetic testing confirmed the absence of mutations in the TTR gene.

Data collection

Demographic and clinical characteristics were collected at admission or at presentation at the outpatient clinic. Age, date of ATTRwt diagnosis and symptoms onset were obtained. The clinical profile leading to ATTRwt diagnosis was recorded as well as the previous diagnosis. Data regarding functional class according to New York Heart Association (NYHA), heart failure signs, admissions due to cardiovascular causes, blood pressure, and treatment at first evaluation were obtained.

Hypertension was defined based on clinical history or use of, at least, one antihypertensive medication at presentation. Coronary artery disease (CAD) was defined by previous history of myocardial infarction or by the presence of at least moderate coronary stenosis by angiography. Left-sided valve disease was defined as the presence of moderate or severe regurgitation or stenosis by echocardiography according to current guidelines. The history of monoclonal gammopathy of undetermined significance (MGUS) or CTS was also collected.

Blood test parameters were collected from the first blood test available. Creatinine clearance was calculated using CKD-EPI formula and NT-proBNP was obtained when available.

Follow-up started at the time of diagnosis of ATTRwt. Information on patient's final status was obtained from medical records or from the primary care physicians. Overall mortality was defined as mortality due to any cause during follow-up. Cardiovascular mortality was considered if death was caused by heart failure, myocardial infarction or stroke. A committee formed by two physicians adjudicated these events. A third physician resolved discrepancies.

ECG

ECG measures were based on standard definitions using the first ECG available when the diagnosis of ATTRwt was made. Low voltage was assessed by limb or precordial criteria (QRS amplitude ≤0.5 mV in all limb leads or ≤1 mV in all precordial leads)[3,10] and Sokolow index (≤1.5 mV).[19,20] Electrocardiograhic LV hypertrophy was evaluated according to Sokolow criteria and voltage-to-mass ratio was calculated as peripheral QRS score divided by indexed LV mass. Ventricular-paced QRS complexes were excluded.

Echocardiography

Chamber and LVEF quantification was based on standard recommendations.[21] Patterns of hypertrophy were defined as previously described.[22] LV mass was evaluated by M-mode and myocardial contraction fraction (MCF) was calculated.[23]

^{99m}Tc-DPD-scintigraphy

^{99m}Tc-DPD-scintigraphy studies were performed and evaluated as described elsewhere.[14,18] The scan was considered positive when it revealed a moderate to severe ^{99m}Tc-DPD uptake (Perugini score 2–3) in both ventricles.[18]

Genotyping

All patients underwent genetic analysis for mutations in TTR gene. The coding regions of the TTR gene were amplified by polymerase chain reaction and amplified DNA fragments were directly sequenced.

Histology

Patients underwent cardiac, abdominal fat or salivary gland biopsies if considered by their treating physicians. Sections from formalin-fixed, paraffin-embedded biopsy specimens were stained with Haematoxylin-Eosin and Congo Red. Immunostaining was performed using the following antibodies: monoclonal antibody directed against AA amyloid, TTR, λ-light chain, and

Downloaded from https://academic.oup.com/eurheartj/article-abstract/38/24/1895/3059372 by biblioteca biomedica centrale universita di bologna user on 18 February 2020

κ-light chain (all from DAKO, Glostrup, Denmark). The specificity of immunostaining was controlled using specimens containing known classes of amyloid. Omission of primary antibodies served as negative controls. Mass spectrometry (MS) proteomic analysis was undertaken in selected cases.

Statistical analysis

Normality was assessed using Shapiro-Wilk test. Normally distributed variables were expressed as mean ± standard deviation while non-normally distributed variables were reported as the median and interquartile range (IQR). Categorical data were reported as frequencies and percentages and were compared using Chi squared or Fisher's exact test. Comparison of continuous variables between two independent groups was performed using unpaired Student's *t*-test (if normally distributed) or Mann–Whitney U-test (non-normally distributed variables) and in cases where more than two groups were compared, one way analysis of variance (ANOVA) or Kruskal–Wallis test was used. Survival was evaluated with Kaplan–Meier curves and hazard ratios were estimated by Cox proportional hazards regression. All tests were 2-tailed and a *P* value of <0.05 was considered to be statistically significant. Statistical analysis was performed using SPSS Statistics (version 22. IBM Corp., Chicago, IL, USA).

Results

During the study period, a total of 108 patients were diagnosed with ATTRwt, 71 at the University of Bologna (Italy) and 37 at Hospital Universitario Puerta de Hierro Majadahonda in Madrid (Spain). The findings from each centre are shown in Supplementary material online, *Table S1*.

^{99m}Tc-DPD scintigraphy and tissue biopsy

ATTRwt was diagnosed by histology coupled with immunohistochemistry/MS in 67 patients (62%). A non-invasive diagnosis was made in 41 (38%) patients. In all cases, mutations in the TTR gene were excluded (*Table 1*).

Among patients with histologically proven ATTRwt, 65 (97%) had undergone EMB and just 2 (3%) showed the presence of amyloid in an extracardiac biopsy.

Except in three cases (all confirmed by EMB), all patients underwent ^{99m}Tc-DPD scintigraphy. In all cases, the scan showed an intense (grade 2–3) biventricular uptake.

Patients diagnosed non-invasively were significantly older at time of symptom onset (82.7 ± 6.4 vs. 74.1 ± 7.2; $P < 0.001$) and diagnosis (84.2 ± 6.1 vs. 75.2 ± 7; $P < 0.001$) than patients diagnosed invasively. Patients diagnosed non-invasively also presented with worse renal function (45 ± 21 vs. 58.6 ± 21 mL/min/1.73 m^2; $P = 0.006$), lower LV mass (179.7 ± 70.6 vs. 216.2 ± 65.3 g/m^2; $P = 0.009$), higher MCF (37.4 vs. 20.5%; $P = 0.047$) and lower proportion of low voltage on ECG by classical criteria (15 vs. 25.4%; $P = 0.05$).

Interestingly, although not statistically significant, patients diagnosed non-invasively showed a shorter interval to diagnosis compared with patients diagnosed invasively [7 months (IQR 1–45) vs. 12 months (IQR 5–35); $P = 0.32$]. Other findings are shown in the Supplementary material online, *Table S2*.

Table 1 Baseline, diagnostic and clinical characteristics of patients with ATTRwt included in the study (*N* = 108)

	Total (*N* = 108)
Baseline characteristics	
Female sex	20 (18.5%)
Age at symptoms onset	77.3 ± 8 [*N* = 104]
Diagnostic characteristics	
Age at diagnosis	78.6 ± 8 [*N* = 107]
Clinical profile leading to diagnosis:	
1. Heart failure/Dyspnoea	73 (67.6%)
2. Atrioventricular block	8 (7.4%)
3. Differential diagnosis LVH	15 (13.9%)
4. Incidental	12 (11.1%)
Previous misdiagnosis:	34 (34%) [*N* = 100]
1. Hypertensive cardiomyopathy	12 (35.3%)[a]
2. HFpEF	3 (8.8%)[a]
3. Hypertrophic cardiomyopathy	8 (23.5%)[a]
4. Restrictive cardiomyopathy	1 (2.9%)[a]
5. Ischaemic heart disease	4 (11.8%)[a]
6. Aortic stenosis	3 (8.8%)[a]
7. Others	3 (8.8%)[a]
Diagnosis made by:	
A. Histology	67 (62%)
1. Endomyocardial biopsy	65 (97%)[b]
2. Extracardial	2 (3%)[b]
B. Non-invasive	41 (38%)
Positive DPD scintigraphy	105 (100%) [*N* = 105]
Clinical characteristics	
Hypertension	59 (54.6%)
Coronary artery disease	14 (13%)
Left-sided valve disease:	10 (9.3%)
A. Moderate aortic regurgitation	1 (10%)[c]
B. Moderate aortic stenosis	2 (20%)[c]
C. Moderate mitral regurgitation	7 (70%)[c]
MGUS	11 (10.2%)
Carpal tunnel syndrome	36 (33.3%)
NYHA	
I	19 (17.6%)
II	54 (50%)
III	34 (31.5%)
IV	1 (0.9%)
Systolic blood pressure (mmHg)	126 ± 19
Diastolic blood pressure (mmHg)	72 ± 12
Heart failure development	88 (81.5%)
Cardiovascular admissions	66 (64%) [*N*=103]
Death	18 (16.7%)
Cardiovascular death	15 (83.3%)[d]
Age at death	81.8 ± 6.5[d]
Treatment at first evaluation	
ACEI/ARB	45 (41.7%)
Beta-blockers	41 (38%)

Continued

Downloaded from https://academic.oup.com/eurheartj/article-abstract/38/24/1895/3059372 by biblioteca biomedica centrale universita di bologna user on 18 February 2020

Table 1 *Continued*

	Total (*N* = 108)
Blood test	
eGFR (mL/min/1.73m^2)	53 ± 22 [*N* = 83]
Median NTproBNP (pg/mL)	2997 (1592–9621)

[a]Based on the number of patients with previous misdiagnosis [*N* = 34].
[b]Based on the number of patients with histological diagnosis [*N* = 67].
[c]Based on the number of patients with left-sided valve disease [*N* = 10].
[d]Based on the number of death patients [*N* = 18].
Data are shown as mean ± SD, median (interquartile range), or *n* (percentage).
LVH, Left ventricular hypertrophy; HFpEF, Heart failure with preserved ejection fraction; MGUS, Monoclonal gammopathy of undetermined significance; NYHA, New York Heart Association Functional Classification; ACEI, Angiotensin-converting enzyme inhibitor; ARB, Angiotensin II receptor blocker; eGFR, estimated Glomerular Filtration Rate.

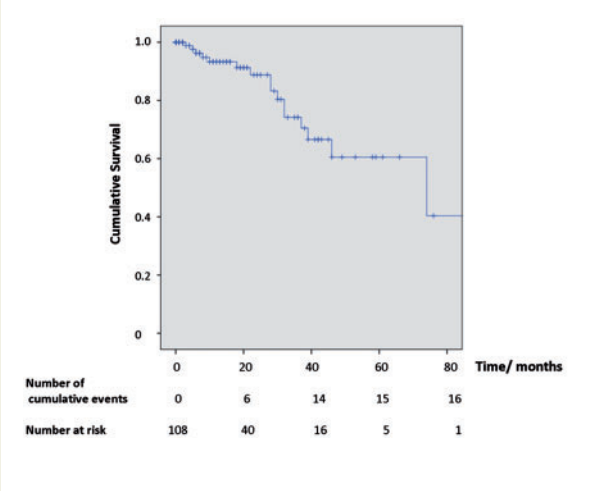

Figure 1 Overall survival of 108 patients with ATTRwt. Overall survival of the cohort was 93% (87–99), 89% (81–97), and 74% (60–88) at 12, 24, and 36 months, respectively.

Clinical features

Basal characteristics

Twenty patients (18.5%) were female. Mean age at symptom onset was 77.3 ± 8 years and mean age at diagnosis was 78.6 ± 8 years.

Interestingly, female patients were significantly older than male patients at time of symptoms' onset (82.3 vs. 76.1; $P = 0.002$) as well as at diagnosis (83.9 vs. 77.4; $P = 0.001$). Women were also diagnosed non-invasively more frequently (75% vs. 29%; $P < 0.001$) and tended to present with a smaller LV cavity size (41 vs. 46 mm; $P = 0.003$), better LVEF (59 vs. 51%; $P = 0.014$), thinner LV ventricles and lower LV mass (158 vs. 212 g/m^2; $P = 0.002$). Findings comparing characteristics according to gender are shown in Supplementary material online, *Table S3*.

Clinical profile leading to diagnosis

The clinical profile leading to ATTRwt diagnosis was heart failure (HF) in 73 cases (68%), including one patient (1%) diagnosed while being treated for cardiogenic shock.

Nevertheless, HF was not the unique presentation leading to diagnosis: 8 patients (7%) presented with symptomatic atrioventricular (AV) block, requiring a pacemaker; in 15 cases (14%), the diagnosis was reached as part of the work-up in the differential diagnosis of left ventricular hypertrophy (LVH), and 12 patients (11%) were diagnosed as an incidental finding after a positive DPD-scan requested for oncologic or rheumatologic reasons (*Table 1*).

Comorbidities

Regarding comorbidities, 59 (55%) patients were previously diagnosed with hypertension, 14 patients (13%) had history of CAD and 10 (9.3%) had moderate left-sided valve disease, mainly mitral regurgitation (70%) (*Table 1*). Thirty-six patients (33%) had CTS and 11 patients (10%) were considered to have MGUS.

Previous misdiagnosis

Thirty-four patients (35%) had been previously misdiagnosed with other cardiac diseases. Among them, 'hypertensive heart disease' was the most common (12 patients) followed by hypertrohic cardiomyopathy (HCM) (8), ischaemic heart disease (4), heart failure with preserved ejection fraction (HFpEF) (3), aortic stenosis (AS) (3), and miscellanea of other diagnosis (4).

Functional status

Among the overall cohort, the majority of patients were considered to be in NYHA functional class II (54; 50%) at diagnosis, while 19 (17.6%) were asymptomatic from a cardiac point of view at first evaluation (*Table 1*). During follow-up, only a 19% of patients of the entire cohort remained free of HF symptoms and 36% did not require admission for HF or other cardiovascular complications.

Table S4 (see Supplementary material online) summarizes the different characteristics according NYHA functional class.

Survival and therapies

During a median follow-up of 13.8 (IQR 4.5–30.5) months after diagnosis, 18 patients died. The majority of them, 15 patients (83%), died due to cardiovascular causes (14 patients (93.3%) due to refractory HF, and 1 patient (6.7%) due to ischaemic stroke), with a mean age of 81.8 ± 6.5 at the time of death. Overall survival at 12, 24 and 36 months was 93% (87–99), 89% (81–97) and 74% (60–88), respectively (*Figure 1*). There was inconclusive evidence that patients with MCF ≥30% had better survival than those with MCF <30% [HR 0.83 (0.29–2.36); $P = 0.73$] and that patients with LVEF <50% had worse survival than those with LVEF ≥50% [HR 1.32 (0.48–3.57); $P = 0.6$].

Mortality was significantly higher in patients who were diagnosed invasively (88.9 vs. 56.7%; $P = 0.015$) and, as expected, it was associated with a higher rate of HF development (100 vs. 77.8%; $P = 0.022$), CV admissions (88.9 vs. 58.8%; $P = 0.016$), worse renal function (40.4 vs. 56.6 mL/min/1.73m^2; $P < 0.001$), and higher NTproBNP values compared with those of survivors (15 617 vs. 2922 pg/mL; $P = 0.012$). Other findings are shown in Supplementary material online, *Table S5*.

In terms of medical therapy, at first evaluation, 45 (42%) patients were receiving ACEI or ARB and 41 (38%) were on beta-blockers.

Downloaded from https://academic.oup.com/eurheartj/article-abstract/38/24/1895/3059372 by biblioteca biomedica centrale universita di bologna user on 18 February 2020

Table 2 ECG and echocardiographic characteristics of patients with ATTRwt included in the study (*N* = 108)

	Total (*N* = 108)
ECG characteristics	
Pacemaker	19 (17.6%)
Atrial fibrillation (any form)	60 (55.6%)
Normal ECG	2 (1.9%)
Sinus rhythm	56 (51.9%)
1st AV block	24 (30.8%)
Low voltage limb/precordial leads	22 (22%)
Sokolow (<15 mm)	47 (48.5%)
RBBB	15 (15%)
LBBB	17 (17%)
QTc (ms)	463 ± 39
LVH	10 (10.5%)
Voltage-to-mass ratio (mV/g/m^2)	0.17 (0.12–0.26)
Pseudoinfarct pattern	60 (63.2%)
Echocardiography	
LVEDD (mm)	45 ± 7
LVESD (mm)	31 ± 9
LVEF (%)	52 ± 14
LVEF < 50%	39 (36.8%)
MCF (%)	30 (21–43)
Septal MWT (mm)	17.5 ± 3
Posterior MWT (mm)	15 ± 3
LVH pattern:	
1. No LVH	1 (0.9%)
2. Symmetric	82 (75.9%)
3. Asymmetric	25 (23.1%)
Left ventricular mass index (g/m^2)	203 ± 69
Mean TD (ms)	180 ± 53
Restrictive filling pattern	35 (35%)
Pericardial effusion	45 (42.1%)

Data are shown as mean ± SD, median (interquartile range), or *n* (percentage). AV, atrioventricular; L/RBBB, Left/Right bundle branch block; LVH, Left ventricular hypertrophy; LVEDD/LVESD, left ventricular end-diastolic/systolic diameter; LVEF, Left ventricular ejection fraction; MCF, Myocardial contraction fraction; MWT, Maximal wall thickness; TD, Early deceleration time.

Other clinical findings and blood test parameters are presented in *Table 1*.

Electrocardiographic characteristics

Sixty subjects (56%) had any form of AF and 19 (17%) had a permanent pacemaker.

Only 22 patients (22%) fulfilled low QRS voltage according to limb and precordial leads criteria, or 48% considering Sokolow index (*Table 2*).

LV hypertrophy on ECG was only present in 10 patients (11%) and median voltage-to-mass was of 0.17 mV/g/m^2 (0.12–0.26). Only 2 patients (both diagnosed incidentally) had a normal ECG. The commonest finding on ECG (60 patients, 63%) was a pseudo-infarct pattern (*Figure 2*).

Echocardiographic characteristics

Mean LVEF was 52 ± 14% with 39 patients (37%) showing a LVEF <50%. Median MCF was 30% (IQR 21–43). Mean maximal septum thickness was 17.5 ± 3 mm. The pattern of hypertrophy was symmetric in 81 individuals (76%) and asymmetric in 25 patients (23%) (*Figure 3*). Only one patient (1%) did not show LV hypertrophy ≥12 mm. This patient was incidentally diagnosed by a positive DPD.

Mean LV mass was 203 ± 69 gr/m^2 and pericardial effusion was present in up to 42% of the patients.

Regarding evaluation of diastolic function, mean early deceleration time was 180 ± 53 ms and only 35% of the patients showed a restrictive filling pattern (*Table 2*).

Discussion

This study describes a large cohort of patients with ATTRwt, including patients diagnosed non-invasively for the first time according to the recently proposed diagnostic criteria.[12] Our study shows that ATTRwt patients can present with a variety of clinical, electrocardiographic and echocardiographic features. Moreover, it demonstrates that some classic features are rare and others are not as rare as traditionally believed. Consequently, our study highlights that in order to correctly diagnose this condition, physicians should not limit their suspicions only to patients who fit the classic clinical phenotype.

Beyond the classic clinical profile

Previous published ATTRwt series have shown a marked male preponderance in ATTRwt with rates of affected males ranging from 89% to 98%[8,9] (*Table 3*). No clear explanations have been proposed to support the apparently increased incidence of ATTRwt among men. Furthermore, male sex-predominance in an age-related disease contrasts with increased life expectancy of women in most countries. In our series, almost 20% of patients were female, which is decidedly higher than the anecdotal rate previously reported in ATTRwt. Women were significantly older at time of symptom onset and diagnosis, they were mainly diagnosed non-invasively and presented with increased LVEF, less thicker LV and lower LV mass. These findings may suggest that female ATTRwt patients present later and with a less aggressive profile compared with ATTRwt male patients.

Our groups have recently published studies on atypical ATTRwt clinical scenarios.[14,24,25] and we have found a high number of female patients, supporting the hypothesis that the proportion of females affected by ATTRwt could have been largely underestimated.

In contrast to previously published series of similar size (*Table 3*), our series included patients with a non-invasive diagnosis, which probably allows identification of individuals that do not fulfil the 'classic' phenotype. Interestingly, although not statistically significant, patients diagnosed non-invasively showed a shorter interval to diagnosis.

Contrary to previous reports, comorbidities were frequently found in our series. These entities might have been underrepresented in previous series from referral centres where patients tend to present with a more classical clinical profile[8,9] (*Table 3*). Special consideration should be made to high blood pressure. Hypertensive heart disease was indeed the most common previous

Downloaded from https://academic.oup.com/eurheartj/article-abstract/38/24/1895/3059372 by biblioteca biomedica centrale universita di bologna user on 18 February 2020

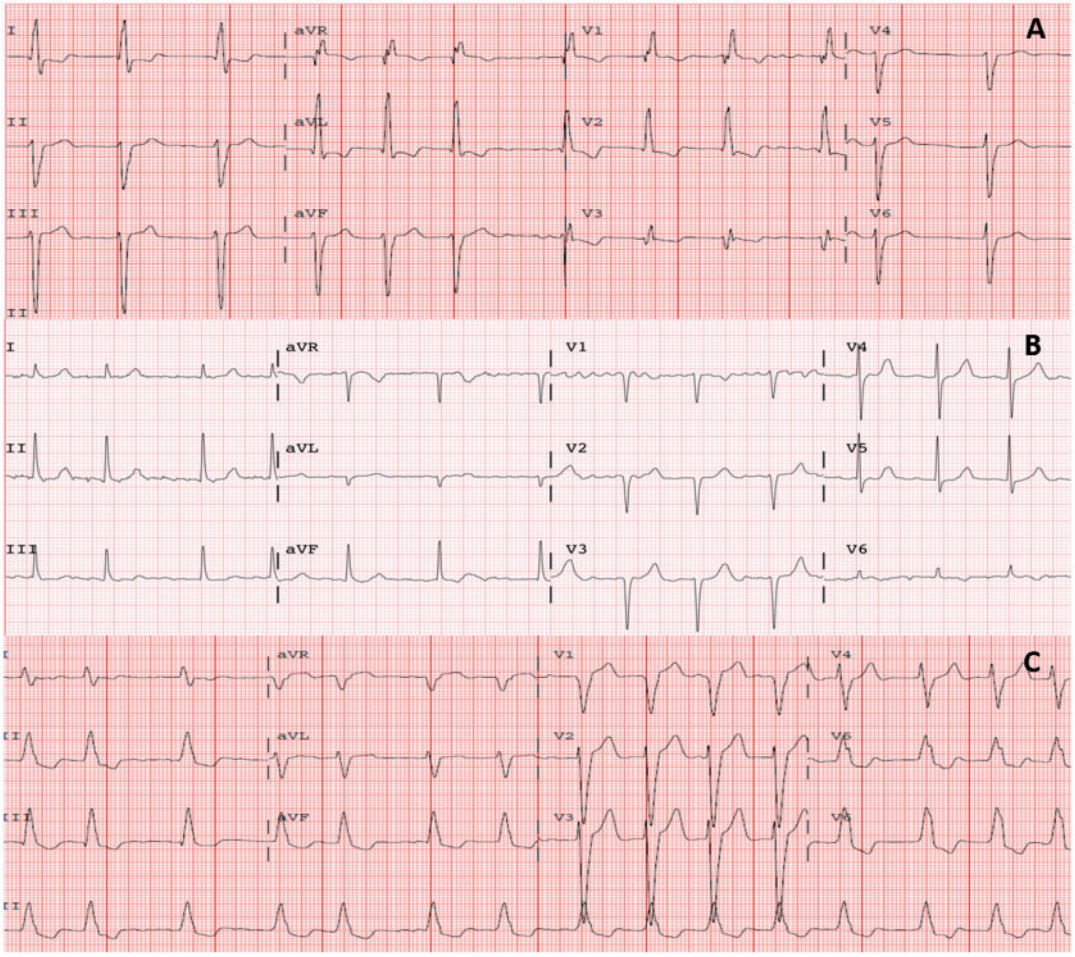

Figure 2 Diversity of ECG patterns in ATTRwt. (*A*) ECG showing right bundle-branch block and fulfilling LVH criteria by Sokolow. (*B*) ECG showing atrial fibrillation and pseudoinfarct pattern in precordial leads. (*C*) ECG showing atrial fibrillation and left bundle-branch block.

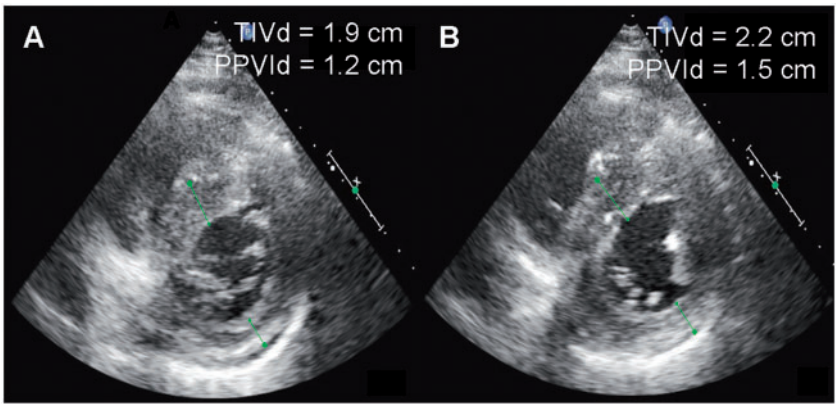

Figure 3 Asymmetric left ventricular hypertrophy. Echocardiographic paraesternal basal (*A*) and mid cavity (*B*) short axis views showing asymmetric LVH with anteroseptal predominance and a trace of posterior pericardial effusion.

Downloaded from https://academic.oup.com/eurheartj/article-abstract/38/24/1895/3059372 by biblioteca biomedica centrale universita di bologna user on 18 February 2020

Table 3 Clinical, analytical, electrocardiographic, and echocardiographic characteristics of published ATTRwt cohorts

	Bologna & Madrid (*N* = 108)	London[8] (*N* = 99)	Boston[9] (*N* = 121)
Baseline characteristics			
Female sex	20 (19%)	11 (11%)	3 (2%)
Age at symptoms onset	78.4 (73.0–82.1)	70.9 (67.7–74.1)	73.5 (58.8–86.6)
Diagnostic characteristics			
Age at diagnosis	79.4 (73.8–84.2)	73 (69.5–78.2)	75.1 (59–87.5)
Clinical profile leading to diagnosis:			
1. HF/Dyspnoea	73 (67.6%)	53 (53.3%)	103 (86%)
2. AVB	8 (7.4%)	NA	NA
3. DD LVH	15 (13.9%)	NA	NA
4. Incidental	12 (11.1%)	8 (8%)	NA
Diagnosis made by:			
A. Histology	67 (62%)	99 (100%)	121 (100%)
1. EMB	65 (97%)[a]	65 (66%)[b]	99 (82%)[c]
2. Extracardial	2 (3%)[a]	34 (34%)[b]	57 (47%)[c]
B. Non-invasive	41 (38%)		
Clinical characteristics			
Hypertension	59 (54.6%)	NA	30 (25%) (119)
CAD	14 (13%)	27 (27%)	33 (31%) (106)
MGUS	11 (10.2%)	22 (24%) (91)	12 (10%) (120)
CTS	36 (33.3%)	48 (48.5%)	56 (46%)
NYHA at presentation			
I	I 19 (17.6%)	I 35 (35%)	≥ II 102 (85%) [N = 120]
II	II 54 (50%)	II 26 (26%)	
II	III 34 (31.5%)	III 25 (25%)	
IV	IV 1 (0.9%)	IV 6 (6%)	
Death	18 (17%)	32 (32%)	68 (56%)
Age at death	81.8 (78.8–82.9)	77 (74–81)	77.9 (64–89.6)
Median survival (years)	6.1	2.71	3.89
Analytical findings			
eGFR (mL/min/1.73 m^2)	51 (36–67) [*N* = 83]	63 (41–69)	
NTproBNP/BNP	NTproBNP (pmol/L): 353.6 (187.9–1135.3)	NTproBNP (pmol/L): 317.5 (212.3–909.3)	BNP (pg/mL): 482 ± 337
ECG characteristics			
Pacemaker	19 (17.6%)	13 (13%)	36 (40%)[d]
AF (any form)	60 (55.6%)	43 (43%)	70 (67%)
SR at first ev	56 (51.9%)	42 (45%)	
1st AV Block	24 (30.8%)	10 (11%)	
Low voltage	22 (22%)	11 (12.9%)	29 (33%)
RBBB	15 (15%)	14 (16%)	
LBBB	17 (17%)	17 (20%)	
QTc	463 ± 39	478.7 ± 53.3	
Echo characteristics			
LVEDD	45 ± 7	44 ± 0.6	44 ± 6
LVESD	31 ± 9	NA	34 ± 6
LVEF	52 ± 14	46.6 ± 12.8	48.1 ± 10.5
Septal MWT	17.5 ± 3	17 ± 3	16.3 ± 3
Posterior MWT	15 ± 3	17 ± 2	16 ± 2.8
LV Mass index	203 ± 69	NA	156.5 ± 42

Continued

Downloaded from https://academic.oup.com/eurheartj/article-abstract/38/24/1895/3059372 by biblioteca biomedica centrale universita di bologna user on 18 February 2020

Table 3 *Continued*

	Bologna & Madrid (*N* = 108)	London[8] (*N* = 99)	Boston[9] (*N* = 121)
DT	180 ± 53	191.2 ± 59.35	NA
Restrictive pattern	35 (35%)	47 (62%)	50 (66%)

[a]Based on the number of patients with histological diagnosis in the Bologna & Madrid cohort [*N* = 67].
[b]Based on the number of patients with histological diagnosis in the London cohort [*N* = 99].
[c]Based on the number of patients with histological diagnosis in the Boston cohort [*N* = 121].
[d]Includes pacemakers and ICDs.
Data are shown as mean ± SD, median (interquartile range), or *n* (percentage).
HF, Heart Failure; AVB, Atrioventricular block; DD LVH, Differential diagnosis of Left ventricular hypertrophy; EMB, Endomyocardial biopsy; CAD, Coronary artery disease; MGUS, Monoclonal gammopathy of undetermined significance; CTS, Carpal Tunnel Syndrome; NYHA, New York Heart Association Functional Classification; eGFR, estimated Glomerular Filtration Rate; AF, Atrial Fibrillation; SR, sinus rhythm; L/RBBB, Left/Right bundle branch block; LVEDD/LVESD, left ventricular end-diastolic/systolic diameter; LVEF, Left ventricular ejection fraction; MWT, Maximal wall thickness; NA: not available; TD, Early deceleration time.

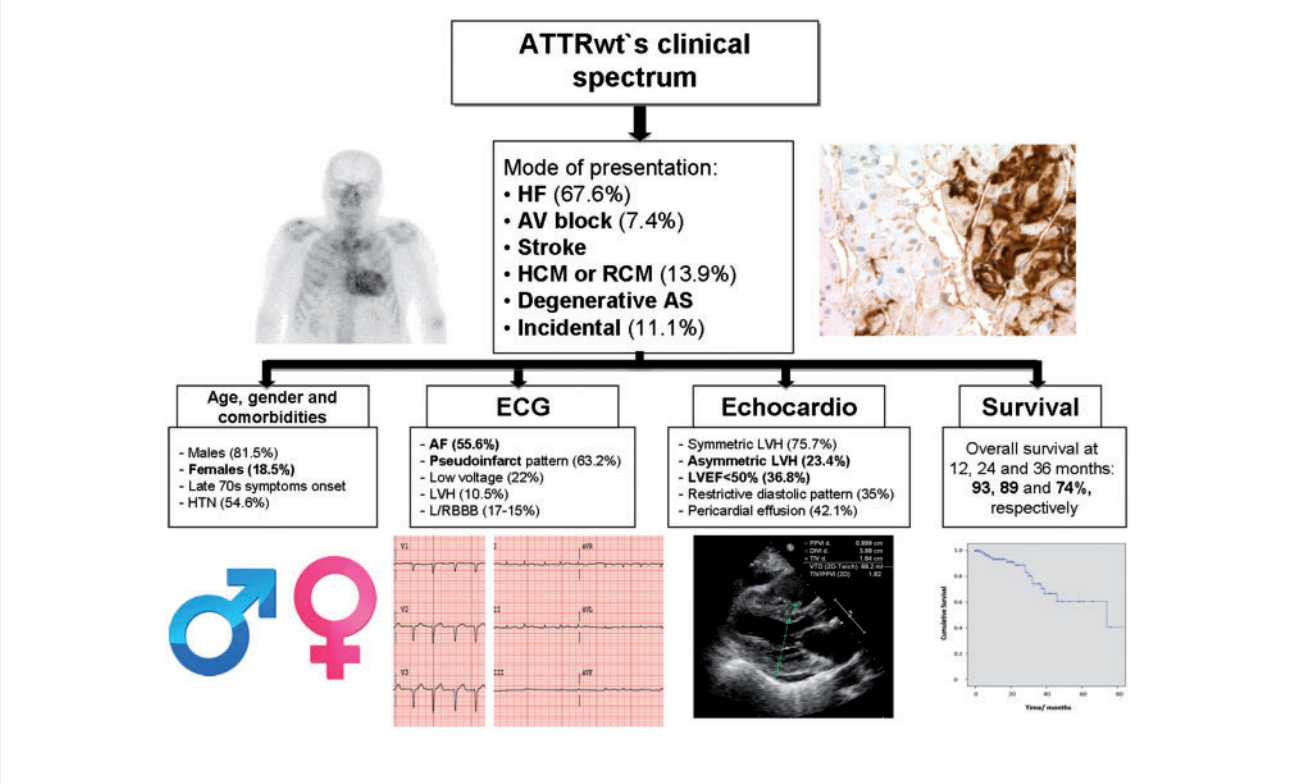

Figure 4 Characteristics of ATTRwt. HF, Heart failure; AV, Atrioventricular; HCM, Hypertrophic cardiomyopathy; RCM, Restrictive cardiomyopathy; AS, Aortic stenosis; HTN, Hypertension; AF, Atrial fibrillation; LVH, Left ventricular hypertrophy; L/RBBB, Left/Right bundle branch block; LVEF, Left ventricular ejection fraction.

misdiagnosis in our cohort. Hypertension is highly prevalent in the elderly population and LVH is frequently attributed to it. ATTRwt should not be excluded in this context and it should be highly suspected when hypertensive patients show normal blood pressure and require dose reduction or discontinuation of antihypertensive drugs.

HF is by far the most frequent manifestation of ATTRwt. Nonetheless, the clinical spectrum of ATTRwt is broader (*Figure 4*). One third of ATTRwt patients in our series did not present with signs or symptoms of HF at diagnosis (*Table 1*). Some ATTRwt patients presented with advanced AV block, stroke or restrictive cardiomyopathy, and HCM phenocopies. The heterogeneous presentation of ATTRwt is increasingly recognised in the literature and the latest ESC guidelines on HCM have acknowledged the role of bone-tracer scintigraphy for the differential diagnosis of ATTR.[26] More recently, the focus has turned towards the coexistence and importance of ATTRwt in the context of degenerative AS.[25] At the other end of the spectrum, ATTRwt can be diagnosed incidentally after a DPD scan performed for other reasons.[24]

Downloaded from https://academic.oup.com/eurheartj/article-abstract/38/24/1895/3059372 by biblioteca biomedica centrale universita di bologna user on 18 February 2020

Given the high sensitivity of scintigraphy to detect TTR amyloid before abnormalities are identified by other cardiac tests[24,27] and because new drugs under investigation could be more effective in earlier stages of the disease, DPD scintigraphy is an ideal screening tool for clinical scenarios where the prevalence of ATTRwt is beginning to be significant.[14,26,25]

Overcoming typical features–disproving the myths

Although low-voltage QRS is widely considered the most characteristic ECG sign of cardiac amyloidosis,[4] we found that this feature can only be found in one fifth of individuals according to the widely used limb and precordial criteria (*Figure 4*). Nonetheless, the prevalence of low voltage may vary depending on the criteria applied.[19,20]

A pseudoinfarct pattern (mainly in anterior leads) was the most frequent ECG finding (60% of patients) in our series (*Figure 2*) and other ATTRwt cohorts have reported similar findings.[13] Moreover, as shown in our cohort, LV hypertrophy criteria can be fulfilled in up to 10% of patients, making ATTRwt diagnosis in everyday practice challenging (*Figure 2*). A normal ECG can also be present in ATTRwt and, in our experience, usually goes hand-in-hand with an incidental bone-tracer cardiac uptake.

From an echocardiographic perspective, the classic ATTRwt phenotype has long been considered to be a thick-walled ventricle with a granular appearance of the myocardium. Despite the fact that a concentric hypertrophic pattern could be considered intuitively as part of the infiltrative nature of cardiac amyloidosis, we have found that almost 25% of patients have an asymmetric pattern of hypertrophy (*Figure 4*). The reported prevalence of asymmetric hypertrophy in cardiac amyloidosis in old series was quite low. However, a higher proportion of asymmetric hypertrophy (up to 69%) has been reported recently in a CMR study with 51 patients with several types of cardiac amyloidosis,[28] and also a segmental form with predominance of deposits in the septum has been described by histology.[29] Moreover, a recent study from the Mayo Clinic[30] described normal wall thickness in 3% of patients diagnosed with cardiac amyloidosis demonstrated by EMB. In this subgroup, 14% of individuals had ATTRwt and all of them required medications for congestive HF. Therefore, normal wall thickness does not exclude the possibility of cardiac amyloid, altering the accepted viewpoint that amyloidotic cardiomyopathy equals increased ventricular wall thickness. Additionally, the requirement of at least mild LVH to support a non-invasive diagnosis might lead to an underestimation of ATTRwt.

Regarding systolic function, and notwithstanding the classic strong link between ATTRwt and preserved EF, we found depressed LVEF <50% in ATTRwt more commonly than in other subtypes of cardiac amyloidosis. More than one third of our patients presented with LVEF <50%, and 10 (9%) showed a LVEF <30%. Due to the small sample size, evidence was not conclusive whether impaired LVEF or decreased MCF were associated or not with a reduced survival in our cohort.

Clinical impact of diagnosing ATTRwt

Overall, establishing the diagnosis of ATTRwt is important even in the absence of an approved specific therapy. ATTRwt diagnosis usually leads to modifications in prescribed treatment since beta-blockers, ACEI, and ARB are usually poorly tolerated in these patients and calcium channel blockers and digitalis are contra-indicated.[3,4] Moreover, intravascular fluid depletion from loop diuretics should always be borne in mind and diuretics used with care. Diagnosis of ATTRwt also leads to close rhythm follow-up as conduction defects could appear frequently and pacemaker insertion could be needed. By contrast, ICD implantation is controversial in ATTRwt for lack of evidence,[4,6,15] making differential diagnosis between ATTRwt and HCM very important. Another consequence of recognising ATTRwt is defining patient prognosis. Survival in ATTRwt is better than in other forms of cardiac amyloidosis and probably better than previously thought (*Figure 4*). Although survival in our cohort was 74% at 3 years, it should be noted that our cohort included a significant amount of patients diagnosed non-invasively in whom the diagnosis could have been made earlier, and also patients diagnosed incidentally and in 'atypical' clinical scenarios different to HF, representing an earlier phase of the disease.

Finally, it is expected that appropriate diagnosis may have a direct therapeutic impact in the near future given the promising results of ongoing clinical trials with different disease modifying compounds.[16,17]

Limitations

Considering the double-centre cohort study, variations in imaging techniques between the two centres cannot be fully excluded. Additionally, data from other biomarkers, speckle tracking or CMR could not be included in the present study due to the lack of standardization between the two centres. Survival data was limited to few events and a relatively short-term follow-up.

A potential heterogeneous nature of patient population due to the different means of diagnosis could not be excluded.

Finally, both participating centres are highly specialized, with active cardiac amyloidosis programmes and referral and survival bias cannot be ruled out.

Conclusions

The clinical spectrum of ATTRwt is heterogeneous and partly differs from the classic clinical phenotype of this disease currently accepted in the literature: women are affected in a significant proportion of cases; asymmetric LV hypertrophy and impaired LVEF are not rare; the commonest ECG finding is a pseudo-infarct pattern and only a minority of patients show low QRS voltages. Clinicians should be aware of the broad clinical spectrum of ATTRwt in order to correctly identify this entity for which a number of disease-modifying treatments are under investigation.

Supplementary material

Supplementary material is available at *European Heart Journal* online.

Acknowledgement

We gratefully acknowledge Kenneth McCreath PhD for English editing.

Downloaded from https://academic.oup.com/eurheartj/article-abstract/38/24/1895/3059372 by biblioteca biomedica centrale universita di bologna user on 18 February 2020

Funding

This work was supported in part by the Spanish Society of Cardiology [Grant 2016 to E.G-L.] and by the Instituto de Salud Carlos III (ISCIII) [grants RD012/0042/0066 and CB16/11/00432] and by the Spanish Ministry of Economy and Competitiveness [grant SAF2015-71863-REDT]. Grants are supported by the Plan Estatal de I+D+I 2013-2016–European Regional Development Fund (FEDER) "A way of making Europe".

Conflict of interest: none declared.

References

1. Tanskanen M, Peuralinna T, Polvikoski T, Notkola IL, Sulkava R, Hardy J, Singleton A, Kiuru-Enari S, Paetau A, Tienari PJ, Myllykangas L. Senile systemic amyloidosis affects 25% of the very aged and associates with genetic variation in alpha2-macroglobulin and tau: a population-based autopsy study. *Ann Med* 2008;**40**:232–239.
2. Lie JT, Hammond PI. Pathology of the senescent heart: anatomic observations on 237 autopsy studies of patients 90 to 105 years old. *Mayo Clin Proc* 1988;**63**:552–564.
3. García-Pavía P, Tomé-Esteban MT, Rapezzi C. Amyloidosis. Also a heart disease. *Rev Esp Cardiol* 2011;**64**:797–808.
4. Gertz MA, Benson MD, Dyck PJ, Grogan M, Coelho T, Cruz M, Berk JL, Plante-Bordeneuve V, Schmidt HH, Merlini G. Diagnosis, prognosis, and therapy of transthyretin amyloidosis. *J Am Coll Cardiol* 2015;**66**:2451–2466.
5. Yanagisawa A, Ueda M, Sueyoshi T, Okada T, Fujimoto T, Ogi Y, Kitagawa K, Tasaki M, Misumi Y, Oshima T, Jono H, Obayashi K, Hirakawa K, Uchida H, Westermark P, Ando Y, Mizuta H. Amyloid deposits derived from transthyretin in the ligamentum flavum as related to lumbar spinal canal stenosis. *Mod Pathol* 2015;**28**:201–207.
6. Priori SG, Blomström-Lundqvist C, Mazzanti A, Blom N, Borggrefe M, Camm J, Elliott PM, Fitzsimons D, Hatala R, Hindricks G, Kirchhof P, Kjeldsen K, Kuck KH, Hernandez-Madrid A, Nikolaou N, Norekvål TM, Spaulding C, Van Veldhuisen DJ. 2015 ESC Guidelines for the management of patients with ventricular arrhythmias and the prevention of sudden cardiac death. *Eur Heart J* 2015;**36**:2793–2867.
7. Olson LJ, Gertz MA, Edwards WD, Li CY, Pellikka PA, Holmes DR Jr, Tajik AJ, Kyle RA. Senile cardiac amyloidosis with myocardial dysfunction. Diagnosis by endomyocardial biopsy and immunohistochemistry. *N Engl J Med* 1987;**317**:738–742.
8. Pinney JH, Whelan CJ, Petrie A, Dungu J, Banypersad SM, Sattianayagam P, Wechalekar A, Gibbs SD, Venner CP, Wassef N, McCarthy CA, Gilbertson JA, Rowczenio D, Hawkins PN, Gillmore JD, Lachmann HJ. Senile systemic amyloidosis: clinical features at presentation and outcome. *J Am Heart Assoc* 2013;**2**:e000098.
9. Connors LH, Sam F, Skinner M, Salinaro F, Sun F, Ruberg FL, Berk JL, Seldin DC. Heart failure resulting from age-related cardiac amyloid disease associated with wild-type transthyretin: a prospective, observational cohort study. *Circulation* 2016;**133**:282–290.
10. Falk RH, Quarta CC, Dorbala S. How to image cardiac amyloidosis. *Circ Cardiovasc Imaging* 2014;**7**:552–562.
11. Ponikowski P, Voors AA, Anker SD, Bueno H, Cleland JG, Coats AJ, Falk V, González-Juanatey JR, Harjola VP, Jankowska EA, Jessup M, Linde C, Nihoyannopoulos P, Parissis JT, Pieske B, Riley JP, Rosano GM, Ruilope LM, Ruschitzka F, Rutten FH, van der Meer P. 2016 ESC Guidelines for the diagnosis and treatment of acute and chronic heart failure: the Task Force for the diagnosis and treatment of acute and chronic heart failure of the European Society of Cardiology (ESC). *Eur J Heart Fail* 2016;**18**:891–975.
12. Gillmore JD, Maurer MS, Falk RH, Merlini G, Damy T, Dispenzieri A, Wechalekar AD, Berk JL, Quarta CC, Grogan M, Lachmann HJ, Bokhari S, Castano A, Dorbala S, Johnson GB, Glaudemans AW, Rezk T, Fontana M, Palladini G, Milani P, Guidalotti PL, Flatman K, Lane T, Vonberg FW, Whelan CJ, Moon JC, Ruberg FL, Miller EJ, Hutt DF, Hazenberg BP, Rapezzi C, Hawkins PN. Non-biopsy diagnosis of cardiac transthyretin amyloidosis. *Circulation* 2016;**133**:2404–2412.
13. Rapezzi C, Lorenzini M, Longhi S, Milandri A, Gagliardi C, Bartolomei I, Salvi F, Maurer MS. Cardiac amyloidosis: the great pretender. *Heart Fail Rev* 2015;**20**:117–124.
14. González-López E, Gallego-Delgado M, Guzzo-Merello G, de Haro-Del Moral FJ, Cobo-Marcos M, Robles C, Bornstein B, Salas C, Lara-Pezzi E, Alonso-Pulpon L, Garcia-Pavia P. Wild-type transthyretin amyloidosis as a cause of heart failure with preserved ejection fraction. *Eur Heart J* 2015;**36**:2585–2594.
15. Castaño A, Drachman BM, Judge D, Maurer MS. Natural history and therapy of TTR-cardiac amyloidosis: emerging disease-modifying therapies from organ transplantation to stabilizer and silencer drugs. *Heart Fail Rev* 2015;**20**:163–178.
16. Wechalekar AD, Gillmore JD, Hawkins PN. Systemic amyloidosis. *Lancet* 2016;**387**:2641–2654.
17. Maurer MS, Grogan DR, Judge DP, Mundayat R, Packman J, Lombardo I, Quyyumi AA, Aarts J, Falk RH. Tafamidis in transthyretin amyloid cardiomyopathy: effects on transthyretin stabilization and clinical outcomes. *Circ Heart Fail* 2015;**8**:519–526.
18. Perugini E, Guidalotti PL, Salvi F, Cooke RM, Pettinato C, Riva L, Leone O, Farsad M, Ciliberti P, Bacchi-Reggiani L, Fallani F, Branzi A, Rapezzi C. Noninvasive etiologic diagnosis of cardiac amyloidosis using ^{99m}Tc-3,3-diphosphono-1,2-propanodicarboxylic acid scintigraphy. *J Am Coll Cardiol* 2005;**46**:1076–1084.
19. Cyrille NB, Goldsmith J, Alvarez J, Maurer MS. Prevalence and prognostic significance of low QRS voltage among the three main types of cardiac amyloidosis. *Am J Cardiol* 2014;**114**:1089–1093.
20. Mussinelli R, Salinaro F, Alogna A, Boldrini M, Raimondi A, Musca F, Palladini G, Merlini G, Perlini S. Diagnostic and prognostic value of low QRS voltages in cardiac AL amyloidosis. *Ann Noninvasive Electrocardiol* 2013;**18**:271–280.
21. Lang RM, Bierig M, Devereux RB, Flachskampf FA, Foster E, Pellikka PA, Picard MH, Roman MJ, Seward J, Shanewise JS, Solomon SD, Spencer KT, Sutton MS, Stewart WJ. Chamber quantification writing group; American society of echocardiography's guidelines and standards committee; European association of echocardiography. Recommendations for chamber quantification. *J Am Soc Echocardiogr* 2005;**18**:1440–1463.
22. McFarland TM, Alam M, Goldstein S, Pickard SD, Stein PD. Echocardiographic diagnosis of left ventricular hypertrophy. *Circulation* 1978;**57**:1140–1144.
23. Tendler A, Helmke S, Teruya S, Alvarez J, Maurer MS. The myocardial contraction fraction is superior to ejection fraction in predicting survival in patients with AL cardiac amyloidosis. *Amyloid* 2015;**22**:61–66.
24. Longhi S, Guidalotti PL, Quarta CC, Gagliardi C, Milandri A, Lorenzini M, Potena L, Leone O, Bartolomei I, Pastorelli F, Salvi F, Rapezzi C. Identification of TTR-related subclinical amyloidosis with ^{99m}Tc-DPD scintigraphy. *JACC Cardiovasc Imaging* 2014;**7**:531–532.
25. Longhi S, Lorenzini M, Gagliardi C, Milandri A, Marzocchi A, Marrozzini C, Saia F, Ortolani P, Biagini E, Guidalotti PL, Leone O, Rapezzi C. Coexistence of degenerative aortic stenosis and wild-type transthyretin-related cardiac amyloidosis. *JACC Cardiovasc Imaging* 2016;**9**:325–327.
26. Elliott PM, Anastasakis A, Borger MA, Borggrefe M, Cecchi F, Charron P, Hagege AA, Lafont A, Limongelli G, Mahrholdt H, McKenna WJ, Mogensen J, Nihoyannopoulos P, Nistri S, Pieper PG, Pieske B, Rapezzi C, Rutten FH, Tillmanns C, Watkins H. 2014 ESC Guidelines on diagnosis and management of hypertrophic cardiomyopathy: the Task Force for the Diagnosis and Management of Hypertrophic Cardiomyopathy of the European Society of Cardiology (ESC). *Eur Heart J* 2014;**35**:2733–2779.
27. Hutt DF, Quigley AM, Page J, Hall ML, Burniston M, Gopaul D, Lane T, Whelan CJ, Lachmann HJ, Gillmore JD, Hawkins PN, Wechalekar AD. Utility and limitations of 3,3-diphosphono-1,2-propanodicarboxylic acid scintigraphy in systemic amyloidosis. *Eur Heart J Cardiovasc Imaging* 2014;**15**:1289–1298.
28. Pozo E, Kanwar A, Deochand R, Castellano JM, Naib T, Pazos-López P, Osman K, Cham M, Narula J, Fuster V, Sanz J. Cardiac magnetic resonance evaluation of left ventricular remodelling distribution in cardiac amyloidosis. *Heart* 2014;**100**:1688–1695.
29. Leone O, Longhi S, Quarta CC, Ragazzini T, De Giorgi LB, Pasquale F, Potena L, Lovato L, Milandri A, Arpesella G, Rapezzi C. New pathological insights into cardiac amyloidosis: implications for non-invasive diagnosis. *Amyloid* 2012;**19**:99–105.
30. Suresh R, Grogan M, Maleszewski JJ, Pellikka PA, Hanna M, Dispenzieri A, Pereira NL. Advanced cardiac amyloidosis associated with normal interventricular septal thickness: an uncommon presentation of infiltrative cardiomyopathy. *J Am Soc Echocardiogr* 2014;**27**:440–447.

Downloaded from https://academic.oup.com/eurheartj/article-abstract/38/24/1895/3059372 by biblioteca biomedica centrale universita di bologna user on 18 February 2020