


REVIEW ARTICLE

Chilblains-like lesions and SARS-CoV-2 in children: An overview in therapeutic approach

Piero Pavone¹  | Silvia Marino² | Lidia Marino³ | Giovanni Cacciaguerra³ |
Claudio Guarneri⁴ | Giuseppe Nunnari⁴ | Rosaria Taibi⁵ | Livia Marletta⁴ |
Raffaele Falsaperla^{2,6}

¹Department of Clinical and Experimental Medicine, Section of Pediatrics and Child Neuropsychiatry, University of Catania, Catania, Italy

²Unit of Pediatrics and Pediatric Emergency, Pediatric COVID-19 Center, AOU "Policlinico", PO "SanMarco", University of Catania, Catania, Italy

³Department of Clinical and Experimental Medicine, University of Catania, Catania, Italy

⁴University of Messina, AOU "G. Martino", COVID Hospital, Messina, Italy

⁵Department of Medical Oncology, Istituto Nazionale Tumori, IRCCS, CRO, Aviano, Italy

⁶Neonatal Intensive Care Unit [NICU], Neonatal COVID-19 Center, AOU "Policlinico", PO "San Marco, University of Catania, Catania, Italy

Correspondence

Piero Pavone, Department of Clinical and Experimental Medicine, Section of Pediatrics and Child Neuropsychiatry, University of Catania, Italy.
Email: ppavone@unict.it

Abstract

SARS-CoV-2 (Severe Acute Respiratory Syndrome, Coronavirus, type 2) is the virus responsible for the global pandemic of Coronavirus disease 2019 (COVID-19) that began in China in December 2019. The variability of nasal olfactory symptoms in pediatric patients is interlinked with possible warning signs, including respiratory, gastrointestinal, ocular, or dermatological symptoms. Skin findings in patients with COVID-19 can range from petechiae to papulovesicular rashes to diffuse urticaria and can be confused with rashes of non-COVID-19 conditions. These lesions typically appear early during COVID-19 and are thought to be secondary to viral replication or circulating cytokines. Herein, we discuss two pediatric cases, presenting with skin lesions, which tested positive for SARS-CoV-2, thus, briefly reviewing current literature for similar reports and related management. Although these lesions heal spontaneously in most cases, an adequate "targeted" therapeutic approach can shorten the time and the discomfort of the skin disease.

KEYWORDS

coronavirus disease 2019, pediatric severe acute respiratory syndrome-Coronavirus type-2, therapy

1 | INTRODUCTION

The recent outbreak of Coronavirus infection greatly involves the resources of the global healthcare system, as it affects in first-line older adults and individuals already burdened by a great number of comorbidities. This novel Coronavirus may affect newborns, adults, and elders.¹ SARS-CoV-2 is a novel human coronavirus. There is now a total of seven coronaviruses known to cause disease in humans. Other elements of the family include severe acute respiratory syndrome-related coronavirus 1 (SARS-CoV-1), and Middle East respiratory syndrome-related coronavirus (MERS-CoV). The other four human coronaviruses—HCoV-NL63, HCoV-229E, HCoV-OC43, and HCoV-HKU1 are responsible for milder disease in humans: upper respiratory infections, croup, bronchiolitis, and pneumonia.^{2,3}

SARS-CoV-2 (Severe Acute Respiratory Syndrome, Coronavirus, type 2) is the virus responsible for the global pandemic of Coronavirus disease 2019 (COVID-19) that began in China in 4 December 2019.⁴

SARS-CoV-2 invades human cells binding to the angiotensin-converting enzyme II (ACE2) on cell surfaces.

Respiratory droplets containing the virus represent the main source of infection, through proximity with aerosolized secretions, with a sneeze or cough, or from direct contact with secretions of affected individuals.⁵

Vertical transmission of severe acute respiratory syndrome coronavirus 2 is possible and seems to occur in a minority of cases of maternal coronavirus disease 2019 infection in the third trimester. The rates of infection are similar to those of other pathogens that cause congenital infections.⁶

The incubation period of SARS-CoV-2 ranges from 2 to 14 days, with most patients developing symptoms 3 to 7 days after exposure.⁷ Reverse transcription-polymerase chain reaction (RT-PCR) is the current reference standard for the diagnosis of COVID-19.

Approved or clinically proven antiviral drugs recommended for COVID-19 in children do not exist. Clinical management includes prompt implementation of recommended infection prevention and control measures in healthcare settings and supportive management of complications.⁸

This infection runs in three major stages: a mild cold-like illness, moderate respiratory syndrome and severe acute interstitial pneumonia. The neck and head region can be variably affected in adults, and taste and smell disorders together with fever are typical manifestations. Patients with the moderate disease commonly have respiratory signs and symptoms: shortness of breath, chest constriction, and/or hypoxemia. These symptoms can progress to acute respiratory distress syndrome. However, pediatric clinical signs are less severe, making the onset diagnosis challenging to interpret. There is evidence that the levels of various proinflammatory cytokines are higher in adults. This may mean that adults experience a more pronounced inflammatory response than children with similar exposure to SARS-CoV-2.⁹

The variability of nasal olfactory symptoms in children and adolescents is intertwined with possible warning signs, including respiratory, gastrointestinal, ocular, or dermatological symptoms. Skin findings in patients with COVID-19 can range from petechiae to papulovesicular rashes to diffuse urticaria and can be confused with rashes of non-COVID-19 conditions.¹⁰ These rashes typically appear early during COVID-19 and are thought to be secondary to viral replication or circulating cytokines.¹¹ Acrocyanosis and chilblains seem to be more common and more suggestive, from a mechanistic point of view, than the others.¹²

2 | CASE REPORTS

2.1 | Case 1

A 7-year-old female patient presented with chilblain-like erythema accompanied by swelling and pain in her toes in the absence of any

systemic symptoms, the drug history was negative (no drug therapy in the past month). Red to purplish macules and papules further erupted on all her toes with a single vesicle on the second toe of her right foot (Figure 1A, B). Four days after the appearance of these manifestations, she was tested for SARS-CoV-2 because a family member was positive and symptomatic. Six days after the onset of the cutaneous lesions, mild to moderate respiratory symptoms appeared. Her skin lesions remained asymptomatic, improved, and healed over the next 3 weeks. The presence of SARS-CoV-2 was confirmed by nasal and pharyngeal swabs (RT-PCR with a detection limit of 100 copies/reaction).

2.2 | Case 2

An 11-year-old girl presented with persistent fever and cough 4 days after the onset of chilblains-like erythema and reddish maculopapular lesions affecting most of her toes with subsequent appearance of mild itching (Figure 2A,B). Small, red macules, and papules were also noted on the second and third digit of the left hand. Nasal and pharyngeal swabs SARS-CoV-2 were positive.

The girl received a short course of topical corticosteroids, before then, last drug therapy (NSAIDs for headache) 20 days before skin manifestation. No itch, pain or burning was reported during the next 15-day course of the cutaneous disease.

3 | DISCUSSION

Symptoms of SARS-CoV-2 infection are non-specific and disease presentation can range from no symptoms to severe pneumonia and multiple organ dysfunction syndrome.¹³ People of any age may be affected, from infants to the elderly population.¹⁴ Prognosis is worse in the presence of co-morbidities such as diabetes, cardiovascular, or chronic obstructive pulmonary disease. Even if some complications such as multisystem inflammatory syndrome has been reported, children usually show less severe clinical manifestations and lower

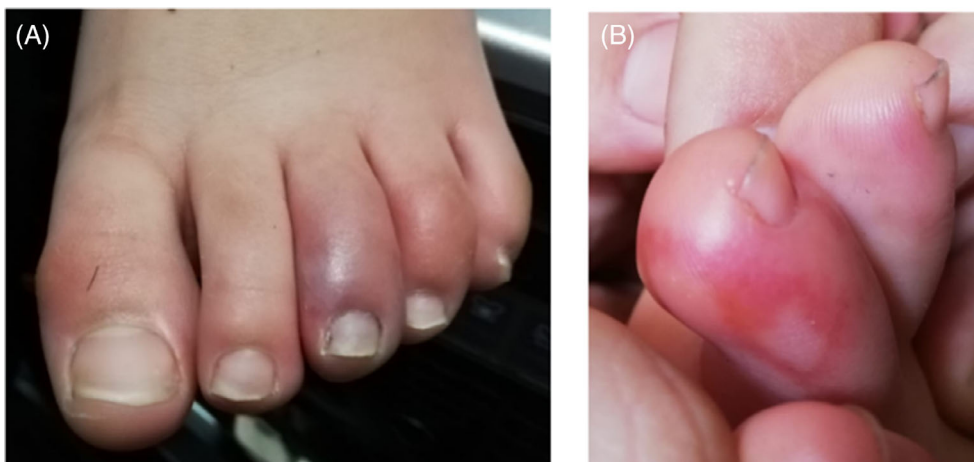
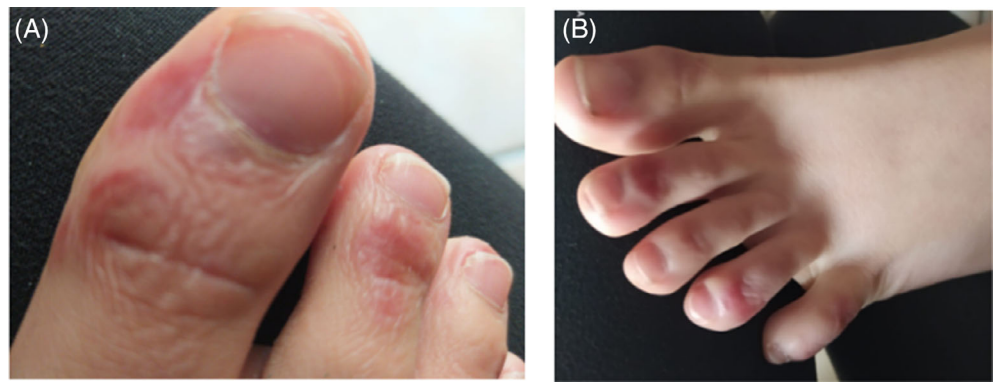


FIGURE 1 A, B, Swelling of the toes with red maculopapular and vesicular lesions

FIGURE 2 A, B, Reddish maculopapular lesions of the toes



mortality. This could be due to lower expression levels of the angiotensin-converting enzyme 2 binding receptor for SARS-CoV-2 as well as an immature immunological development.¹⁵ Huang et al¹⁴ prospectively collected and analyzed data from 41 adult patients with laboratory-confirmed SARS-CoV-2 infection. Presenting symptoms were often fever, cough, myalgia and fatigue. Less frequently, the disease presented with sputum production, headache, hemoptysis, and diarrhea. Dyspnea developed in almost half of the patients. Although data on children are limited, it appears that the infection can be asymptomatic, paucisymptomatic (fever, dry cough, and fatigue), or can present with gastrointestinal symptoms such as abdominal discomfort, nausea, vomiting, abdominal pain, and diarrhea. Since clinical symptoms are often absent; children may represent undiagnosed and underestimated carriers of the disease. Children and adolescents with chilblain-like lesions who are otherwise asymptomatic should undergo SARS-CoV-2 testing, which could help early detection of silent carriers.¹⁶

Chilblains, also known as erythema pernio, are the result of a self-limiting skin inflammation that occurs in some individuals as a reaction to cold exposure followed by rewarming. The diagnosis of pernio is largely clinical and based on a deep history and physical exam.¹⁷ The etiology is unknown, but it might relate to vessel spasms induced by cold exposure.

Chilblains are occasionally a cutaneous manifestation of autoimmune diseases such as lupus erythematosus or sarcoidosis. Recalcati recently reported SARS-CoV-2 cutaneous manifestations in adults. In his cohort, 18 out of 88 patients developed cutaneous manifestations, of which eight at disease onset and 10 during hospitalization. Skin manifestations had no apparent correlation with disease severity, and they included erythematous rashes, widespread urticaria, and chickenpox-like vesicle.¹⁸ Varga et al¹⁹ suggested that the recruitment of immune cells, either by direct viral infection of the endothelium or immune-mediated, can result in widespread endothelial dysfunction associated with apoptosis. Other variants of virus-related skin manifestations are described in the literature. Klimach et al²⁰ reported a case of confirmed COVID-19 in a child who presented with skin findings localized to the axillae, lower limbs and plantar aspects of the feet. The skin changes fully resolved within 10 to 14 days. Torreló et al²¹ described four patients with lesions clinically consistent with

erythema multiforme (EM) and histopathological features not specific or typical for EM. These lesions were located on the most common cutaneous sites of involvement of classical EM. They appeared in patients with COVID-19-related chilblains. One patient was given a short course of oral corticosteroids and another patient received topical corticosteroids. All patients experienced complete remission of their skin lesions within 1 to 3 weeks and had no complications. Colonna et al²² described chilblains-like lesions in four children to further explore its correlation with COVID-19. In their patients, the cutaneous manifestation appeared several days after systemic symptoms and all tests for active COVID-19 infection were negative at the time of first clinical evaluation. COVID-19 could be responsible for coagulation disorders, increasing the D-dimer and fibrinogen degradation products, leading to acro-ischemia. Madinaveitia et al²³ presented the case of a 9-year-old girl who consulted for a pruritic rash associated with odynophagia and myalgias of 9 days of evolution. Given the current epidemic situation, general symptoms (fever, myalgias) and upper respiratory tract (odynophagia) and pruritic lesions predominantly on the trunk, lower extremities and in distal regions previously described in up to 20% of infections for SARS-CoV-2, RT-PCR was requested in the nasopharyngeal swab, which was positive. The patient received treatment with oral prednisone for 3 days at 1 mg/kg, with a subsequent decrease to 0.5 mg/kg for 2 days. The response to treatment was favorable, with significant improvement in the lesions and disappearance of itching 48 h after starting treatment; later, asymptomatic. As we have noticed, there are many skin lesions associated with COVID-19, as well as therapeutic proposals.

Ladha et al²⁴ described that potent topical corticosteroids (TCS) are often recommended. The anti-inflammatory effect of potent TCS (eg, clobetasol propionate) via inhibition of interferon production provides relief of inflammatory (red, hot, and burning/painful) lesions. Additional reported treatments for chilblains include topical nitroglycerin 0.2% ointment twice daily (bis in die-BID).

4 | CONCLUSIONS

Chilblains may be signs or symptoms of SARS-CoV-2 infection in children, although the underlying mechanism remains to be

investigated. Uncertainty exists regarding whether the pathogenesis of chilblains is inflammatory, vasculitic, ischemic, or a combination thereof.

In our opinion, patients presenting with any type of skin rash or acrocyanosis need to be tested for SARS-CoV-2 to timely manage the disease in the pediatric setting and prevent the spread of the virus. As regards the therapy, both in our case and in the aforementioned ones, adding a mainly topical therapy could shorten the duration of the skin lesion, and improve the symptoms, such as itching or edema. The debate on which drug to use is still wide and many molecules are tested on these lesions (topical cortisones, nitroglycerin, etc.). If prevention is still a better strategy compared to treatment, probably, we should focus on new strategic approaches to outbreak management.²⁵

A better knowledge of the pathogenetic mechanisms of the disease and a wider casuistry will better guide us soon.

ACKNOWLEDGMENTS

The authors would like to thank AME (USA) Editor American manuscript Editors, in the person of Molly Mullin for editing the manuscript. Compensation has been provided.

CONFLICT OF INTEREST

The authors declare no conflicts of interest.

AUTHOR CONTRIBUTIONS

Dr. Piero Pavone had full access to all the data in the study and takes responsibility for its integrity and accuracy. Dr. Marino Silvia, Dr. Marino Lidia, Prof. Claudio Guarneri, Prof. Giuseppe Nunnari, Dott. Rosaria Taibi and Dott Livia Marletta conceptualized and designed the study, drafted the initial manuscript, reviewed and revised the manuscript. Prof. Falsaperla and Dr. Cacciaguerra designed the data collection instruments, collected data, carried out the initial analyses, reviewed and revised the manuscript. All authors approved the final manuscript as submitted and agree to be accountable for all aspects of the work.

DATA AVAILABILITY STATEMENT

The data that support the findings of this study are available on request from the corresponding author. The data are not publicly available due to privacy or ethical restrictions.

ORCID

Piero Pavone  <https://orcid.org/0000-0002-5600-9560>

REFERENCES

- Pavone P, Ceccarelli M, Taibi R, La Rocca G, Nunnari G. Outbreak of COVID-19 infection in children: fear and serenity. *Eur Rev Med Pharmacol Sci*. 2020;24:4572-4575.
- Zimmermann P, Curtis N. Coronavirus infections in children including COVID-19: an overview of the epidemiology, clinical features, diagnosis, treatment and prevention options in children. *Pediatr Infect Dis J*. 2020; 39(5):355-368. <https://doi.org/10.1097/INF.0000000000002660>.
- Dong Y, Mo X, Hu Y, et al. Epidemiology of COVID-19 Among Children in China. *Pediatrics*. 2020;145(6):e20200702. <http://dx.doi.org/10.1542/peds.2020-0702>.
- Li Q, Guan X, Wu P, et al. Early transmission dynamics in Wuhan, China, of novel coronavirus-infected pneumonia. *N Engl J Med*. 2020; 382(13):1199-1207. <https://doi.org/10.1056/NEJMoa2001316>.
- Heymann DL, Shindo N. WHO scientific and technical advisory group for infectious hazards. COVID-19: what is next for public health? *Lancet*. 2020;395:542-545.
- Kotlyar AM, Grechukhina O, Chen A, et al. Vertical transmission of coronavirus disease 2019: a systematic review and meta-analysis. *Am J Obstet Gynecol*. 2020;49:1-19. <https://doi.org/10.1016/j.ajog.2020.07.049>
- Chen ZM, Fu JF, Shu Q, et al. Diagnosis and treatment recommendations for pediatric respiratory infection caused by the 2019 novel coronavirus. *World J Pediatr*. 2020;16(3):240-246. <https://dx.doi.org/10.1007/s12519-020-00345-5>.
- Shen KL, Kunling, Yang YH, Wang TY, et al. Diagnosis, treatment, and prevention of 2019 novel coronavirus infection in children: experts' consensus statement. *World Journal of Pediatrics*. 2020;16(3): 223-231. <http://dx.doi.org/10.1007/s12519-020-00343-7>.
- Molloy EJ, Bearer CF. COVID-19 in children and altered inflammatory responses. *Pediatr Res*. 2020;88:340-341. <https://doi.org/10.1038/s41390-020-0881-y>.
- Genovese G, Colonna C, Marzano AV. Varicella-like exanthem associated with COVID-19 in an 8-year-old girl: a diagnostic clue? *Pediatr Dermatol*. 2020;37:435-436. <https://doi.org/10.1111/pde.14201>.
- Diotallevi F, Campanati A, Bianchelli T, et al. Skin involvement in SARS-CoV-2 infection: case series. *J Med Virol*. 2020;92:2332-2334. <https://doi.org/10.1002/jmv.26012>.
- Guarneri C, Venanzi Rullo E, Gallizzi R, et al. Diversity of clinical appearance of cutaneous manifestations in the course of COVID-19. *Journal of the European Academy of Dermatology and Venereology*. 2020;34(9):1-6. <http://dx.doi.org/10.1111/jdv.16669>.
- Pavone P, Giallongo A, La Rocca A, et al. Recent COVID-19 outbreak: effects in childhood. *Infect Dis Trop Med*. 2020;6:e594.
- Huang C, Wang Y, Li X, et al. Clinical features of patients infected with 2019 novel coronavirus in Wuhan, China. *Lancet*. 2020;395 (10223):497-506. [https://doi.org/10.1016/S0140-6736\(20\)30183-5](https://doi.org/10.1016/S0140-6736(20)30183-5).
- Zheng F, Liao C, Fan QH, et al. Clinical characteristics of children with coronavirus disease 2019 in Hubei, China. *Curr Med Sci*. 2020;40(2): 275-280. <https://doi.org/10.1007/s11596-020-2172-6>.
- Guarneri C, Rullo EV, Pavone P, et al. Silent COVID-19: what your skin can reveal. *Lancet Infect Dis*. 2020;3099(20):30402-30403. [https://doi.org/10.1016/S1473-3099\(20\)30402-3](https://doi.org/10.1016/S1473-3099(20)30402-3).
- Gallizzi R, Sutera D, Spagnolo A, et al. Management of pernio-like cutaneous manifestations in children during the outbreak of covid-19. *Dermatol Ther*. 2020;1-6. e14312. <https://doi.org/10.1111/dth.14312>.
- Recalcati S. Cutaneous manifestations in COVID-19: a first perspective. *J Eur Acad Dermatol Venereol*. 2020;34(5):212-213. <https://doi.org/10.1111/jdv.16387>.
- Varga Z, Flammer AJ, Steiger P, et al. Endothelial cell infection and endotheliitis in COVID-19. *Lancet*. 2020;395:1417-1418.
- Klimach A, Evans J, Stevens J. Rash as a presenting complaint in a child with COVID-19. *Pediatr Dermatol*. 2020 37:966-967. <https://doi.org/10.1111/PDE.14257>.
- Torrelo A, Andina D, Santonja C. Erythema multiforme-like lesions in children and COVID-19. *Pediatr Dermatol*. 2020;37(3):442-446. <https://doi.org/10.1111/pde.14246>.
- Colonna C, Monzani NA, Rocchi A, et al. Chilblain-like lesions in children following suspected COVID-19 infection. *Pediatr Dermatol*. 2020;37(3):437-440.

23. Madinaveitia SO, Penedo RP, Gil RR. Lesiones cutáneas en paciente con infección por SARS-COV2. *Anal Pediatr.* 2020;93(2):144-145.
24. Ladha MA, Luca N, Constantinescu C. Approach to chilblains during the COVID-19 pandemic. *J Cutan Med Surg.* 2020;24(5):504-517. <https://doi.org/10.1177/1203475420937978>.
25. Perrella A, Carannante N, Berretta M, et al. Novel coronavirus 2019 (Sars-CoV2): a global emergency that needs new approaches? *Eur Rev Med Pharmacol Sci.* 2020;24(4):2162-2164. https://doi.org/10.26355/eurrev_202002_20396.

How to cite this article: Pavone P, Marino S, Marino L, et al. Chilblains-like lesions and SARS-CoV-2 in children: An overview in therapeutic approach. *Dermatologic Therapy.* 2021;34:e14502. <https://doi.org/10.1111/dth.14502>