

# Subcutaneous emphysema after spontaneous pneumothorax: A rare cause of persistent increase of shock impedance in an implantable cardioverter-defibrillator



Federico Gibiino, MD,\* Francesco Vitali, MD,\* Michele Malagù, MD,\* Luca Rossi, MD,†  
Andrea Biagi, MD,† Matteo Bertini, MD, PhD\*

From the \*Cardiovascular Institute, University of Ferrara, Ferrara, Italy, and †Division of Cardiology, Cardiovascular and Emergency Department, Guglielmo da Saliceto Hospital, Piacenza, Italy.

## Introduction

Cardiac implantable electronic devices (CIED) are widely used today and management of remote monitoring device alerts is a common issue in everyday clinical practice. Low-voltage (pacing circuit) and high-voltage (HV) (shock circuit) impedance (defined as ratio of voltage to current in an electrical circuit) are crucial parameters of pacemakers and implantable cardioverter-defibrillators (ICDs). Shock impedance or HV impedance is automatically estimated using low-voltage sub-threshold measurements to provide useful data for diagnosis of lead malfunctions. Normal values vary among time and manufacturers, but abrupt and persistent changes can be caused not only by lead malfunction, pin-header connection problems, and electrode/coil mineralization, but also by pathologic extracardiac conditions such as pneumothorax or intrathorax fluid accumulation.<sup>1</sup> Extensive use of home monitoring allows early detection of altered values, reducing inappropriate therapies and increasing patients' safety.<sup>2</sup> We report a case of abrupt and persistent increase of HV impedance detected at home monitoring transmission caused by subcutaneous emphysema after a massive pneumothorax.

## Case report

A 72-year-old male patient was admitted to the emergency department with shortness of breath and cough. He had previous atypical resection of the apical and anterior segment of

**KEYWORDS** Shock impedance; Subcutaneous emphysema; Implantable cardioverter-defibrillator; Remote monitoring; Pneumothorax (Heart Rhythm Case Reports 2023;9:296–299)

**Funding Sources:** This research did not receive any specific grant from funding agencies in the public, commercial, or not-for-profit sectors. **Disclosures:** On behalf of all authors, the corresponding author states that there is no conflict of interest. **Address reprint requests and correspondence:** Dr Federico Gibiino, Cardiology Unit, Azienda Ospedaliero-Universitaria S. Anna, Via A. Moro 8, Ferrara-Cona (FE), Italy. E-mail address: [federico.gibiino@hotmail.it](mailto:federico.gibiino@hotmail.it).

## KEY TEACHING POINTS

- Shock impedance or high-voltage (HV) impedance is a key parameter in implantable cardioverter-defibrillators (ICDs), as high values could be responsible for failure to defibrillate and responsible for inappropriate therapies.
- This the first reported case of persistently increased HV impedance in a transvenous ICD caused by subcutaneous emphysema near the generator not as an early complication of the implantation procedure but occurring spontaneously after years of stability.
- Remote monitoring was confirmed to be reliable in promptly transmitting the abrupt increase in shock impedance and was helpful to follow the return of shock impedance in range values after subcutaneous emphysema resolution.

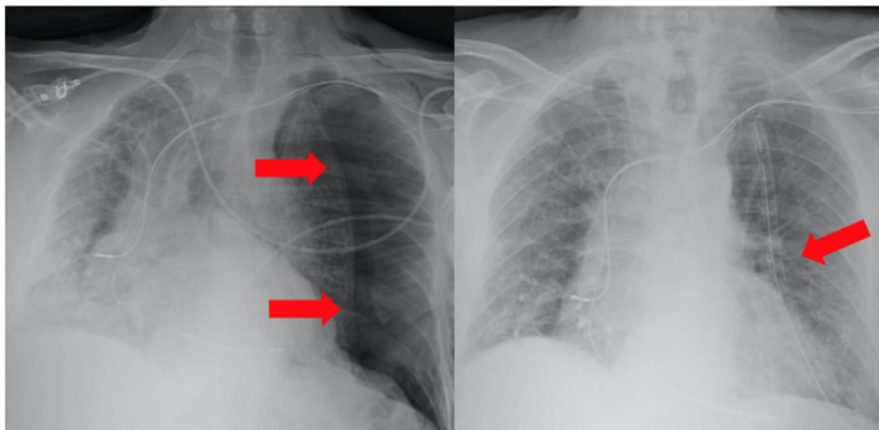
the right upper lung lobe owing to right spontaneous massive pneumothorax in severe pulmonary emphysema, with good long-term recovery. In 2014 he also had a diagnosis of dilated cardiomyopathy with very low left ventricular ejection fraction, and 1 year later a bicameral transvenous ICD (Inventra 7 DR-T; Biotronik, Berlin, Germany) with single-coil ventricular lead was implanted in primary prevention. ICD home monitoring was activated. After 8 years of follow-up left ventricular ejection fraction improved from 25% to 40% and no ICD intervention were registered; pacing/sensing and HV circuit parameters were optimal and stable. At hospital admission, blood pressure was 140/90 mm Hg with a pulse of 65 beats/min. The electrocardiogram showed normal sinus rhythm. On pulmonary auscultation vesicular murmur was absent in the left hemithorax. A chest radiograph showed

evidence of spontaneous massive left pneumothorax. Immediately a chest tube was positioned (Figure 1). The next day the pneumothorax increased in size up to the total collapse of the left lung, documented at computed tomography scanning so the chest tube was repositioned and then chemical pleurodesis was performed. A new chest radiograph confirmed the resolution of the pneumothorax and showed mild subcutaneous emphysema in the left hemithorax near the chest tube. After a few days the chest tube was removed. The patient was then discharged asymptomatic. Once discharged and back home, the patient resumed the usual remote monitoring transmissions. We received a home monitoring red alarm showing out-of-range shock impedance with an abrupt and sudden increase of the values from 85 to >150 ohms. Right atria and right ventricle sensing, pacing, pacing impedance, and also thoracic impedance values remained stable. No arrhythmic or noise events were detected. In the following days we received continuously out-of-range shock impedance alarms, with remaining parameters within the normal range. Fearing a new recurrence of pneumothorax or of damage to the shock circuit, even if the patient reported to be well, an urgent visit was scheduled. Shock impedance was confirmed to be out of range. No noise episodes were recorded even after muscle maneuvers. Physical examination and a new chest radiograph showed large subcutaneous emphysema, in particular in the left axillary region around the defibrillator generator (Figure 2), and confirmed the resolution of the pneumothorax. After about 10 days we obtained a first shock impedance value of around 150 ohms from remote monitoring transmission. In the following months with concomitant subcutaneous emphysema resolution, we witnessed a progressive reduction of the shock impedance values until stabilization around 90 ohms (similar to the values prior to the hospitalization) about 1 month after discharge (Figure 3).

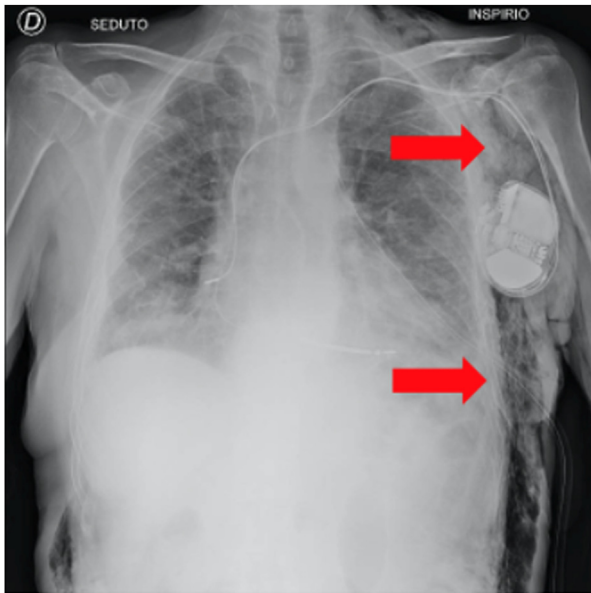
## Discussion

Shock impedance, estimated using a low-voltage sub-threshold measurement, is a key parameter in ICDs. Normal

values vary among manufacturers, different leads (single or double coil), and defibrillation vectors, with typical ranges between 40 and 100  $\Omega$  for right ventricle coil to can vector. Gradual lowering of shock impedance can occur in case of insulation breach, while conductor fracture cause increase of shock impedance.<sup>3</sup> Causes of abrupt increase of shock impedance in the perioperative period are connector pin connection issues, lead dislodgment, ventricle perforation, and pneumothorax, while conductor fracture is the main cause of abrupt increase during follow-up and is usually associated with noise detection (signals detected are not cyclical, with very short intervals, and have variable amplitude, morphology, and frequency). Conversely, gradual increases in shock impedance are typical of mineralization of the fibrous sheath around the shock coil.<sup>3</sup> As the underlined conditions could be responsible for failure to defibrillate and responsible for inappropriate therapies, prompt identification of abnormal high-voltage impedance values and correction of the causes are mandatory.<sup>1,3</sup> Remote monitoring has shown to provide fast report of altered parameters (including shock impedance) and earlier detection of clinical events, contributing to the reduction of inappropriate ICD shock.<sup>2,4</sup> Pneumothorax, a rare perioperative complication after subclavian vein puncture, is a well-described cause of abrupt increase of shock impedance after implant and consequently the cause of high defibrillation threshold owing to air increase in the hemithorax. Defibrillation impedance usually returns to normal values after pneumothorax resolution.<sup>5,6</sup> Similarly, air entrapment and subcutaneous emphysema have been reported since the 1980s as early complications after subclavian vein puncture or generator replacement as the cause of pacing impedance increase and loss of capture in the old unipolar pacemakers.<sup>7,8</sup> With subcutaneous ICDs several cases of air entrapment in the device pocket or surrounding the electrode early after implantation have been described. In subcutaneous ICDs air entrapment can cause increased shock impedance, oversensing, and inappropriate shocks. In all the cases described, air entrapment was detected hours or few days after the implant procedure with chest radiography, and spontaneous resolution occurred in few weeks.<sup>9,10</sup>



**Figure 1** Chest radiograph showed evidence of spontaneous massive left pneumothorax and chest tube (red arrows in the left and the right panel, respectively).



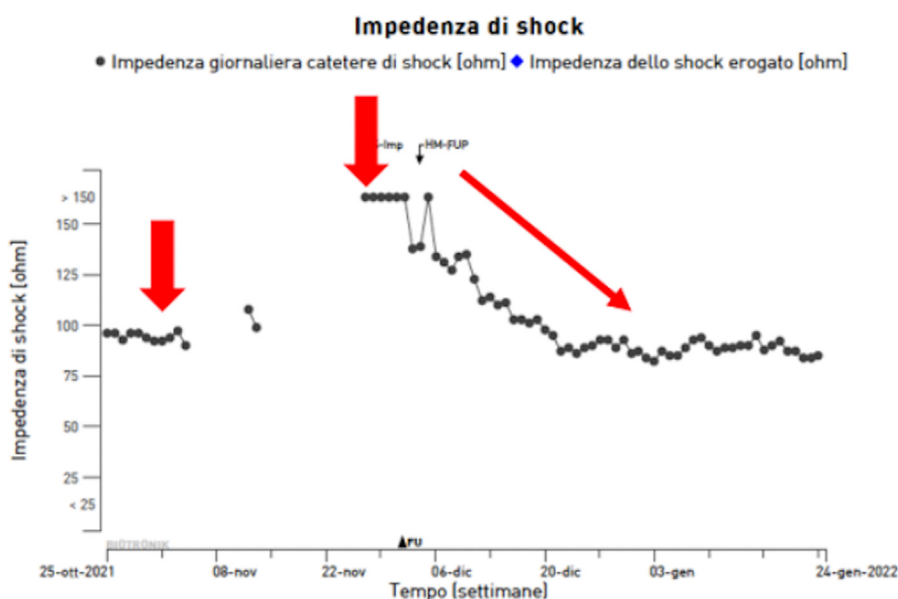
**Figure 2** Chest radiograph showed large subcutaneous emphysema, in particular in the left axillary region and around the defibrillator generator (red arrow), and confirmed the resolution of the pneumothorax.

In our case the patient received a dual-chamber ICD several years before the occurrence of spontaneous pneumothorax. The abrupt increase of shock impedance was correctly and promptly reported by home monitoring. The home monitoring alerts continued to report altered values despite the resolution of pneumothorax, so an urgent visit was scheduled in which vast subcutaneous emphysema was diagnosed in the left axillary region where the defibrillator generator had previously been implanted. Subcutaneous

emphysema is reported to occur both as a complication of large pneumothorax and as a consequence of chest tube drainage.<sup>11</sup> In our case the admission chest radiography showed massive pneumothorax without air entrapped in subcutaneous tissue. We cannot exclude that the first ineffective attempt of the chest tube drainage insertion, requiring repositioning, could have contributed to the formation of subcutaneous emphysema. The progressive return to normal values of shock impedance after complete resolution of subcutaneous emphysema suggests a causative role of air entrapped in subcutaneous tissue in the left axillary region in close proximity of the generator in increasing shock impedance after years of stable values. This finding is also confirmed by the stability of other bipolar electrical parameters (pacing impedance, atrial/ventricular thresholds, and sensing).

As high shock impedance is a cause of defibrillation failure, in case of high values of this parameter defibrillation threshold testing can be indicated and eventually a wearable cardioverter-defibrillator can be prescribed before discharge. In our case during the altered shock impedance phase, given the stability of other parameters, the history of the asymptomatic patient with an improved left ventricular ejection fraction without prior arrhythmic events, and the reported cases of rapid normalization of shock impedance after subcutaneous emphysema, and also thanks to the availability of remote monitoring transmissions, we collegially decided to strictly follow up the patient until the resolution of the anomaly.

To the best of our knowledge, this the first reported case of persistently increased high-voltage impedance in a transvenous ICD caused by subcutaneous emphysema in close proximity of the generator not as an early complication of the implantation procedure but occurring spontaneously after



**Figure 3** High-voltage (HV) impedance trend. On the ordinates are shown values in ohms, on the abscissa time. From left to right the first arrow shows constant normal values of HV impedance. The second arrow shows the abrupt increase after the recovery of home monitoring transmissions at the resolution of pneumothorax. Gradual return of HV values in normal ranges (with the progressive resolution of subcutaneous emphysema) is shown by the third arrow.

years of stability. Furthermore, the diagnosis was made thanks to the remote monitoring alerts that showed high values of HV impedance after pneumothorax resolution, suggesting a causative role of the subcutaneous emphysema.

## Conclusion

High-voltage impedance of ICDs can be altered by pneumothorax and subcutaneous emphysema not only as an early complication of the implant procedure but also following years of clinical and electrical parameter stability. In our case home monitoring was confirmed to be reliable in promptly transmitting the abrupt increase in shock impedance and was helpful to follow the return of shock impedance in range values after subcutaneous emphysema resolution.

## References

1. Swerdlow CD, Ploux S, Poole JE, Nair SG, Himes A, Ellenbogen KA. Interpreting device diagnostics for lead failure. *Heart Rhythm* 2022;19:154–164.
2. Ganeshan R, Enriquez AD, Freeman JV. Remote monitoring of implantable cardiac devices: current state and future directions. *Curr Opin Cardiol* 2018;33:20–30.
3. Swerdlow CD, Koneru JN, Gunderson B, Kroll MW, Ploux S, Ellenbogen KA. Impedance in the diagnosis of lead malfunction. *Circ Arrhythm Electrophysiol* 2020;13:e008092.
4. Ploux S, Swerdlow CD, Bordachar P, et al. Towards eradication of inappropriate therapies for ICD lead failure by combining comprehensive remote monitoring and lead noise alerts. *J Cardiovasc Electrophysiol* 2018;29:1125–1134.
5. Kamioka M, Nodera M, Suzuki H, Takeishi Y. The utility of shock coil and left ventricular tip–right ventricular coil impedance as a predictor of pneumothorax in cardiac resynchronization therapy implantation. *J Cardiol Cases* 2016;13:193–195.
6. Sponga S, Mascioli G, Voisine P, Vitali E. A case of inefficient defibrillation during thoracotomy. *J Card Surg* 2011;26:338–339.
7. Hearne SF, Maloney JD. Pacemaker system failure secondary to air entrapment within the pulse generator pocket. *Chest* 1982;82:651–654.
8. Santomauro M, Ferraro S, Maddalena G, et al. Pacemaker malfunction due to subcutaneous emphysema — a case report. *Angiology* 1992;43:873–876.
9. Adduci C, Spadoni L, Palano F, Francia P. Ventricular fibrillation undersensing due to air entrapment in a patient implanted with a subcutaneous cardioverter defibrillator. *J Cardiovasc Electrophysiol* 2019;30:1373–1374.
10. Lee S, Souvaliotis N, Mehta D, Suri R. Inappropriate shock in a subcutaneous cardiac defibrillator due to residual air. *Clin Case Rep* 2017;5:1203–1206.
11. Jones PM, Hewer RD, Wolfenden HD, Thomas PS. Subcutaneous emphysema associated with chest tube drainage. *Respirology* 2001;6:87–89.