

# Hip Replacement after Proximal Femur Failed Osteosynthesis: our experience

Nicola Corradi, Gaetano Caruso, Ilaria Martini, Leo Massari

Department of Orthopaedic and Traumatology, University of Ferrara, Ferrara, Italy

**Abstract.** *Background and aim:* failure of proximal femur fixation is a rare but challenging complication. Hip replacement could be a safe and optimal salvage treatment option. However, serious complications could occur. The aim of our study is to retrospectively review all hip replacement performed after proximal femur fixation failure and to evaluate functional and radiographic outcomes. *Methods:* we reviewed all Total Hip Arthroplasty and Hemiarthroplasty performed from 2013 to 2020 in Our Department. We evaluated latest follow-up x-rays for stem subsidence, varus-valgus stem position ( $>5^\circ$ ), limb length inequality ( $>1\text{cm}$ ), dislocation, component loosening, heterotopic calcification classified according to Brooker, cement leakage. Harris Hip Score (HHS) and Hip WOMAC score were performed at the latest follow-up to estimate functional outcome. *Results:* 14 THA had no complications with mean HHS 86.5 and WOMAC score 91.68. 1 periprosthetic infection was reported on THA, however after 2-stages revision functional and radiographic outcomes were satisfactory. 5 HA had rated mean HHS 65.8 and WOMAC score 70.18. 2 HA experienced dislocations which required surgical revision and conversion to THA. *Conclusions:* as a salvage surgery for failure of proximal femur fixation, Hip Replacement is safe and recommendable. THA reported better results than HA. Nonetheless, every patient should be carefully evaluated before undergoing surgery to detect possible complication risk factors. ([www.actabiomedica.it](http://www.actabiomedica.it))

**Key words:** proximal femur fracture, failure fixation, salvage hip arthroplasty, complications

## Introduction

Proximal femur fracture is worldwide issue especially in elderly population, raising year by year due to aging (1, 2). Two kind of fracture are the most frequent: lateral or extracapsular fractures and medial or intracapsular fractures (3). They are cause of invalidity and high socio-economic costs therefore early surgery is mandatory whenever possible (4 – 6). Extracapsular fractures are usually treated by intra or extramedullary fixation. Nowadays intramedullary nailing is becoming first choice treatment worldwide (7, 8). Intracapsular fractures treatment depends on patient age, fracture stability and displacement (9). Internal fixation is recommended in young adult patients, while in elderly

patients it is exclusively recommended for undisplaced and stable fractures (10, 11).

Although most of proximal femur fracture fixation achieve good results, possible failures of fixation could compromise patient recovery and even survival in some cases (9).

Salvage surgery could be usually reosteosynthesis or hip replacement. Actually just a few studies report their case series (12).

We reported our retrospective cases, including implant type, bearing surfaces, x-ray and functional outcomes, about total hip arthroplasty or hip hemiarthroplasty performed after failure of proximal femur osteosynthesis.

## Material and methods

We conducted a monocentric retrospective study on Total Hip Arthroplasty (THA) and Hip Hemiarthroplasty (HA) performed after failure of previous proximal femur fracture fixation in our Department. All data were collected and analyzed anonymously.

Between January 2013 and June 2020, 21 patients (13 women and 8 men) with mean age 74.1 years (range 26 – 98) underwent hip replacement for proximal femur fracture fixation failure, one patient had a bilateral fixation failure, consequently overall hip replacements were 22 (12 left and 10 right hip). 17 cases were on failure of extracapsular fracture fixation, while 5 cases were on failure of intracapsular fracture fixation. Extracapsular fracture patterns were as follows: 15 pertrochanteric, 1 intertrochanteric and 1 subtrochanteric fractures. Three kind of fixation device were used: 13 intramedullary nail, 5 extramedullary fixation devices and 4 cannulated screws. Preoperative diagnosis requiring salvage hip replacement were: 12 cephalic screw cut-out, 3 non-union, 4 post-traumatic osteoarthritis, 3 head avascular necrosis. The mean ASA score was 3 (range 1-4). All hip arthroplasty performed on previous conservative treatment were excluded. Minimum considered follow-up was 3 months. (Tabs. 1, 2, 3).

Surgical indication, hip implant and bearing surfaces choices were made by our Department Director (M.L.) with high hip replacement experience. All surgical procedures were performed through a hip direct lateral approach. 6 cases were hip hemiarthroplasty (HA) while 16 cases were total hip arthroplasty (THA).

We evaluated post-operative and follow-up X-rays to detect: stem subsidence, varus-valgus stem position ( $>5^\circ$ ), limb length inequality ( $>1\text{cm}$ ), dislocation, component loosening, heterotopic calcification classified according to Brooker et al., cement leakage (13). At latest follow-up Harris Hip Score and Hip WOMAC Score were performed to evaluate functional outcomes.

## Results

We re-evaluated all patients at the most recent follow-up both radiographically and clinically. We performed 22 hip replacements, 2 patients did not

complete the follow-up because of death onset due to other pathologies. 15 total hip arthroplasties and 5 hip hemiarthroplasties were re-evaluated, mean follow-up was 19.8 months (min 7 months – max 60 months) (Tab. 1).

Given poor bone-stock, patient age and lower surgical time (113 min, range 70 – 180), we implanted all HA as bipolar (metal on polyethylene) and cemented. 3 patients had no complications during follow-up and satisfactory clinical outcome, while 2 (40%) experienced dislocations, consequently one was converted to standard THA and the other one to dual mobility THA. Both revision cases achieved full weight bearing walking and no gait anomalies, x-rays evaluation at latest follow-up highlighted heterotopic calcifica-

**Table 1.** Patients demographics

	HA	THA
Tot. n. (F/M)	6 (5/1)	16 (9/7)
Lat. L/R	4/3	7/5
Surgical time minutes (min. – max.)	113 (70 – 180)	127 (75 – 210)
Follow-up months (min. - max.)	11.2 (5 – 19)	22 (7 – 60)
Follow-up incompleted n.	1	1
ASA (range)	3.2 (3 – 4)	2.8 (1 – 4)
Mean age (min. – max.)	88.2 (80 – 98)	67.6 (26 – 83)

**Table 2.** Failure of devices and conversion to HA and THA

	Nail (HA/THA)	Plate (HA/THA)
Cut-out	10 (4/6)	0 (0/0)
Non-union	0	2 (1/1)
Post-traumatic osteoarthritis	1 (0/1)	2 (0/2)
Total	11 (4/7)	4 (1/3)

**Table 3.** Previous fracture diagnosis and failure diagnosis

Previous Diagnosis.	HA	THA	TOT
Lateral Fractures	5	10	15
Medial Fractures	0	5	5
<b>Failure Diagnosis</b>			
Cut-Out	4	6	10
Non-Union	1	2	3
Post-Traumatic Osteoarthritis.	0	4	4
AVN	0	3	3

tion (Brooker 3) in one patient however, she was asymptomatic (13). 14 patients underwent 15 total hip arthroplasties. Mean operative time was 127 minutes (range 75 – 210). Several kinds of THA have been implanted: 10 cementless primary implant cups, 4 cemented primary implant cups and 1 dual mobility cups, no revision cups were required as a first-choice implant. 4 cementless were press-fit, while 6 were line-to-line and in 5 of them had been added acetabular screws. Due to minimal superior dome bone defect, autologous bone from femoral head was grafted in 2 THA with cementless cup. 3 anatomical stems, 9 single wedge tapered stems, 2 modular metaphyseal-diaphyseal fit stems and 1 cemented stem were used. Head sizes were: 1 28mm diameter head, 5 32mm diameter heads and 9 36mm diameter heads. Bearing surfaces were in 13 of 15 cases ceramic head on polyethylene liner, while in 2 of 15 were metallic head on polyethylene liner however in 1 case Oxidized Zirconium head (Oxinium, Smith and Nephew Memphis, TN, USA) was implanted (Tab. 4).

THA complications were minimal. We reported only 1 periprosthetic infection in dual mobility implant, which was treated by two-stages revision and at latest follow-up it was clinically and radiographically satisfactory. We did not experience any dislocations, limb length discrepancies, loosening and neurovascular deficit. 2 THA developed heterotopic calcification (Brooker 1 and 2) at x-rays evaluation but both asymptomatic. [13] All prosthetic components were properly implanted.

THA functional outcome were overall good: Harris hip Score 86,5 (SD  $\pm$  6,2 range 73.6 – 96) and

WOMAC 91,68 (SD  $\pm$  5,1 range 85.5 – 100); while HA outcomes were poorer highlighting Harris hip Score 65,8 (SD  $\pm$  14,03 range 48,9 – 84,5) and WOMAC 70,18 (SD  $\pm$  13,15 range 53.9 – 87.5).

## Discussion

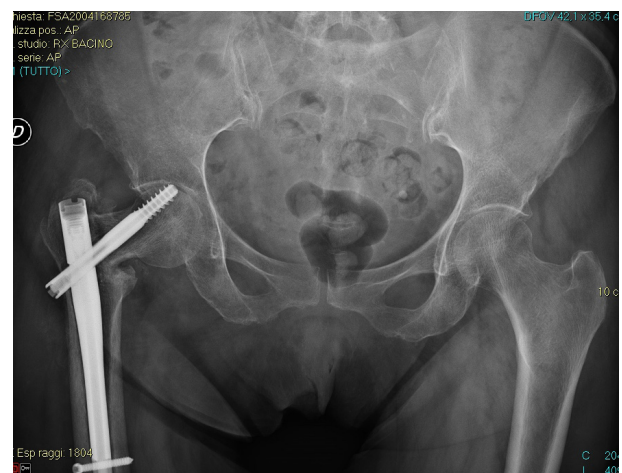Though proximal femur fracture fixation failure rate is quite low 3-12%, it causes important patient disability and its surgical treatment is high demanding requiring an experienced surgeon (5, 7, 14).

Failure fixation salvage surgery could be reosteosynthesis or hip replacement. Literature suggests that hip replacement should be the first choice because of better clinical and functional results, however both procedures have high complications risk, consequently every candidate should be always properly selected before undergoing surgery (15-17).

We reported different kind of fixation failure, such as nail cut-out (Fig. 1), nonunion, post-traumatic osteoarthritis and avascular necrosis, related to different fracture patterns, therefore they present several technical challenges. Hip replacement options are two: hemiarthroplasty or total hip arthroplasty (THA) (Fig. 2). Factors such as: acetabular impairment, age, comorbidities and functional demand should be evaluated to determine whether THA or hemiarthroplasty is the best choice. The treatment of choice for elderly patients is usually hemiarthroplasty because of shorter operative time and smaller blood loss (17-19). In fact,

**Table 4.** THA implants

	Components	Total Number
Cup standard	Standard cementless	10
	Standard cemented	4
	Dual mobility	1
Head size	28mm	1
	32mm	5
	36mm	9
Bearing surfaces	Me-PE	2
	CoP	13
Stem	Anatomic stem	3
	Single wedge tapered stem	9
	Modular stem	2
	Cemented stem	1



**Figure 1.** Femur Cephalo-medullary nail with lag screw cut-out

our study reports a considerable mean age difference 86.4 vs 68.3, shorter operative time 113 minutes vs 127 minutes (Tab. 1). Luthringer et al. outlined different functional outcomes between THA and hemiarthroplasty, in favor of THA, nonetheless complications such as dislocations, revision surgery, intra- and post-operative fracture and stem subsidence have the same rate in both procedures. We experienced more post-operative complications and poorer functional outcomes in HA than THA (19).

Mortazavi et al. pointed out that salvage hip replacement for intracapsular fracture yielded better results and less complications than those for extracapsular fracture. No bone loss is usually associated to intracapsular fracture, consequently primary hip replacement stem is suitable for salvage surgery (18). Even if we registered only 4 THA from medial fracture fixation failure, they outlined excellent results and no complications. Instead, conversion hip replacement for extracapsular fracture failure is a high demanding procedure for surgeons as several technical challenges could be faced: unstable fracture, proximal femoral bone loss, acetabular erosion due to lag screw cut-out, comminuted calcar, as well as difficult implant removal (20-25). Implant selection is crucial for satisfactory results. Intracapsular fracture are usually suitable for primary implant stem, we preferred rectangular tapered stem cementless. Several choices are available for extracapsular fracture failure. Metaphyseal fit stems are recommended when there is a good bone stock and no proximal bone loss. Most of cases we adopted a rectangular tapered stem which ensures

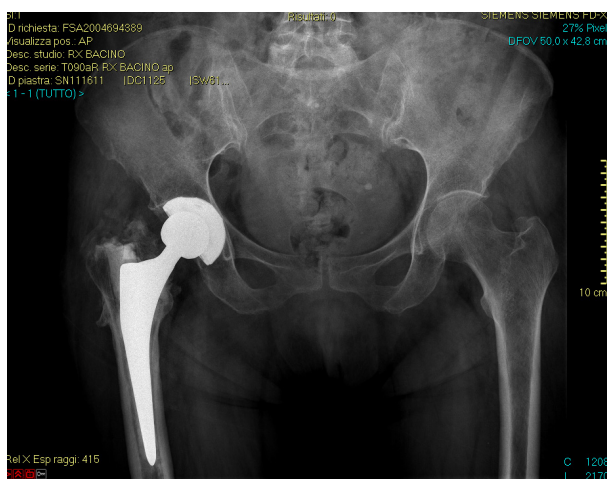
metaphyseal and diaphyseal fit. When metaphyseal bone is compromised, varus or valgus deformity exists, or dislocations risks, or required different neck version, a good alternative is modular stem with diaphyseal fit. Actually, it is possible to modify diaphyseal-neck angle and version allowing to modulate off-set, limb length and implant stability (23, 25-29).

Whenever bone stock quality was not satisfactory, femoral canal shape was type c according to Dorr classification, we preferred cemented stem (30). Primary standard implant acetabular cup is recommended if there is no excessive superior dome bone loss. In 2 cases autologous morcellized bone augmentation was necessary. Surgeon should be aware that press-fit has higher risk of intraoperative fracture than line-to-line fit, we used in 5 cases acetabular screw to add implant stability and implant bone in-growth (17,18).

There is no need for systematic use of cemented stem, modular or revision implants because they are no complication less. There is no evidence in literature to strongly suggest the choice of a particular implant. An interesting option in case of dislocation risk could be dual mobility cup and whenever large bone defect occurs revision implants give an optimal functional and radiographic solutions (16-18, 20, 25-28).

Bearing surfaces are a complex issue nowadays, the most used head material was ceramic in 9 cases while in 3 cases metal on poly was necessary due to small acetabular size. A good alternative to metal head is Oxidized Zirconium which is a metallic material with physical properties similar to ceramic. We always used poly liner because it is safe and it could be coupled with different material head as well. We had no issues related to bearing surfaces (31, 32).

Several complications are reported in literature. The most common one is dislocation, which is often caused by previous surgical approach, compromised hip abductor, insufficient medial offset (17, 25, 28, 29). We had only 1 dislocation in THA. In cases of dislocation, revision surgery is required. Morice et al. reported excellent results with dual mobility cup, noticing an increasing trend as a primary implant in THA after fixation failure in France. Boulat et al. suggest to preserve this option for high risk dislocation patients and to remember raising concerns about adverse local tissue reactions (ALTS) (16, 20).



**Figure 2.** THA after lag screw nail cut-out



Another feared complication is periprosthetic fracture both intraoperative and post-operative, some authors report its rate 0-39% in salvage hip replacement in proximal femur fixation failure, however we did not experience periprosthetic fractures (17, 21-24). Several technical tips are described in literature to reduce intraoperative periprosthetic fracture risk: some authors suggest to dislocate hip before fixation implant removal, other authors prefer to place the stem distally at least 3cm or two times the length of the most distal screw, or preventive metallic cerclage wire on distal screw hole is recommended as well (21-23).

Be aware of periprosthetic infection risk related to all articular replacement surgery. As a salvage hip surgery periprosthetic infection could be a devastating complication especially in elderly patient with poor bone stock and large bone loss, revision surgery could be extremely demolitive (17, 21, 24, 33, 34).

Mahmoud et al. noticed higher complication rate in THA after proximal femur fracture failure fixation compare to primary THA (24). However, DeHaan et al. consider surgical demanding and subsequent operative complications depending more on fixation device than fracture pattern (26).

## Conclusion

Failure of proximal femur fracture osteosynthesis is a rare complication but somewhat challenging and highly disabling for patient. Generally, hip replacement surgery is an optimal option as a salvage surgery in case of failure of proximal femur fracture fixation, granting pain relief and early functional recovery. It is a high demanding surgery because requires experienced and skilled surgeon and higher complication rate compared to primary hip replacement should be reminded and prevented as well (24, 28, 31, 32). Both THA and hemiarthroplasty are good treatment option and possible candidates should be properly evaluated. Although our study has some limitation, we outlined that conversion failed proximal femur fracture fixation to hip replacement is an optimal treatment option, however candidate patients must be evaluated because this surgery presents increase risk of complication and technical challenges.

**Conflict of Interest:** Each author declares that he or she has no commercial associations (e.g. consultancies, stock ownership, equity interest, patent/licensing arrangement etc.) that might pose a conflict of interest in connection with the submitted article

## References

1. Kannus P, Parkkari J, Sievänen H, Heinonen A, Vuori I, Järvinen M. Epidemiology of hip fractures. *Bone*. 1996 Jan;18(1 Suppl):57S-63S.
2. Cummings SR, Rubin SM, Black D. The future of hip fractures in the United States. Numbers, costs, and potential effects of postmenopausal estrogen. *Clin Orthop Relat Res*. 1990 Mar;(252):163-6.
3. Karagas MR, Lu-Yao GL, Barrett JA, Beach ML, Baron JA. Heterogeneity of hip fracture: age, race, sex, and geographic patterns of femoral neck and trochanteric fractures among the US elderly. *Am J Epidemiol*. 1996 Apr 1;143(7):677-82.
4. Veronese N, Maggi S. Epidemiology and social costs of hip fracture. *Injury*. 2018 Aug;49(8):1458-1460.
5. Fernandez MA, Griffin XL, Costa ML. Management of hip fracture. *Br Med Bull*. 2015 Sep;115(1):165-72.
6. Pincus D, Ravi B, Wasserstein D, et al. Association Between Wait Time and 30-Day Mortality in Adults Undergoing Hip Fracture Surgery. *JAMA*. 2017;318(20):1994-2003.
7. Evaniew N, Bhandari M. Cochrane in CORR®: Intramedullary nails for extracapsular hip fractures in adults (review). *Clin Orthop Relat Res*. 2015;473(3):767-774.
8. Socci AR, Casemyr NE, Leslie MP, Baumgaertner MR. Implant options for the treatment of intertrochanteric fractures of the hip: rationale, evidence, and recommendations. *Bone Joint J*. 2017;99-B(1):128-133.
9. Lu Y, Uppal HS. Hip Fractures: Relevant Anatomy, Classification, and Biomechanics of Fracture and Fixation. *Geriatr Orthop Surg Rehabil*. 2019;10:2151459319859139.
10. Florschutz AV, Langford JR, Haidukewych GJ, Koval KJ. Femoral neck fractures: current management. *J Orthop Trauma*. 2015;29(3):121-129.
11. Parker MJ, Gurusamy K. Internal fixation versus arthroplasty for intracapsular proximal femoral fractures in adults. *Cochrane Database Syst Rev*. 2006;(4):CD001708.
12. Dix DB, Araoye IB, Staggers JR, et al. A systematic review and meta-analysis of complications in conversion arthroplasty methods for failed intertrochanteric fracture fixation. *J Clin Orthop Trauma*. 2019;10(2):282-285.
13. Brooker AF, Bowerman JW, Robinson RA, Riley LH Jr. Ectopic ossification following total hip replacement. Incidence and a method of classification. *J Bone Joint Surg Am*. 1973 Dec;55(8):1629-32
14. Matre K, Havelin LI, Gjertsen JE, Vinje T, Espehaug B, Fevang JM. Sliding hip screw versus IM nail in reverse oblique trochanteric and subtrochanteric fractures. A study of 2716 patients in the Norwegian Hip Fracture Register. *Injury*. 2013;44(6):735-742.

15. Brunner A, Büttler M, Lehmann U, et al. What is the optimal salvage procedure for cut-out after surgical fixation of trochanteric fractures with the PFNA or TFN?: A multi-centre study. *Injury*. 2016;47(2):432-438.
16. Morice A, Ducellier F, Bizot P; Orthopaedics and Traumatology Society of Western France (SOO). Total hip arthroplasty after failed fixation of a proximal femur fracture: Analysis of 59 cases of intra- and extra-capsular fractures. *Orthop Traumatol Surg Res*. 2018;104(5):681-686.
17. Krause PC, Braud JL, Whatley JM. Total hip arthroplasty after previous fracture surgery. *Orthop Clin North Am*. 2015;46(2):193-213.
18. Mortazavi SM, R Greenky M, Bican O, Kane P, Parvizi J, Hozack WJ. Total hip arthroplasty after prior surgical treatment of hip fracture is it always challenging?. *J Arthroplasty*. 2012;27(1):31-36.
19. Luthringer TA, Elbuluk AM, Behery OA, Cizmiz Z, Deshmukh AJ. Salvage of failed internal fixation of intertrochanteric hip fractures: clinical and functional outcomes of total hip arthroplasty versus hemiarthroplasty. *Arthroplast Today*. 2018;4(3):383-391..
20. Boulat S, Neri T, Boyer B, Philippot R, Farizon F. Dual mobility cups in total hip arthroplasty after failed internal fixation of proximal femoral fractures. *Orthop Traumatol Surg Res*. 2019;105(3):491-495.
21. Archibeck MJ, Carothers JT, Tripuraneni KR, White RE Jr. Total hip arthroplasty after failed internal fixation of proximal femoral fractures. *J Arthroplasty*. 2013;28(1):168-171.
22. Angelini M, McKee MD, Waddell JP, Haidukewych G, Schemitsch EH. Salvage of failed hip fracture fixation. *J Orthop Trauma*. 2009;23(6):471-478.
23. Chen DW, Lin CL, Hu CC, Tsai MF, Lee MS. Biomechanical consideration of total hip arthroplasty following failed fixation of femoral intertrochanteric fractures - a finite element analysis. *Med Eng Phys*. 2013;35(5):569-575
24. Smith A, Denehy K, Ong KL, Lau E, Hagan D, Malkani A. Total hip arthroplasty following failed intertrochanteric hip fracture fixation treated with a cephalomedullary nail. *Bone Joint J*. 2019;101-B(6\_Supple\_B):91-96.
25. Mahmoud SS, Pearse EO, Smith TO, Hing CB. Outcomes of total hip arthroplasty, as a salvage procedure, following failed internal fixation of intracapsular fractures of the femoral neck: a systematic review and meta-analysis. *Bone Joint J*. 2016;98-B(4):452-460.
26. DeHaan AM, Groat T, Priddy M, et al. Salvage hip arthroplasty after failed fixation of proximal femur fractures. *J Arthroplasty*. 2013;28(5):855-859.
27. Neri T, Philippot R, Klasan A, et al. Dual mobility acetabular cups for total hip arthroplasty: advantages and drawbacks. *Expert Rev Med Devices*. 2018;15(11):835-845
28. D'Arrigo C, Perugia D, Carcangiu A, Monaco E, Speranza A, Ferretti A. Hip arthroplasty for failed treatment of proximal femoral fractures. *Int Orthop*. 2010;34(7):939-942.
29. Tetsunaga T, Fujiwara K, Endo H, et al. Total hip arthroplasty after failed treatment of proximal femur fracture. *Arch Orthop Trauma Surg*. 2017;137(3):417-424.
30. Dorr LD, Faugere MC, Mackel AM, Gruen TA, Bogner B, Malluche HH. Structural and cellular assessment of bone quality of proximal femur. *Bone*. 1993 May-Jun;14(3):231-42.
31. Lachiewicz PF, Kleeman LT, Seyler T. Bearing Surfaces for Total Hip Arthroplasty. *J Am Acad Orthop Surg*. 2018;26(2):45-57.
32. Zagra L, Gallazzi E. Bearing surfaces in primary total hip arthroplasty. *EFORT Open Rev*. 2018;3(5):217-224..
33. Müller F, Galler M, Zellner M, Bäuml C, Füchtmeier B. Total hip arthroplasty after failed osteosynthesis of proximal femoral fractures: Revision and mortality of 80 patients. *J Orthop Surg (Hong Kong)*. 2017;25(2):2309499017717869.
34. Winemaker M, Gamble P, Petruccioli D, Kaspar S, de Beer J. Short-term outcomes of total hip arthroplasty after complications of open reduction internal fixation for hip fracture. *J Arthroplasty*. 2006;21(5):682-688.

Received: 24 October 2020

Accepted: 5 November 2020

Correspondence:

Nicola Corradi, MD

Department of Orthopaedic and Traumatology, Azienda Ospedaliero-Universitaria di Ferrara

Viale Aldo Moro, 8

Ferrara, 44124 Italy

Phone: +39 3331951878.

E-mail: nicola.corradi@alice.it