Case Reports in Ophthalmology

Case Rep Ophthalmol 2026;17:610–618
DOI: 10.1159/000551992
Received: January 23, 2026
Accepted: April 3, 2026
Published online: May 5, 2026

© 2026 The Author(s).
Published by S. Karger AG, Basel
www.karger.com/cop

OPEN ACCESS

This article is licensed under the Creative Commons Attribution-NonCommercial 4.0 International License (CC BY-NC) (https://karger.com/Services/OpenAccessLicense). Usage and distribution for commercial purposes requires written permission.

Case Report

Radial Optic Neurotomy for Progressive Visual Field Loss Associated with Optic Nerve Head Drusen: A Case Report

Chiara Vivarelli[a] Paola Ferri[b] Marco Pellegrini[a, c, d]
Ginevra Giovanna Adamo[a, c] Pietro Maria Talli[a] Carla Enrica Gallenga[a]
Francesco Parmeggiani[a, c] Marco Mura[a, c, e]

[a]Ophthalmology Clinic Operating Unit, Head and Neck Department, Arcispedale Sant'Anna University Hospital, Ferrara, Italy; [b]Department of Biomedical Metabolic and Neural Sciences, University of Modena and Reggio Emilia, Modena, Italy; [c]Department of Translational Medicine, University of Ferrara, Ferrara, Italy; [d]Department of Ophthalmology, Ospedali Privati Forlì "Villa Igea", Forlì, Italy; [e]Department of Vitreoretinal and Uveitis Divisions, King Khaled Eye Specialist Hospital, Riyadh, Saudi Arabia

Keywords
Optic nerve head drusen · Radial optic neurotomy · Visual field loss · Optic neuropathy

Abstract
Introduction: The aim of this study was to report the use of radial optic neurotomy (RON) as an experimental surgical approach for progressive visual field loss associated with extensive bilateral optic nerve head drusen (ONHD). ***Case Presentation:*** A 27-year-old female with extensive bilateral ONHD presented with rapidly progressive and severe concentric visual field loss, more severe in the left eye, despite normal intraocular pressure and topical hypotensive therapy. Multimodal imaging confirmed ONHD with significant retinal nerve fiber layer thinning and severe concentric visual field loss sparing central vision in the left eye. RON was performed at the nasal edge of the optic disc without complications. ***Conclusion:*** RON may represent a potential therapeutic option in carefully selected young patients with ONHD and progressive, severe visual field loss. Further studies are required to establish optimal timing, appropriate indications, and long-term outcomes.

© 2026 The Author(s).
Published by S. Karger AG, Basel

Introduction

Optic nerve head drusen (ONHD) are acellular, calcified deposits located within the optic nerve head, resulting from deranged axonal metabolism and transport, with subsequent axonal damage in the setting of a small scleral canal [1]. The reported prevalence ranges

Correspondence to:
Chiara Vivarelli, chia.vivarelli@gmail.com

Downloaded from karger.com/cop/article-pdf/17/1/610/4534594/000551992.pdf by guest on 17 November 2026

Case Rep Ophthalmol 2026;17:610–618
DOI: 10.1159/000551992
© 2026 The Author(s). Published by S. Karger AG, Basel
www.karger.com/cop

from 3.4 to 24 per 1,000 individuals [1, 2]. Although ONHD are often asymptomatic, they have been associated with progressive visual field loss, particularly in younger patients and in cases of superficial, visible drusen, with visual field defects reported in 24-87% of affected individuals [1, 3]. Central vision involvement is rare in these patients. Nonetheless, patients with ONHD are at increased risk of ischemic optic neuropathy due to a small optic disc size and a narrow optic nerve canal, leading to distortion of prelaminar and laminar vasculature and compression of optic nerve fibers, which predispose to relative vascular insufficiency [4, 5]. To date, no established treatment exists to halt or reverse ONHD-associated axonal damage [1]. Topical intraocular pressure-lowering agents are sometimes prescribed in an attempt to reduce pressure on the optic nerve fibers; however, evidence supporting their efficacy is limited [1]. Radial optic neurotomy (RON) was originally described as a surgical approach for central retinal vein occlusion, aiming to decompress the scleral outlet compartment [6]. Its application in ONHD-associated optic neuropathy is experimental, with only a limited number of cases reported in the literature [7–10]. In the absence of effective therapeutic alternatives, RON was performed in a patient with severe, progressive visual field constriction threatening central vision.

Case Presentation

A 27-year-old woman with a known diagnosis of bilateral ONHD had been followed at our clinic for several years (shown in Fig. 1a). During follow-up, a progressive deterioration of the visual field in the left eye was documented in the absence of other ocular pathology or systemic comorbidities. Best-corrected visual acuity was 20/20 in the right eye and 20/22 in the left eye. Intraocular pressure measured by applanation tonometry was 14 mm Hg in the right eye and 13 mm Hg in the left eye. In an effort to optimize ocular perfusion pressure, the patient was treated with topical dorzolamide hydrochloride-timolol maleate (Cosopt®) twice daily in both eyes. She was not receiving citicoline supplementation. Blue-light fundus autofluorescence imaging revealed multiple, well-defined bright hyperautofluorescent foci within the optic nerve head of both eyes, consistent with ONHD (shown in Fig. 1b). Infrared imaging demonstrated granular hyperreflective foci within the optic discs, irregular disc margins, and the characteristic "lumpy-bumpy" contour (online suppl. Fig. S1; for all online suppl. material, see https://doi.org/10.1159/000551992). Spectral-domain optical coherence tomography (SD-OCT; Spectralis, Heidelberg Engineering, Germany) analysis documented severe thinning of the retinal nerve fiber layer (RNFL) in both eyes, more pronounced in the left eye (shown in Fig. 1c). Automated perimetry of the right eye revealed an inferior arcuate scotoma (shown in Fig. 2a), whereas visual field testing of the left eye demonstrated a severe concentric scotoma with relative preservation of central vision (shown in Fig. 2b). Considering the documented progressive visual field deterioration in both eyes relative to the examination performed at age 24 (online suppl. Fig. S2), and despite preserved central visual acuity with no alternative effective treatments available, a surgical decompressive approach was considered to prevent further functional loss in the more severely affected eye. After obtaining written informed consent, a standard 23-gauge three-port pars plana vitrectomy followed by RON was performed in the left eye under sub-Tenon anesthesia by an experienced vitreoretinal surgeon (M.M.). To minimize intraoperative bleeding, intraocular pressure was transiently elevated to 70 mm Hg for 15 s. Access to the vitreous chamber was obtained using a 20-gauge myringotome. A 20-gauge neurotomy knife with sharp and blunt edges at the tip (Opremcak CRVO, Synergetics by Bausch & Lomb®) was used. As previously described by Opremcak et al. [6], the neurotomy was performed at the

Downloaded from karger.com/cop/article-pdf/17/1/610/4534594/000551992.pdf by guest on 17 November 2026

Case Rep Ophthalmol 2026;17:610–618
DOI: 10.1159/000551992
© 2026 The Author(s). Published by S. Karger AG, Basel
www.karger.com/cop

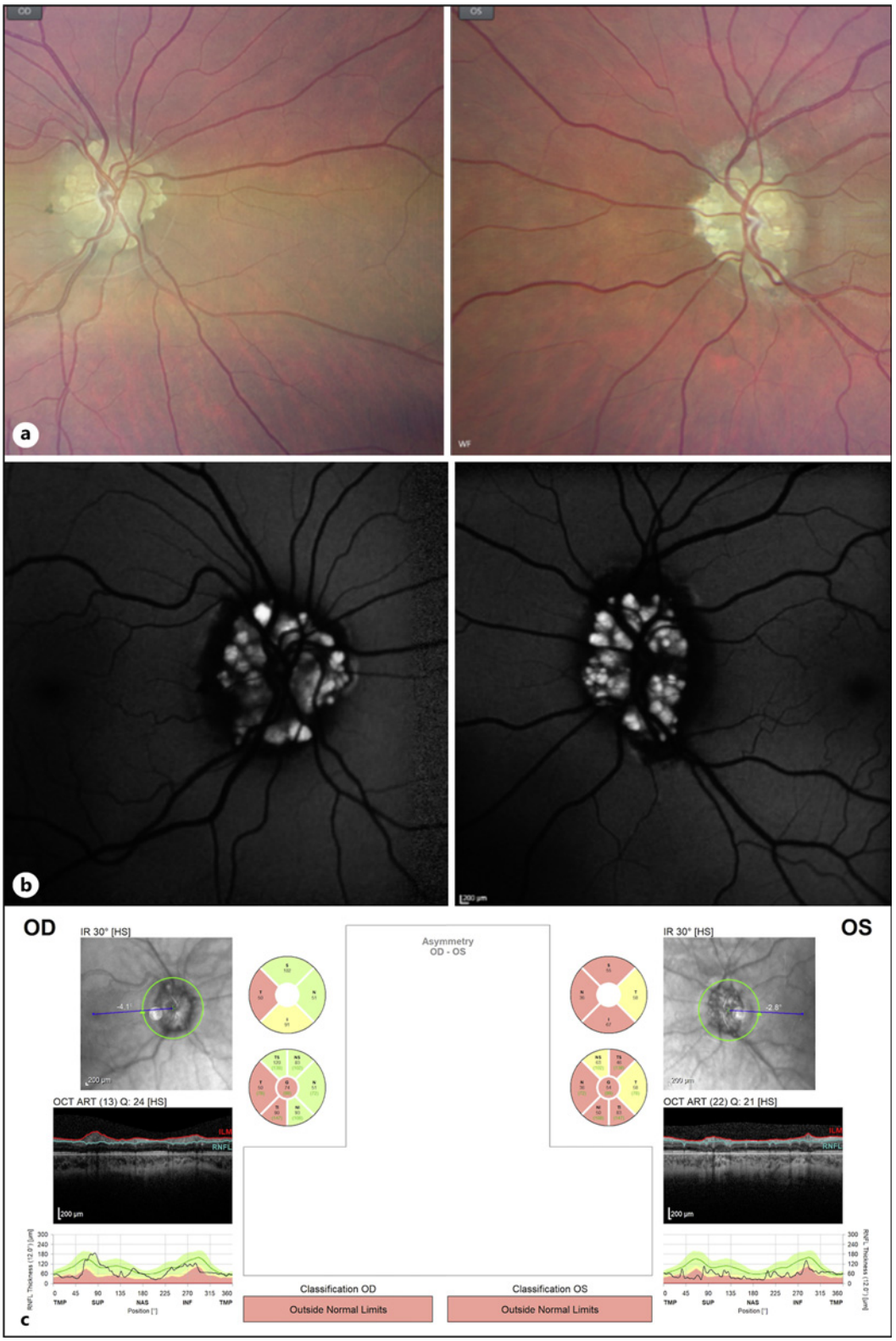

Fig. 1. **a** Color fundus imaging showing visible ONHD. **b** Fundus autofluorescence imaging demonstrating multiple hyperautofluorescent foci within the optic nerve head of both eyes. **c** SD-OCT RNFL analysis demonstrating thinning of the peripapillary RNFL, more pronounced in the left eye.

Downloaded from karger.com/cop/article-pdf/17/1/610/4534594/000551992.pdf by guest on 17 November 2026

Case Rep Ophthalmol 2026;17:610–618
DOI: 10.1159/000551992
© 2026 The Author(s). Published by S. Karger AG, Basel
www.karger.com/cop

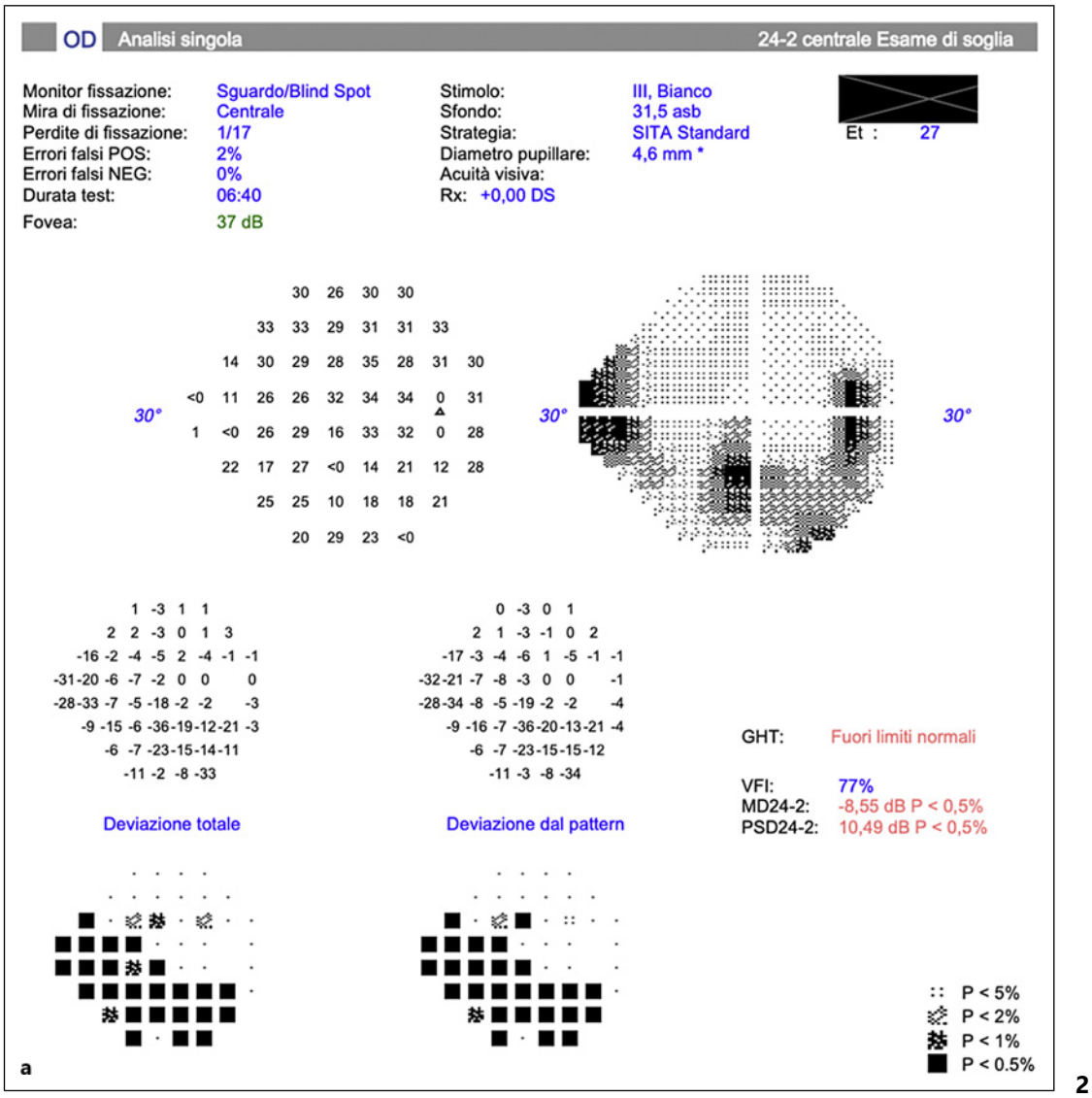

2

(Figure continued on next page.)

nasal edge of the optic disc to reduce the risk of injury to the papillomacular nerve fiber bundle and to minimize the likelihood of subretinal hemorrhage at this location. Radial orientation of the incision relative to the optic disc was chosen to facilitate separation of nerve fibers without transection. The clock-hour location was selected to minimize the risk of vascular injury while providing access to the central portion of the optic disc. Positioned at the optic disc margin with its sharp edge directed peripherally, the microretinal blade was advanced posteriorly into the optic nerve to a depth just beyond the maximal tip width, reaching the 2-mm marker. Two radial incisions were performed to achieve a more uniform distribution of decompressive forces, each involving equal portions of the lamina cribrosa and adjacent sclera. No lateral slicing movements were used. Openings at the optic disc were observed. A mild, localized hemorrhage occurred at the incision site without extension into the subretinal space or vitreous cavity and resolved spontaneously. No other intraoperative complications were noted, and no intraocular tamponade was used. The surgical procedure is shown in online suppl. Video S1.

Downloaded from karger.com/cop/article-pdf/17/1/610/4534594/000551992.pdf by guest on 17 November 2026

Case Rep Ophthalmol 2026;17:610–618
DOI: 10.1159/000551992
© 2026 The Author(s). Published by S. Karger AG, Basel
www.karger.com/cop

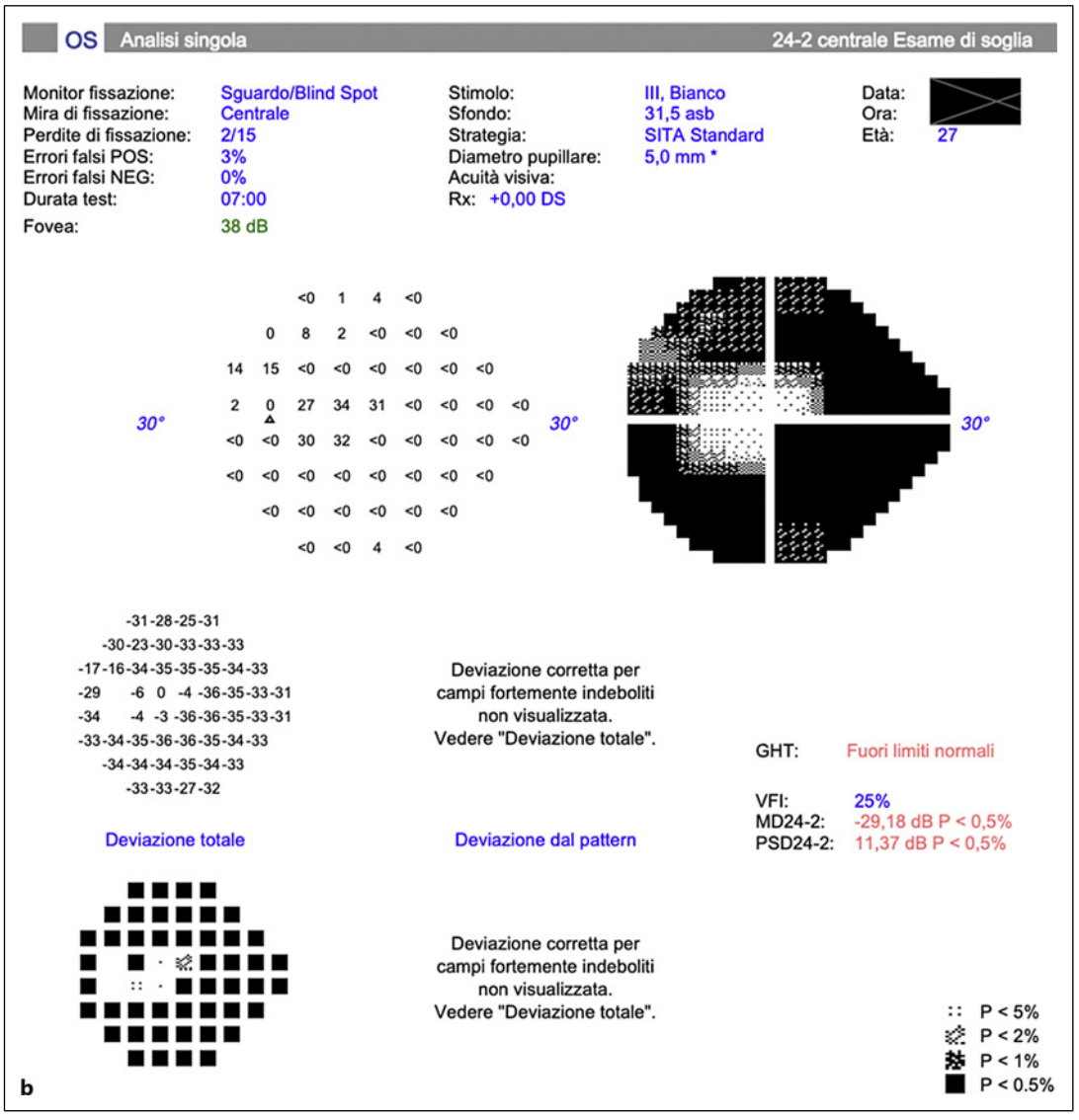

Fig. 2. a Humphrey visual field 24-2 (SITA Standard) of the right eye demonstrating a moderate-to-severe dense arcuate visual field defect predominantly involving the inferior hemifield, with extension toward the nasal and central regions. **b** Humphrey visual field 24-2 (SITA Standard) of the left eye demonstrating severe concentric field depression with near-total field suppression beyond central fixation and minimal isolated island of residual function.

At the first postoperative follow-up visit, 3 weeks after surgery, best-corrected visual acuity in the left eye improved to 20/20. Automated perimetry demonstrated stable visual field parameters, with no evidence of retinal or optic nerve complications. Notably, the stability of visual field findings in the operated eye was maintained at 18 months postoperatively (shown in Fig. 3b), whereas progressive visual field deterioration was observed in the fellow eye (shown in Fig. 3a). On SD-OCT imaging, the incision site is visible as a focal area of atrophy (online suppl. Fig. S3). Postoperative optical coherence tomography angiography of the optic nerve head, with specific analysis of the radial peripapillary capillary layer using a 4.5 × 4.5 mm scan, demonstrated reduced

Downloaded from karger.com/cop/article-pdf/17/1/610/4534594/000551992.pdf by guest on 17 November 2026

Case Rep Ophthalmol 2026;17:610–618
DOI: 10.1159/000551992
© 2026 The Author(s). Published by S. Karger AG, Basel
www.karger.com/cop

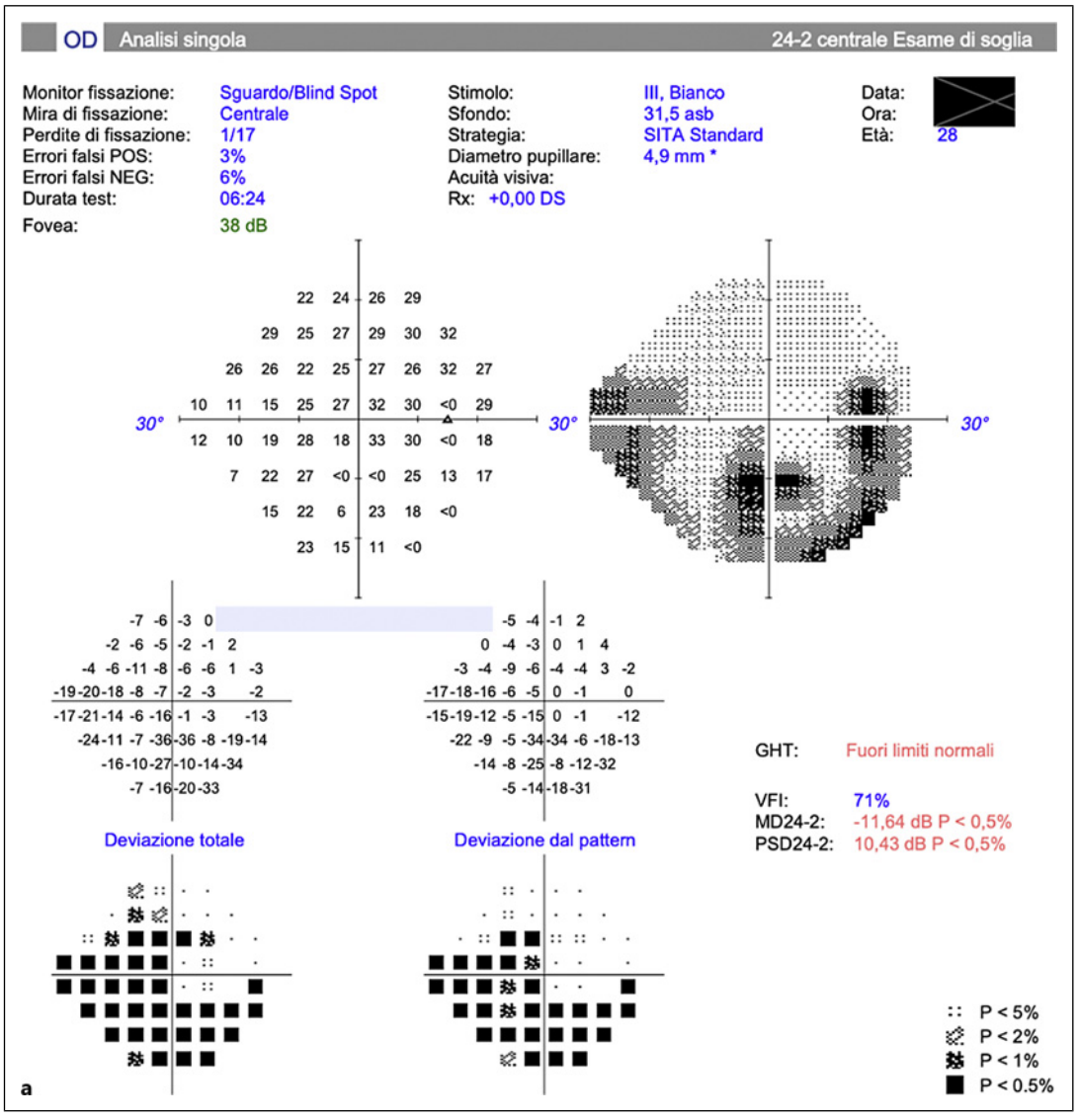

3

(Figure continued on next page.)

peripapillary vessel density and sectoral capillary dropout in both eyes (online suppl. Fig. S4, S5). The CARE Checklist has been completed by the authors for this case report, attached as online supplementary material.

Discussion

There is currently no standardized treatment for patients with ONHD, and experience with surgical management is limited [1, 3]. Optic nerve sheath decompression has been reported in a small series but is invasive and of uncertain benefit [11], while surgical excision of ONHD has been associated with vision loss [12, 13]. To relieve neurovascular compression, RON was proposed as a potential surgical approach for ONHD in an initial report by Haritoglou et al. [7]. In our case, consistent with the findings of Nentwich et al. [8], preoperative visual acuity was preserved with slight improvement,

Downloaded from karger.com/cop/article-pdf/17/1/610/4534594/000551992.pdf by guest on 17 November 2026

Case Rep Ophthalmol 2026;17:610–618
DOI: 10.1159/000551992
© 2026 The Author(s). Published by S. Karger AG, Basel
www.karger.com/cop

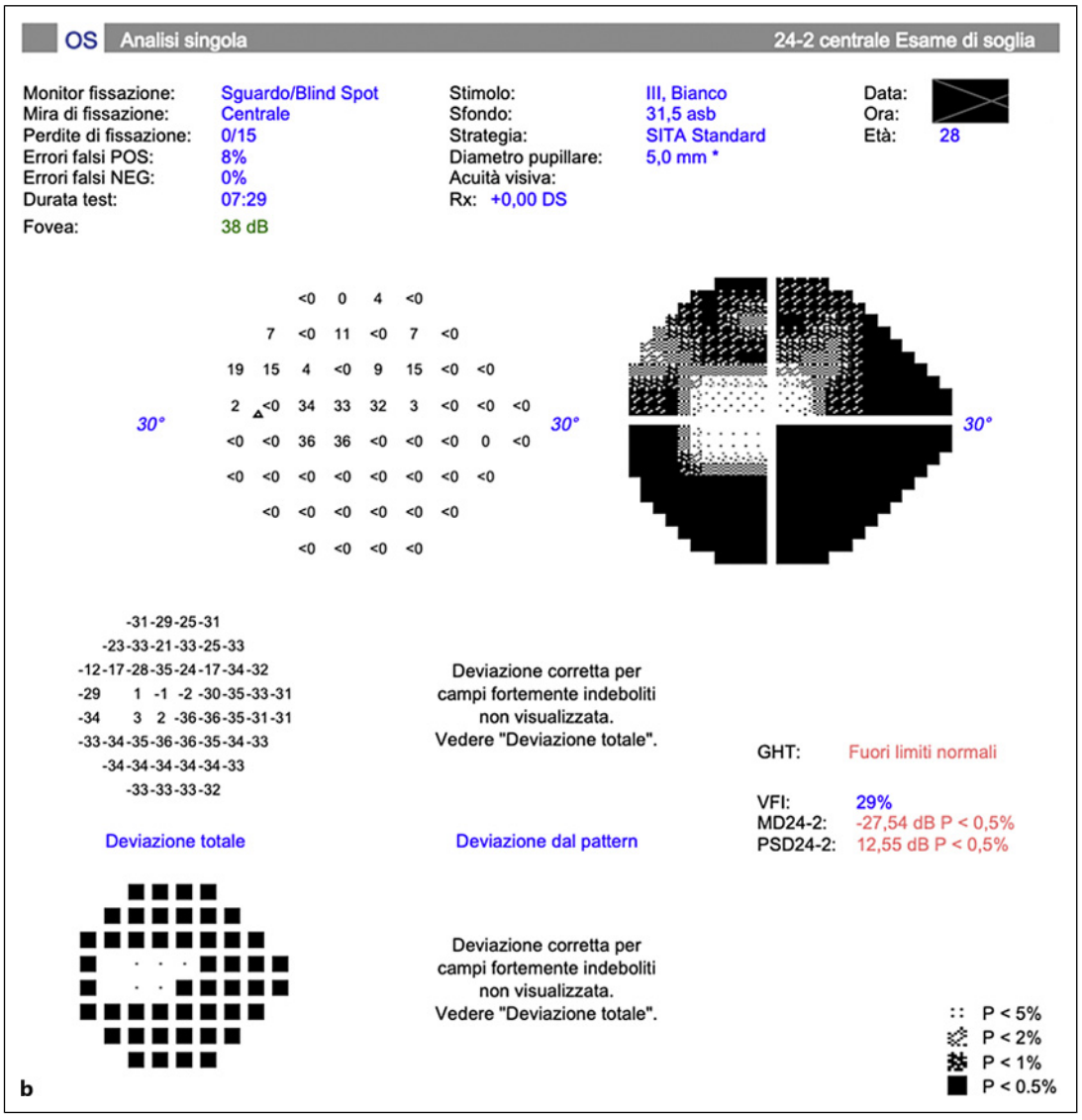

Fig. 3. a Automated perimetry of the right eye (untreated) showing progression compared with the previous examination performed 18 months earlier, with worsening of the inferior arcuate defect and a reduction in mean deviation and visual field index. **b** Postoperative automated perimetry of the left eye showing advanced, diffuse visual field loss, with stabilization of the mean deviation and visual field index.

and stabilization of the visual field was achieved during follow-up, whereas the untreated fellow eye showed continued visual field deterioration; notably, no procedure-related complications were observed. Histopathological studies in human specimens have demonstrated the technical feasibility of radially introducing a microretinal blade at the nasal margin of the optic disc to incise the lamina cribrosa, scleral rim, and adjacent sclera, with advancement into the intraocular portion of the optic nerve without anatomical perforation of the globe or optic nerve sheath [6, 14]. Although the use of RON has declined in the management of central retinal vein occlusion, its proposed ability to reduce peripapillary compartment pressure makes it a potentially appealing option in ONHD-associated optic neuropathy, both in cases of recent rapid visual field

Downloaded from karger.com/cop/article-pdf/17/1/610/4534594/000551992.pdf by guest on 17 November 2026

deterioration and in long-standing visual field loss, as well as for the prevention of anterior ischemic optic neuropathy. Given the potential for serious adverse events associated with deep incisions, which may result in additional visual field defects, careful patient selection is essential, and further studies are needed to better define the indications, timing, and standardization of the surgical technique.

Conclusion

In the absence of effective alternative treatments, optic nerve decompression by RON may be considered as a potential option to halt further progression of visual field loss and preserve preoperative visual acuity in carefully selected patients with ONHD at high risk of permanent visual impairment. Given the limited clinical experience with RON in this setting, this case underscores the need for further investigation to clarify its optimal timing, appropriate indications, and long-term outcomes.

Statement of Ethics

This case report did not require ethical approval in accordance with local/national guidelines. Written informed consent was obtained from the patient for publication of the details of this case report, any accompanying images and surgical video.

Conflict of Interest Statement

The authors have no conflicts of interest to declare.

Funding Sources

This study was not supported by any sponsor or funder.

Author Contributions

C.V., M.M.: conceptualization, methodology, investigation and data curation, visualization, writing (original draft), and writing (reviewing and editing). P.F., M.P., G.G.A., P.M.T., C.E.G., and F.P.: data curation and writing (reviewing and editing). All authors have read and agreed to the published version of the manuscript.

Data Availability Statement

All data generated or analyzed during this study are included in this article and its online supplementary material. Further inquiries can be directed to the corresponding author.

Downloaded from karger.com/cop/article-pdf/17/1/610/4534594/000551992.pdf by guest on 17 November 2026

References

1 Auw-Haedrich C, Staubach F, Witschel H. Optic disk drusen. Surv Ophthalmol. 2002;47(6):515–32. https://doi.org/10.1016/s0039-6257(02)00357-0
2 Hamann S, Malmqvist L, Costello F. Optic disc drusen: understanding an old problem from a new perspective. Acta Ophthalmol. 2018;96(7):673–84. https://doi.org/10.1111/aos.13748
3 Palmer E, Gale J, Crowston JG, Wells AP. Optic nerve head drusen: an update. Neuroophthalmology. 2018;42(6):367–84. https://doi.org/10.1080/01658107.2018.1444060
4 Gittinger JW Jr, Lessell S, Bondar RL. Ischemic optic neuropathy associated with optic disc drusen. J Clin Neuroophthalmol. 1984;4(2):79–84.
5 Jonas JB, Gusek GC, Naumann GO. Anterior ischemic optic neuropathy: nonarteritic form in small and giant cell arteritis in normal sized optic discs. Int Ophthalmol. 1988;12(2):119–25. https://doi.org/10.1007/BF00137137
6 Opremcak EM, Bruce RA, Lomeo MD, Ridenour CD, Letson AD, Rehmar AJ. Radial optic neurotomy for central retinal vein occlusion: a retrospective pilot study of 11 consecutive cases. Retina. 2001;21(5):408–15. https://doi.org/10.1097/00006982-200110000-00002
7 Haritoglou C, Prieglinger SG, Grueterich M, Kampik A, Kriegelstein GK. Radial optic neurotomy for the treatment of acute functional impairment associated with optic nerve drusen. Br J Ophthalmol. 2005;89(6):779–80. https://doi.org/10.1136/bjo.2004.060335
8 Nentwich MM, Remy M, Haritoglou C, Kampik A. Radial optic neurotomy to treat patients with visual field defects associated with optic nerve drusen. Retina. 2011;31(3):612–5. https://doi.org/10.1097/IAE.0b013e318209b748
9 Pinxten I, Stalmans P. Radial optic neurotomy as a treatment for anterior ischemic optic neuropathy secondary to optic disc drusen. GMS Ophthalmol Cases. 2014;4:Doc05. https://doi.org/10.3205/oc000018
10 Vandebroek AC, Emmerich C, Rickmann A, Macek MA, Szurman P. Radiäre Optikusneurotomie bei Drusenpapille [Radial optic neurotomy with optic disc drusen]. Ophthalmologe. 2021;118(11):1143–5. German. https://doi.org/10.1007/s00347-020-01258-4
11 Jirásková N, Rozsíval P. Dekomprese obalů zrakového nervu: výsledky u prvních 37 operovaných ocí [decompression of the optic nerve sheath – results in the first 37 operated eyes]. Cesk Slov Oftalmol. 1996;52(5):297–307.
12 Kapur R, Pulido JS, Abraham JL, Sharma M, Buerk B, Edward DP. Histologic findings after surgical excision of optic nerve head drusen. Retina. 2008;28(1):143–6. https://doi.org/10.1097/IAE.0b013e31815e98d8
13 Pfriem M, Hoerauf H. Unsuccessful surgical excision of optic nerve drusen. Graefes Arch Clin Exp Ophthalmol. 2011;249(10):1583–5. https://doi.org/10.1007/s00417-011-1693-x
14 Opremcak EM, Rehmar AJ, Ridenour CD, Kurz DE. Radial optic neurotomy for central retinal vein occlusion: 117 consecutive cases. Retina. 2006;26(3):297–305. https://doi.org/10.1097/00006982-200603000-00008

Downloaded from karger.com/cop/article-pdf/17/1/610/4534594/000551992.pdf by guest on 17 November 2026