


Phenotypic heterogeneity of COVID-19 pneumonia: clinical and pathophysiological relevance of the vascular phenotype^a

Matteo Bertini^{1*} , Emanuele D'Aniello¹, Luca Di Lenno¹, Federico Gibiino¹, Guido Tavazzi², Carlo Alberto Volta³, Marco Contoli⁴, Alberto Papi⁴, Gianluca Campo¹, Roberto Ferrari⁵ and Claudio Rapezzi^{1,5}

¹Cardiological Center, Translational Medicine Department, University of Ferrara, Ferrara, Italy; ²Anesthesia and Intensive Care, Fondazione Policlinico San Matteo Hospital IRCCS, Pavia, Italy; ³Section of Anaesthesia and Intensive Care Medicine, University of Ferrara, Ferrara, Italy; ⁴Malattie dell'Apparato Respiratorio, Dipartimento di Morfologia, Chirurgia e Medicina Sperimentale, University of Ferrara, Ferrara, Italy; and ⁵Maria Cecilia Hospital, GVM Care & Research, Cotignola, Italy

Recent data support the existence of a distinctive 'vascular' phenotype with the involvement of both pulmonary parenchyma and its circulation in COVID-19 pneumonia. Its prompt identification is important for the accurate management of COVID-19 patients. The aim is to analyse the pro and contra of the different modalities to identify the 'vascular' phenotype. Chest computed tomography scan and angiogram may quantify both parenchyma and vascular damage, but the presence of thrombosis of pulmonary microcirculation may be missed. Increased D-dimer concentration confirms a thrombotic state, but it cannot localize the thrombus. An elevation of troponin concentration non-specifically reflects cardiac injury. Echocardiogram and electrocardiogram provide specific signs of right ventricular pressure overload. This is particularly relevant for the 'vascular' phenotype, which does not necessarily represent the result of thrombo-embolic venous complications, but more frequently, it is the result of pulmonary microcirculation thrombosis *in situ* and needs immediate therapeutic action.

Condensed abstract Despite diagnosis of the 'vascular' phenotype of COVID-19 pneumonia may be subtle, the evidence indicates a reasonable possibility of identifying it already in the initial stage of the infection. Chest computed tomography scan and angiogram, increased D-dimer concentration, and elevation of troponin concentration may be not sufficient to identify 'vascular' phenotype. Echocardiogram and electrocardiogram provide specific signs of right ventricular pressure overload. This is particularly relevant for the 'vascular' phenotype, which does not necessarily represent the result of thrombo-embolic venous complications, but more frequently, it is the result of pulmonary microcirculation thrombosis *in situ* and needs immediate therapeutic action.

Keywords COVID-19; Vascular phenotype; ECG

Received: 4 August 2021; Accepted: 19 August 2021

*Correspondence to: Matteo Bertini, Cardiological Center, Translational Medicine Department, University of Ferrara, Via Aldo Moro, 8-44124 Cona, Ferrara, Italy. Tel: +39 0532236269; Fax: +39 0532236593. Email: doc.matber@gmail.com

Towards the concept of vascular phenotype in COVID-19 pneumonia

Several studies have unveiled a great heterogeneity of COVID-19 pneumonia, and from clinical and pathophysiological point of view, the spectrum of the pulmonary involvement ranges from mild flu-like symptoms to a devastating rapid progression of the respiratory distress.¹ Recent data support the existence of a distinctive 'vascular' phenotype with the involvement of both pulmonary parenchyma and its

circulation in COVID-19 pneumonia.² Awareness of such 'vascular' phenotype and its prompt identification is important for the comprehensive and accurate management of COVID-19 patients. There are several clinical and instrumental variables that may raise the alert and are the grounds for diagnosis of the 'vascular' phenotype.

The aim is to analyse the pro and contra of the different modalities to identify the 'vascular' phenotype of COVID-19 pneumonia with emphasis on the contribution of the cardiovascular tools.

Pathological observations

The first autopsic studies reported the presence of microangiopathic, haemorrhagic, and thrombotic phenomena in the lungs of critically ill COVID-19 patients, in addition to alveolar/interstitial diffuse oedema, consistent with acute respiratory distress syndrome (ARDS). Ackermann *et al.*³ found that COVID-19 patients and those with influenza A H1N1 share the morphological pattern of diffuse alveolar damage and infiltrating perivascular lymphocytes. More precisely, they presented three angiocentric features: (i) severe endothelial injury with intracellular presence of SARS-CoV-2 virus, (ii) widespread vascular thrombosis with microangiopathy and occlusion of alveolar capillaries, and (iii) new vessel growth through a mechanism of intussusceptive angiogenesis. These observations are, in part, shared with those reported by Wichmann *et al.* of high incidence of thrombo-embolic events (about one-third of the patients), suggesting an important role of COVID-19-induced coagulopathy.⁴ In another series of autopsies,⁵ high D-dimer levels were associated with the presence of microvascular thrombosis (retiform purpura o livedo racemose) and SARS-CoV-2 glycoprotein, both in the lungs and in the skin. Furthermore, the detection of macrovascular and microvascular thrombosis (on arterial and venous sides) both in 'red' form, made up of erythrocytes, leucocytes, and fibrin, and in 'white' form, constituted by platelets and fibrin, were common findings amongst several reports.⁶ In a selected COVID-19 population, Basso *et al.*⁷ found myocardial interstitial macrophage infiltration in 84% of myocardium specimen, but only in three cases there was a true multifocal lymphocytic myocarditis. They also described signs of right ventricular (RV) strain probably related to pulmonary circulation involvement, in 19% of autopsies. Finally, Bussani *et al.* reported the systematic analysis of 41 consecutive autopsies of COVID-19 patients showing not only the extensive alveolar damage in 100% of the patients but also the thrombosis of pulmonary microcirculation and macrocirculation in 71% of the patients. These authors described a minor involvement of other organs including the heart.⁸ Taken together, all these observations suggest an involvement of the lung circulation in COVID-19 pneumonia.

Imaging of the lung

Chest computed tomography scan

The most common presentation of chest computed tomography (CT) pattern in COVID-19 is ground glass opacities described as bilateral, peripheral, posterior, diffuse, and in lower zone of the lung. Ground glass opacities can evolve in a crazy paving pattern when associated with thickened

interlobular septa and intralobular lines resembling irregularly shaped paving stones.^{9,10}

Computed tomography scan images correlate with lung ultrasound findings characterized by bilateral, patchy distribution of areas with multiple separated or coalescent B-lines separated by 'spared' areas and the presence of sub-pleural and lobar consolidation.¹¹ Additionally, peripheral and pulmonary consolidations are correlated with fibroproliferative diffuse alveolar damage.¹²

Computed tomography angiogram

Several retrospective studies showed an association between COVID-19 pneumonia and higher prevalence segmental and/or sub-segmental pulmonary embolism diagnosed with chest CT angiogram as well as thrombi in the peripheral venous system.^{13–16} Other studies describe the pulmonary thrombosis *in situ* as a complex interplay between endothelial dysfunction, vascular inflammation, platelet activation, and cytokine hyperstimulation related to the infection.¹⁴ This phenomenon, firstly observed by Zapol *et al.* already 50 years ago in ARDS patients,¹⁷ could explain the high prevalence of segmental, sub-segmental, and small vessels thrombosis in the lungs of COVID-19 patients.^{16,18} Thus, CT pulmonary angiogram can be useful to diagnosis and prognosis of pulmonary embolism in patient with COVID-19 pneumonia, however does not explore damages in the microcirculation.¹⁸

Respiratory phenotypes

Respiratory phenotypes of patients with COVID-19-related ARDS may present different features, depending on the stage of the disease. Gattinoni *et al.* hypothesized two clinical presentations: the low (L) type and the high (H) type.^{19,20} The L type is characterized by the absence of subjective distress: low elastance (compliance >50 mL/cmH₂O), low ventilation/perfusion ratio (Va/Q), low lung weight (only ground glass is present on CT scan), and low lung recruitability (non-aerated tissue is rare). Instead, the H type shares the clinical and diagnostic feature of classic ARDS: high elastance (i.e. low compliance), high intra-pulmonary shunt, high lung weight, and potentially, high recruitability. However, the two phenotypes represent different stages of the disease, which may overlap with evolution from L to H type. Recently, Grasselli *et al.* demonstrated that the majority of patients admitted to intensive care unit had lung morphology and respiratory mechanics matching those with 'classical' ARDS according to the Berlin definition.²¹ Additionally, a subgroup (30%) with high mortality was characterized by low static compliance of the respiratory system, higher D-dimer, and increased dead space (DS).²¹ In these patients, there was no relationship between severity of hypoxaemia and static

compliance, confirming the role of DS and of vascular pathology in the reduction of PaO₂/FiO₂. The cause for the increase in DS may be due to the presence of dilated, branching, and/or tortuous vessels in peripheral lung, to perfusion defects due to pulmonary thrombotic angiopathy, or to peripheral embolism.¹⁸ Patients with severe lung parenchymal disease (identified by low compliance) and increased D-dimer have a mortality rate twice than that of patients who have just one of the two.²¹ The reasons for the high prevalence of microangiopathy and peripheral embolism in some, but not in all the patients are unknown.

Laboratory tests

Blood coagulation aspects have received particular attention in most of the studies with the proposition of several markers. Between these, the prognostic role of the increased levels of D-dimer and troponin has immediately emerged.

D-Dimer

The activation of cytokines has also a role in coagulation pathways with the increase of vascular hyperpermeability, capillary damage, and activation of thrombin resulting in micro-thrombosis, CID, and multiple organ failure.²² D-Dimer is an indicator of hypercoagulable state, and an increase of its concentration is one of the most common laboratory findings in COVID-19 patient requiring hospitalization,^{23,24} and it is associated to poor prognosis. Different observations suggest that D-dimer on admission >2.0 µg/mL is a marker of poor prognosis at an early stage.²³ High D-dimer concentration is common in mechanically ventilated patients characterized by low static compliance of the lung and a poor short-term prognosis. The increase of D-dimer in critical COVID-19 patient has multiple explanations: a pro-inflammatory response, endothelial damage, and dysfunction, sepsis-induced hypercoagulability, as well as general condition including age and critically ill conditions.²³ However, despite D-dimer expressing a clear procoagulant state, its increase is highly non-specific and, therefore, cannot discriminate between thrombosis occurring inside or outside the lung.

Troponin

Relationship between acute infection and acute myocardial injury is well known. In a larger single-sample study using cardiac troponin I, Shi *et al.* demonstrated that 19.7% (82/416) of hospitalized COVID-19 patients had cardiac troponin I >99th percentile. This group was characterized by high prevalence of hypertension, coronary heart disease, heart failure, and co-morbidities.²⁴ Furthermore, sepsis has a correlation

with impaired systolic and diastolic function leading to increase high-sensitivity cardiac troponin T (Hs-cTnT) and N-terminal pro-brain natriuretic peptide. Elevated Hs-cTnT and N-terminal pro-brain natriuretic peptide have prognostic value in COVID-19 including a higher risk for death and arrhythmias. The setting of COVID-19 confirms the association between myocardial injury and adverse outcomes, using the Hs-cTnT as a robust, continuous prognostic marker to measure the short-term and long-term cardiovascular risk. Elevated levels of troponin do not discriminate between injuries occurring in the left or in the right side of the heart or both.²⁵ The prognostic role of elevated high-sensitivity troponin was confirmed by Lombardi *et al.* in a multicentric study enrolling 614 patients with laboratory-confirmed severe acute respiratory syndrome coronavirus 2 and high-sensitivity plasma troponin levels (either troponin I or troponin T) measured within 24 h from the time of COVID-19 diagnosis. Elevated troponin levels were found in 45.3% of the patients and were associated with a 71% increase in the risk of in-hospital death and with a more than two-fold increase in major complications, including sepsis, acute kidney failure, multiple organ failure, pulmonary embolism, and major bleeding. The group with the presence of both elevated troponin levels and cardiac co-morbidity was associated with the highest mortality rate in comparison with the group with low troponin levels and the group with high troponin levels or the presence of cardiac co-morbidity.²⁶

Inflammatory markers

Immune dysregulation plays an emerging role in the analysis of myocardial injury defined as troponin elevation. Li *et al.* showed that in 317 patients with COVID-19, 39 (21.4%) patients experienced myocardial injury, 144 (79.1%) patients were diagnosed with immune dysregulation, of which 139 (76.4%) presented with cellular immune dysregulation, and 48 (26.4%) had humoral immunity dysregulation. The multivariate logistic regression analysis showed that white blood cells count, high-sensitivity C-reactive protein, and procalcitonin were independently associated with myocardial injury in patients with COVID-19.²⁷ In support of these data, also Barman *et al.* report how the blood levels of white blood cell, C-reactive protein, procalcitonin, and ferritin were significantly higher in the myocardial injury group.²⁸

Cardiac involvement

Echocardiogram

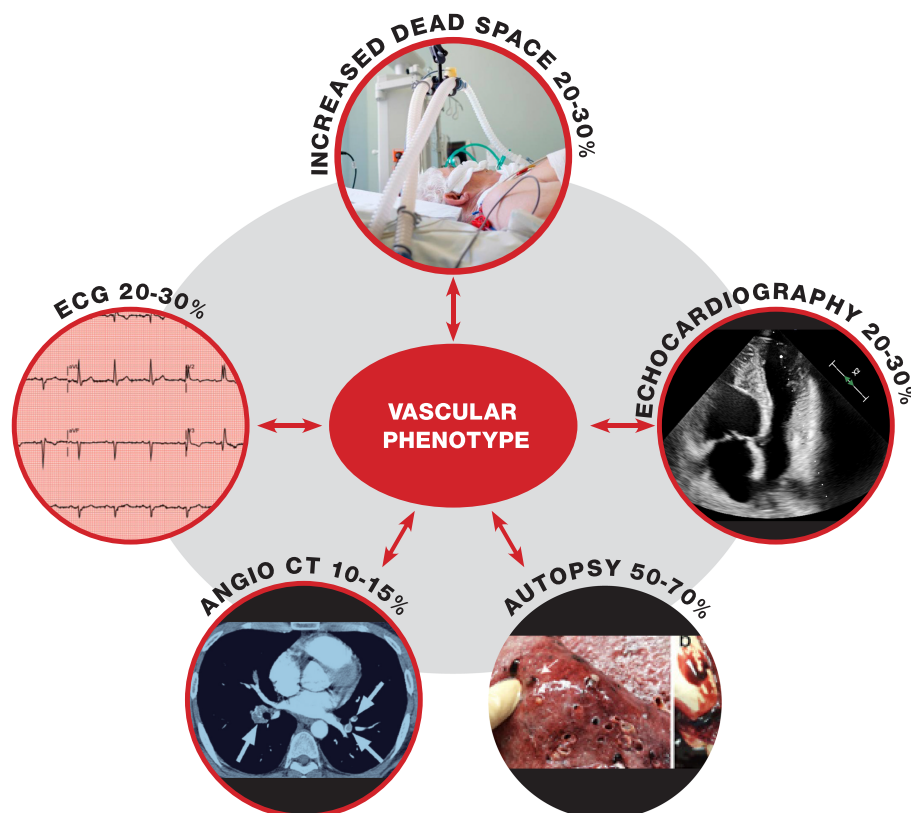
A myocardial injury can present with various clinical manifestations, up to heart failure and cardiogenic shock. Today, echocardiography is the first line for the assessment of

ventricular function, and it has a role for identification of ventricular dysfunction in COVID-19 patients. Deng *et al.*²⁹ report that 112 hospitalized COVID-19 patients had a mean left ventricular (LV) ejection fraction (EF) of $60 \pm 5.6\%$, and only 5.4% of patients had an EF $< 50\%$ with no patients with EF $< 40\%$. The Seattle-based American group founded, in the acute phase of COVID-19, LV dysfunction in a higher percentage (33%) of cases admitted to intensive care unit.³⁰ There are different scenarios of non-ischaemic LV dysfunction in COVID-19 patients: ventricular stress dysfunction, myocarditis, and cytokine-induced dysfunction.³¹ Ventricular stress-induced dysfunction, known as takotsubo syndrome, has been observed in a few cases.^{32,33} The diagnosis was suspected at echocardiography in view of the typical contraction of the LV with systolic apical ballooning and confirmed on coronary angiography with the absence of significant coronary lesions. Clinical cases of suspected myocarditis are also few,^{34–39} including one proven by biopsy,³⁶ six by severe LV systolic dysfunction and marked reduction in EF, and two by biventricular dysfunction.

Besides the evaluation of LV, echocardiogram studies highlighted the relatively frequent RV enlargement suggesting RV pressure overload.^{40–43} The role of increased RV afterload during ARDS, in terms of acute cor pulmonale,

has already widely described.⁴⁴ Argulian *et al.* reviewed the echocardiographs of 105 hospitalized COVID-19 patients, 30% of whom were critically ill at the time of the echocardiographic examination. Right ventricular dilation was observed in 31% of them. Patients with RV dilation often had ventricular hypokinesia and moderate to severe tricuspid insufficiency. In the multivariate analysis, RV dilation was the only variable associated with mortality.⁴⁰ These data show that RV dilation is prevalent in COVID-19 patients. An analysis of echocardiographic parameters in over 400 COVID-19 patients with matched controls assessed the prognostic value of LV and RV function.⁴¹ The systolic function of both ventricles was reduced in patients with COVID-19 and associated with an increased risk of mortality. These observations have been confirmed by Li *et al.*⁴⁵ in 120 consecutive patients with COVID-19: RV strain impairment was associated with increased incidence of acute myocardial injury, ARDS, and deep vein thrombosis. Thus, echocardiography, despite all the technical, logistical, and safety limitations in its execution especially in intubated patients, appears to be of importance to identify the dysfunction of both ventricles, left and right, thus contributing to the identification of the 'vascular' phenotype in case of prevalence of RV pressure overload.

Figure 1 Summary of test and imaging tools that can unmask 'vascular' phenotype. CT, computed tomography; ECG, electrocardiogram.



Standard electrocardiogram

Standard electrocardiogram (ECG) as a screening tool for cardiovascular complications was almost neglected in the initial phase of COVID-19. Thus far, few studies have been published, which indicate that signs of RV pressure overload are present in critically ill COVID-19 patients.^{46–50} This has shifted the initial attention from the LV to the RV, and it is useful to timely suspect injuries in pulmonary macrocirculation or microcirculation typical of the ‘vascular’ phenotype. The ECG offers several advantages compared with other tools: it can be obtained easily, rapidly, and safely, and it is useful to show acute or chronic cardiac diseases, which, in turn, are linked to negative outcome in these patients. Lanza *et al.* analysed 324 ECGs of COVID-19 patients admitted to emergency room.⁴⁶ They found that the 37% of these ECGs had some major abnormalities, confirming previously reported data.^{47–49} We analysed 431 ECGs of critically ill COVID-19 patients admitted to emergency rooms: 93% of these patients had an abnormal ECG, and more specifically, 30% had signs of RV pressure overload unrelated to differences in values of positive end expiratory pressure.⁴⁹

Paradigm shifts in COVID-19 pneumonia: clinical and pathophysiological relevance of the vascular phenotype

Despite diagnosis of the ‘vascular’ phenotype of COVID-19 pneumonia may be subtle, the evidence indicates a reasonable possibility of identifying it already in the initial stage of the infection. This is clinically relevant as the vascular component is the result of thrombosis of the lung and may benefit of immediate therapeutic action. (see supplemental Table S1).

Figure 1 summarizes the diagnostic value of each tool. Chest CT scan and chest CT angiogram may quantify both parenchyma and vascular damage. However, chest CT angiogram may be normal even in the presence of thrombosis of pulmonary microcirculation. Increased D-dimer concentration is of additional value to confirm a thrombotic state, but it is non-specific and cannot localize the thrombus. An elevation of troponin concentration may reflect cardiac injury but cannot distinguish whether the injury is on the left or in the right site of the heart; only the last condition reflects an obstruction of the lung circulation. Standard ECG provides specific signs of RV pressure overload already in the early state, at low cost, and without risk for patients and healthcare workers. The ECG may and should be complemented by echocardiography, although in SARS-CoV-

2 patients, echocardiography is often of poor quality and technically difficult because of the obliged decubitus and mechanical ventilation.

This is particularly relevant for the ‘vascular’ phenotype, which does not necessarily represent the result of thrombo-embolic venous complications, but more frequently, it is the result of pulmonary microcirculation thrombosis *in situ* and needs immediate therapeutic action to improve prognosis of the patients.⁵¹

Conclusions

COVID-19 pneumonia is not all the same. There is the need to timely identify in a simple manner the specific phenotype of each patient to start a proper treatment and evaluate the prognosis. In the hospital, already at the admission, it is possible to reach a ‘phenotypic’ diagnosis mixing the various instrumental tests. We need to realize that COVID-19 pneumonia is dynamic: the ‘parenchyma’ phenotype may evolve in the ‘vascular’ one. The daily, ECG-based, reconsideration of patient phenotype may be useful to guide the right treatment.

Conflict of interest

None declared.

Funding

None.

Endnote

^aTake home message

- Diagnosis of the ‘vascular’ phenotype (involvement of both pulmonary parenchyma and its circulation) of COVID-19 pneumonia may be subtle.
- Chest computed tomography scan and angiogram may be not sufficient to identify ‘vascular’ phenotype.
- Increased D-dimer concentration and elevation of troponin levels are non-specific.
- Echocardiogram and electrocardiogram provide specific signs of right ventricular pressure overload unmasking ‘vascular’ phenotype.
- The electrocardiogram should be complemented by echocardiography, although in SARS-CoV-2, patients’ echocardiography is often of poor quality and technically difficult.

References

1. Coronavirus disease 2019 (COVID-19)—history and exam. *BMJ*. 2020. Accessed: 21 August 2020. <https://bestpractice.bmj.com/topics/engb/3000168/history-exam>
2. Iba T, Warkentin TE, Thachil J, Levi M, Levy JH. Proposal of the definition for COVID-19-associated coagulopathy. *J Clin Med* 2021; **10**: 191.
3. Ackermann M, Verleden SE, Kuehnel M, Haverich A, Welte T, Laenger F, Vanstapel A, Werlein C, Stark H, Tzankov A, Li WW, Li VW, Mentzer S, Jonigk D. Pulmonary vascular endothelialitis, thrombosis, and angiogenesis in Covid-19. *N Engl J Med* 2020; **383**: 120–128. <https://doi.org/10.1056/NEJMoa2015432>
4. Wichmann D, Sperhake JP, Lütgehetmann M, Steurer S, Edler C, Heinemann A, Heinrich F, Mushumba H, Knipf I, Schröder AS, Burdelski C, de Heer G, Nierhaus A, Frings D, Pfefferle S, Becker H, Brederke-Wiedling H, de Weerth A, Paschen HR, Sheikhzadeh-Eggers S, Stang A, Schmiedel S, Bokemeyer C, Addo MM, Aepfelbacher M, Püschel K, Kluge S. Autopsy findings and venous thromboembolism in patients with COVID-19: a prospective cohort study. *Ann Intern Med* 2020; **173**: 268–277.
5. Magro C, Mulvey JJ, Berlin D, Nuovo G, Salvatore S, Harp J, Baxter-Stoltzfus A, Laurence J. Complement associated microvascular injury and thrombosis in the pathogenesis of severe COVID-19 infection: a report of five cases. *Transl Res* 2020; **220**: 1–13.
6. Becker RC. COVID-19 update: Covid-19-associated coagulopathy. *J Thromb Thrombolysis* 2020; **50**: 54–67.
7. Basso C, Leone O, Rizzo S, de Gaspari M, van der Wal AC, Aubry MC, Bois MC, Lin PT, Maleszewski JJ, Stone JR. Pathological features of COVID-19-associated myocardial injury: a multicentre cardiovascular pathology study. *Eur Heart J* 2020; **41**: 3827–3835.
8. Bussani R, Schneider E, Zentilin L, Collesi C, Ali H, Braga L, Volpe MC, Colliva A, Zanonati F, Berlot G, Silvestri F, Zaccagna S, Giacca M. Persistence of viral RNA, pneumocyte syncytia and thrombosis are hallmarks of advanced COVID-19 pathology. *EBioMedicine* 2020; **61**: 103104.
9. Simpson S, Kay FU, Abbara S, Bhalla S, Chung JH, Chung M, Henry TS, Kanne JP, Kligerman S, Ko JP, Litt H. Radiological Society of North America expert consensus statement on reporting chest CT findings related to COVID-19. Endorsed by the Society of Thoracic Radiology, the American College of Radiology, and RSNA—secondary publication. *J Thorac Imaging* 2020; **35**: 219–227.
10. Vetrugno L, Baciarello M, Bignami E, Bonetti A, Saturno F, Orso D, Girometti R, Cereser L, Bove T. The “pandemic” increase in lung ultrasound use in response to Covid-19: can we complement computed tomography findings? A narrative review. *Ultrasound J* 2020; **12**: 39.
11. Volpicelli G, Lamorte A, Villén T. What’s new in lung ultrasound during the COVID-19 pandemic. *Intensive Care Med* 2020; **46**: 1445–1448.
12. de Almeida Monteiro RA, Duarte-Neto AN, Ferraz da Silva LF, de Oliveira EP, do Nascimento ECT, Mauad T, Saldiva PHDN, Dolhnikoff M. Ultrasound assessment of pulmonary fibroproliferative changes in severe COVID-19: a quantitative correlation study with histopathological findings. *Intensive Care Med* 2021; **47**: 199–207.
13. Tang N, Li D, Wang X, Sun Z. Abnormal coagulation parameters are associated with poor prognosis in patients with novel coronavirus pneumonia. *J Thromb Haemost* 2020; **18**: 844–847.
14. Ooi MWX, Rajai A, Patel R, Gerova N, Godhangaonkar V, Liang SY. Pulmonary thromboembolic disease in COVID-19 patients on CT pulmonary angiography—prevalence, pattern of disease and relationship to D-dimer. *Eur J Radiol* 2020; **132**: 109336.
15. Grillet F, Behr J, Calame P, Aubry S, Delabrousse E. Acute pulmonary embolism associated with COVID-19 pneumonia detected with pulmonary CT angiography. *Radiology* 2020; **296**: E186–E188.
16. Léonard-Lorant I, Delabranche X, Séverac F, Helms J, Pauzet C, Collange O, Schneider F, Labani A, Bilbault P, Molière S, Leyendecker P, Roy C, Ohana M. Acute pulmonary embolism in patients with COVID-19 at CT angiography and relationship to D-dimer levels. *Radiology* 2020; **296**: E189–E191.
17. Zapol WM, Snider MT. Pulmonary hypertension in severe acute respiratory failure. *N Engl J Med* 1977; **296**: 476–480.
18. Patel BV, Arachchilage DJ, Ridge CA, Bianchi P, Doyle JF, Garfield B, Ledot S, Morgan C, Passariello M, Price S, Singh S, Thakuria L, Trenfield S, Trimlett R, Weaver C, Wort SJ, Xu T, Padley SPG, Devaraj A, Desai SR. Pulmonary angiopathy in severe COVID-19: physiologic, imaging, and hematologic observations. *Am J Respir Crit Care Med* 2020; **202**: 690–699.
19. Gattinoni L, Chiumello D, Caironi P, Busana M, Romitti F, Brazzi L, Camporota L. COVID-19 pneumonia: different respiratory treatments for different phenotypes? *Intensive Care Med* 2020; **46**: 1099–1102.
20. Gattinoni L, Chiumello D, Rossi S. COVID-19 pneumonia: ARDS or not? *Crit Care* 2020; **24**: 154.
21. Grasselli G, Tonetti T, Protti A, Langer T, Girardis M, Bellani G, Laffey J, Carrafiello G, Carsana L, Rizzuto C, Zanella A, Scaravilli V, Pizzilli G, Grieco DL, di Meglio L, de Pascale G, Lanza E, Monteduro F, Zompatori M, Filippini C, Locatelli F, Cecconi M, Fumagalli R, Nava S, Vincent JL, Antonelli M, Slutsky AS, Pesenti A, Ranieri VM, Lissoni A, Rossi N, Guzzardella A, Valsecchi C, Madotto F, Bevilacqua F, di Laudo M, Querci L, Seccafico C. Pathophysiology of COVID-19-associated acute respiratory distress syndrome: a multicentre prospective observational study. *Lancet Respir Med* 2020; **8**: 1201–1208.
22. Jose RJ, Manuel A. COVID-19 cytokine storm: the interplay between inflammation and coagulation. *Lancet Respir Med* 2020; **8**: e46–e47.
23. Zhang L, Yan X, Fan Q, Liu H, Liu X, Liu Z, Zhang Z. D-dimer levels on admission to predict in-hospital mortality in patients with Covid-19. *J Thromb Haemost* 2020; **18**: 1324–1329.
24. Shi S, Qin M, Shen B, Cai Y, Liu T, Yang F, Gong W, Liu X, Liang J, Zhao Q, Huang H, Yang B, Huang C. Association of cardiac injury with mortality in hospitalized patients with COVID-19 in Wuhan, China. *JAMA Cardiol* 2020; **5**: 802–810.
25. Sandoval Y, Januzzi JL Jr, Jaffe AS. Cardiac troponin for assessment of myocardial injury in COVID-19: JACC review topic of the week. *J Am Coll Cardiol* 2020; **76**: 1244–1258.
26. Lombardi CM, Carubelli V, Iorio A, Inciardi RM, Bellasi A, Canale C, Camporotondo R, Catagnano F, Dalla Vecchia LA, Giovinazzo S, Maccagni G. Association of troponin levels with mortality in Italian patients hospitalized with coronavirus disease 2019: results of a multicenter study. *JAMA Cardiol* 2020; **5**: 1274–1280.
27. Li D, Chen Y, Jia Y, Tong L, Tong J, Wang W, Liu Y, Wan Z, Cao Y, Zeng R. SARS-CoV-2-induced immune dysregulation and myocardial injury risk in China: insights from the ERS-COVID-19 study. *Circ Res* 2020; **127**: 397–399.
28. Barman HA, Atici A, Sahin I, Alici G, Tekin EA, Baycan ÖF, Öztürk F, Oflar E, Tugrul S, baran Yavuz M, Celik FB. Prognostic significance of cardiac injury in COVID-19 patients with and without coronary artery disease. *Coron Artery Dis* 2020; **30**.
29. Deng Q, Hu B, Zhang Y, Wang H, Zhou X, Hu W, Cheng Y, Yan J, Ping H, Zhou Q. Suspected myocardial injury in patients with COVID-19: evidence from front-line clinical observation in Wuhan, China. *Int J Cardiol* 2020; **311**: 116–121.
30. Arentz M, Yim E, Klaff L, Lokhandwala S, Riedo FX, Chong M, Lee M. Characteristics and outcomes of 21 critically ill patients with COVID-19 in Washington State. *JAMA* 2020; **323**: 1612–1614.

31. Hendren NS, Drazner MH, Bozkurt B, Cooper LT Jr. Description and proposed management of the acute COVID-19 cardiovascular syndrome. *Circulation* 2020; **141**: 1903–1914.
32. Meyer P, Degrauwe S, Van Delden C, Ghadri JR, Templin C. Typical takotsubo syndrome triggered by SARS-CoV-2 infection. *Eur Heart J* 2020; **41**: 1860.
33. Moderato L, Monello A, Lazzeroni D, Binno S, Giacalone R, Ferraro S, Piepoli MF, Villani GQ. Sindrome Takotsubo in corso di polmonite da SARS-CoV-2: una possibile complicanza cardiovascolare [Takotsubo syndrome during SARS-CoV-2 pneumonia: a possible cardiovascular complication]. *G Ital Cardiol (Rome)* 2020; **21**: 417–420.
34. Hu H, Ma F, Wei X, Fang Y. Coronavirus fulminant myocarditis saved with glucocorticoid and human immunoglobulin. *Eur Heart J* 2020; **42**: ehaa190.
35. Zeng JH, Liu YX, Yuan J, Wang FX, Wu WB, Li JX, Wang LF, Gao H, Wang Y, Dong CF, Li YJ, Xie XJ, Feng C, Liu L. First case of COVID-19 complicated with fulminant myocarditis: a case report and insights. *Infection* 2020; **48**: 773–777.
36. Inciardi RM, Lupi L, Zaccone G, Italia L, Raffo M, Tomasoni D, Cani DS, Cerini M, Farina D, Gavazzi E, Maroldi R, Adamo M, Ammirati E, Sinagra G, Lombardi CM, Metra M. Cardiac involvement in a patient with coronavirus disease 2019 (COVID-19). *JAMA Cardiol* 2020; **5**: 819–824.
37. Sala S, Peretto G, Gramegna M, Palmisano A, Villatore A, Vignale D, de Cobelli F, Tresoldi M, Cappelletti AM, Basso C, Godino C, Esposito A. Acute myocarditis presenting as a reverse Tako-Tsubo syndrome in a patient with SARS-CoV-2 respiratory infection. *Eur Heart J* 2020; **41**: 1861–1862.
38. Kim IC, Kim JY, Kim HA, Han S. COVID-19-related myocarditis in a 21-year-old female patient. *Eur Heart J* 2020; **41**: 1859.
39. Fried JA, Ramasubbu K, Bhatt R, Topkara VK, Clerkin KJ, Horn E, Rabbani LR, Brodie D, Jain SS, Kirtane AJ, Masoumi A, Takeda K, Kumaraiah D, Burkhoff D, Leon M, Schwartz A, Uriel N, Sayer G. The variety of cardiovascular presentations of COVID-19. *Circulation* 2020; **141**: 1930–1936.
40. Argulian E, Sud K, Vogel B, Bohra C, Garg VP, Talebi S, Lerakis S, Narula J. Right ventricular dilation in hospitalized patients with COVID-19 infection. *JACC Cardiovasc Imaging* 2020; **13**: 2459–2461.
41. Lassen MCH, Skaarup KG, Lind JN, Alhakak AS, Sengeløv M, Nielsen AB, Espersen C, Ravnkilde K, Hauser R, Schöps LB, Holt E, Johansen ND, Modin D, Djernæs K, Graff C, Bundgaard H, Hassager C, Jabbari R, Carlsen J, Lebech AM, Kirk O, Bodtger U, Lindholm MG, Joseph G, Wiese L, Schiødt FV, Kristiansen OP, Walsted ES, Nielsen OW, Madsen BL, Tønder N, Benfield T, Jeschke KN, Ulrik CS, Knop FK, Lamberts M, Sivapalan P, Gislason G, Marott JL, Møgelvang R, Jensen G, Schnohr P, Sjøgaard P, Solomon SD, Iversen K, Jensen JUS, Schou M, Biering-Sørensen T. Echocardiographic abnormalities and predictors of mortality in hospitalized COVID-19 patients: the ECHOVID-19 study. *ESC Heart Fail* 2020; **7**: 4189–4197.
42. Schott JP, Mertens AN, Bloomingdale R, O'Connell TF, Gallagher MJ, Dixon S, Abbas AE. Transthoracic echocardiographic findings in patients admitted with SARS-CoV-2 infection. *Echocardiography* 2020; **37**: 1551–1556.
43. Mahmoud-Elsayed HM, Moody WE, Bradlow WM, Khan-Kheil AM, Senior J, Hudsmith LE, Steeds RP. Echocardiographic findings in patients with COVID-19 pneumonia. *Can J Cardiol* 2020; **36**: 1203–1207.
44. Repessé X, Charron C, Vieillard-Baron A. Acute cor pulmonale in ARDS: rationale for protecting the right ventricle. *Chest* 2015; **147**: 259–265.
45. Li Y, Li H, Zhu S, Xie Y, Wang B, He L, Zhang D, Zhang Y, Yuan H, Wu C, Sun W, Zhang Y, Li M, Cui L, Cai Y, Wang J, Yang Y, Lv Q, Zhang L, Xie M. Prognostic value of right ventricular longitudinal strain in patients with COVID-19. *JACC Cardiovasc Imaging* 2020; **13**: 2287–2299.
46. Lanza GA, De Vita A, Ravenna SE, D'Aiello A, Covino M, Franceschi F, Crea F. Electrocardiographic findings at presentation and clinical outcome in patients with SARS-CoV-2 infection. *Europace* 2020; **23**: euaa245.
47. Elias P, Poterucha TJ, Jain SS, Sayer G, Raikhelkar J, Fried J, Clerkin K, Griffin J, DeFilippis EM, Gupta A, Lawlor M, Madhavan M, Rosenblum H, Roth ZB, Natarajan K, Hripcsak G, Perotte A, Wan EY, Saluja A, Dizon J, Ehlert F, Morrow JP, Yarmohammadi H, Kumaraiah D, Redfors B, Gavin N, Kirtane A, Rabbani L, Burkhoff D, Moses J, Schwartz A, Leon M, Uriel N. The prognostic value of electrocardiogram at presentation to emergency department in patients with COVID-19. *Mayo Clin Proc* 2020; **95**: 2099–2109.
48. McCullough SA, Goyal P, Krishnan U, Choi JJ, Safford MM, Okin PM. Electrocardiographic findings in coronavirus disease-19: insights on mortality and underlying myocardial processes. *J Card Fail* 2020; **26**: 626–632.
49. Bertini M, Ferrari R, Guardigli G, Malagù M, Vitali F, Zucchetti O, D'Aniello E, Volta CA, Cimaglia P, Piovaccari G, Corzani A, Galvani M, Ortolani P, Rubboli A, Tortorici G, Casella G, Sassone B, Navazio A, Rossi L, Aschieri D, Rapezzi C. Electrocardiographic features of 431 consecutive, critically ill COVID-19 patients: an insight into the mechanisms of cardiac involvement. *Europace* 2020; **22**: 1848–1854.
50. Pavri BB, Kloo J, Farzad D, Riley JM. Behavior of the PR interval with increasing heart rate in patients with COVID-19. *Heart Rhythm* 2020; **17**: 1434–1438.
51. Rey JR, Caro-Codón J, Rosillo SO, Iniesta ÁM, Castrejón-Castrejón S, Marco-Clement I, Martín-Polo L, Merino-Argos C, Rodríguez-Sotelo L, García-Veas JM, Martínez-Marín LA, Martínez-Cossiani M, Buño A, Gonzalez-Valle L, Herrero A, López-Sendón JL, Merino JL. CARD-COVID Investigators. Heart failure in COVID-19 patients: prevalence, incidence and prognostic implications. *Eur J Heart Fail* 2020; **22**: 2205–2215.