

VISCERAL PERCEPTION

A role for inflammation in irritable bowel syndrome?

G Barbara, R De Giorgio, V Stanghellini, C Cremon, R Corinaldesi

Gut 2002;51(Suppl 1):i41-i44

Attention has been directed to the putative role of low grade mucosal inflammation in irritable bowel syndrome (IBS) on the basis of evidence showing that some patients with IBS have an increased number of inflammatory cells in the colonic and ileal mucosa. Previous episodes of infectious enteritis, genetic factors, undiagnosed food allergies, and changes in bacterial microflora may all play a role in promoting and perpetuating this low grade inflammatory process. Human and animal studies support the concept that inflammation may perturb gastrointestinal reflexes and activate the visceral sensory system even when the inflammatory response is minimal and confined to the mucosa. Thus abnormal neuroimmune interactions may contribute to the altered gastrointestinal physiology and hypersensitivity that underlies IBS. A brief review of the human and animal studies that have focused on the putative role of intestinal inflammation and infections in the pathogenesis of IBS is given.

SUMMARY

Irritable bowel syndrome (IBS) is one of the most common disorders encountered in clinical practice. Accepted mechanisms involve psychosocial factors, abnormal gastrointestinal motility, and disturbed visceral sensory perception, but the underlying cause of the pathophysiological changes remains unclear. In recent years, attention has been directed to the putative role of low grade mucosal inflammation, on the basis of evidence showing that some patients with IBS have an increased number of inflammatory cells in the colonic and ileal mucosa. Previous episodes of infectious enteritis, genetic factors, undiagnosed food allergies, and changes in bacterial microflora may all play a role in promoting and perpetuating this low grade inflammatory process. Both human and animal studies support the concept that inflammation may perturb gastrointestinal reflexes and activate the visceral sensory system even when the inflammatory response is minimal and confined to the mucosa. Thus abnormal neuroimmune interactions may contribute to the altered gastrointestinal physiology and the hypersensitivity that underlies IBS. Animal models have been developed to help explore these paradigms. More research is required to identify which subsets of patients with IBS bear low grade inflammatory changes, and to define the role of inflammation in sensorimotor dysfunction and symptom generation.

INTRODUCTION

IBS is the most common disorder encountered by gastroenterologists, and is responsible for reduced quality of life and considerable economic burden on society.¹ Over the years, several theories have been proposed to explain the pathophysiology of IBS, including psychosocial factors and abnormalities in gastrointestinal motility.¹ It is now clear that these mechanisms, whether considered alone or in combination, are insufficient to explain symptom generation. Attention has recently been focused on increased perception of visceral stimuli arising from the gastrointestinal tract wall, a phenomenon referred to as visceral hypersensitivity.²⁻⁴ Visceral hypersensitivity is thought to play a pivotal role in the intestinal motor abnormalities and abdominal pain or discomfort described by a large proportion of patients with IBS.^{5,6} It is possible that altered visceral perception arises from hyperexcitability of dorsal horn neurones in the central limb of the visceral afferent system.⁷ Peripheral sensitisation of mucosal afferents and recruitment of "silent" nociceptors may also be key factors in visceral hyperalgesia.⁸ Central mechanisms are also involved.

Among the sensitising factors acting on nerve terminals at the peripheral level, altered interaction between the mucosal immune system and the afferent nerve terminals which project to the intestine is now receiving increasing attention. Low grade inflammation in the intestinal mucosa has been found in subgroups of patients and may be involved in the pathophysiology of visceral hypersensitivity, in at least some cases of IBS.⁹ Recent research indicates that patients who develop persistent symptoms following resolution of an enteric gastrointestinal infection (a condition referred to as post-infectious IBS) are likely candidates for this form of low grade inflammation.¹⁰

This paper provides a brief review of the human and animal studies that have focused on the putative role of intestinal inflammation and infections in the pathogenesis of IBS.

EVIDENCE OF INFLAMMATION IN IBS

Table 1 provides a list of the published studies investigating the presence of intestinal inflammation in IBS. The first evidence of possible involvement of an inflammatory component in the intestinal wall of patients with IBS was reported in the early 1960s by Hiatt and Katz who detected an increased number of mast cells in the *muscularis externa* of surgical colonic specimens.¹¹ However, only a few cases were studied and, unfortunately, this line of research was not taken up by other investigators. As full thickness specimens

See end of article for authors' affiliations

Correspondence to:
Dr G Barbara, Department
of Internal Medicine and
Gastroenterology, St
Orsola Hospital, Via
Massarenti 9, I-40138
Bologna, Italy;
gbarbara@med.unibo.it

Abbreviations: IBS, irritable bowel syndrome.

Table 1 Studies describing low grade inflammation in irritable bowel syndrome (IBS)

Clinical setting	Ref	n	Diagnostic criteria	Type of inflammatory cell	Intestinal tract involved	Intestinal layer involved
Irritable colon	11	4	—	Mast cells	Colon	Muscularis propria
IBS	13	51	—	Unspecified	Right colon	Lamina propria
Diarrhoea predominant IBS	23	20	Manning	Mast cells	Ileum	Lamina propria
	14	14	Rome I	Mast cells	Right colon	Lamina propria
Post-infective IBS	34	10	Rome I	Chronic inflammatory infiltrate	Left colon	Lamina propria
	10	10	Rome I	T lymphocytes	Rectum	Lamina propria

from IBS patients are no longer available, more recent studies have focused on the mucosa.

The intestinal mucosa contains a florid immune system which can be regarded as “physiologically inflamed”. Thus low grade inflammation can only be evaluated using quantitative assessments.¹² Using this approach, it has been shown that patients with IBS have a measurable significant increase in lamina propria immune cells in the colonic mucosa compared with healthy subjects.¹³ This low grade inflammation appears to be more predominant in the right than in the left colon.^{13, 14} If low grade inflammation plays a role in sensorimotor dysfunction in IBS, the uneven distribution of increased inflammatory cells may help explain the regional differences in colonic motor dysfunction^{15, 16} or visceral hyper-sensitivity^{17, 18} that have been observed in some studies.

Mucosal mast cells in healthy subjects lie in close proximity to enteric nerves^{19, 20} and release a wide array of inflammatory mediators that are capable of affecting enteric nerve function²¹ and muscle contractility.²² These findings have prompted the initiation of studies to evaluate mast cell density in the mucosa of IBS patients. Quantitative assessments have identified increased numbers of mast cells in the ileum²³ and colon¹⁴ of these patients. It has also been shown that IBS patients have increased numbers of T cells in the colonic mucosa and that these immunocytes lie in close anatomical association with axonal fibres of the enteric nervous system.²⁴ This is of particular interest in the light of studies demonstrating that T cell activation evokes changes in neuromuscular function in the intestinal tract.²⁵

PUTATIVE CAUSES OF LOW GRADE INTESTINAL INFLAMMATION

A variety of mechanisms may contribute to the low grade mucosal inflammation found in IBS patients. Previous episodes of infectious enteritis,¹⁰ genetic factors,²⁶ undiagnosed food allergies,²⁷ and changes in intestinal microflora²⁸ may all play a role, either individually or in combination.

Attention has increasingly been focused on the role of previous acute gastroenteritis as the precipitating cause of inflammation. Patients with IBS frequently refer to the fact that their symptoms developed abruptly following an episode of dysentery, an association which was first recognised some 40 years ago by Chaudary and Truelove.²⁹ Retrospective analysis of 130 patients with IBS showed that in approximately 25% of cases the symptoms had initially appeared in the wake of an enteric infection.²⁹ These findings have been confirmed by recent prospective studies showing that persistent IBS symptoms develop in between 7% and 32% of subjects after enteritis caused by *Salmonella*, *Shigella*, or *Campylobacter*.^{10, 30-35} This association is now referred to as post-infective IBS. The risk factors associated with post-infective IBS include prolonged duration of initial illness, female sex,³³ and psychological disturbance before the illness.³⁴ The use of antibiotics during acute bacterial gastroenteritis is also thought to increase the risk of the development of long term symptoms.³⁶

Altered gastrointestinal transit times,³⁴ visceral hypersensitivity,³⁰ and psychosocial factors³² have all been

implicated in the pathophysiology of post-infectious IBS. Recent studies have demonstrated that the persistence of symptoms after a bout of infection was associated with on-going low grade intestinal inflammation in the colonic mucosa.^{10, 34} These findings suggest such patients are unable to downregulate intestinal inflammation after eviction of the infectious agent. Although knowledge is currently lacking as to how mucosal inflammation persists in patients with IBS, a recent study prompts the speculation that genetic factors may play a role.²⁶ Anti-inflammatory cytokines (that is, interleukin 10 and transforming growth factor β_1), high producer allele, and genotype frequencies have been shown to be significantly reduced in patients with IBS compared with healthy controls.²⁶ This observation suggests that there may be a genetic predisposition in some patients towards an abnormal pattern of proinflammatory and anti-inflammatory cytokine synthesis. This hypothesis is in keeping with data from Morris-Yates and colleagues³⁷ who showed that a significant proportion of functional bowel disorders are likely to be under genetic control as monozygotic, and to a lesser extent dizygotic, twins have a particularly high prevalence of IBS.

Allergic reactions are known to evoke inflammatory cell infiltration and activation at various mucosal sites, including the gastrointestinal tract.^{38, 39} However, the prevalence of food allergies in IBS is poorly defined, probably because of intrinsic difficulties in their identification.⁴⁰ The contribution of food allergies to low grade inflammation in IBS is a topic of great interest for which further studies are needed.

Another putative mechanism which may be responsible for low grade inflammation in IBS involves changes in intestinal microflora. Indirect evidence indicates that bacterial fermentation of foods is increased in patients with IBS,⁴¹ a significant proportion of whom have intestinal bacterial overgrowth,⁴² but few studies have directly assessed the status of the gut microflora in IBS. One study showed that coliforms, lactobacilli, and bifidobacteria were decreased in the faeces of patients with IBS⁴³ while another preliminary study suggests a significant increase in colonic anaerobes, *Escherichia coli*, and bacteroides.⁴⁴ Further studies are therefore needed to elucidate the role of intestinal microflora in triggering minimal mucosal inflammation in IBS.

CONSEQUENCES OF INTESTINAL INFLAMMATION ON SYMPTOM GENERATION

Inflammatory conditions affecting the gastrointestinal tract, including inflammatory bowel disease, coeliac disease, and acute gastrointestinal infections are associated with disturbed intestinal motor function and increased sensory perception.²⁵ Basic studies have demonstrated a cause-effect relationship between mucosal inflammation, altered gastrointestinal motor function, and visceral hyperalgesia.²⁵ These sensorimotor abnormalities are not necessarily related to an overt inflammatory reaction as they can occur even when inflammation is minimal and restricted to the mucosa.²⁵ For example, altered sensory and motor function accompanied by the development of IBS-like symptoms has been observed in patients with quiescent ulcerative colitis.⁴⁵⁻⁴⁷ This supports the

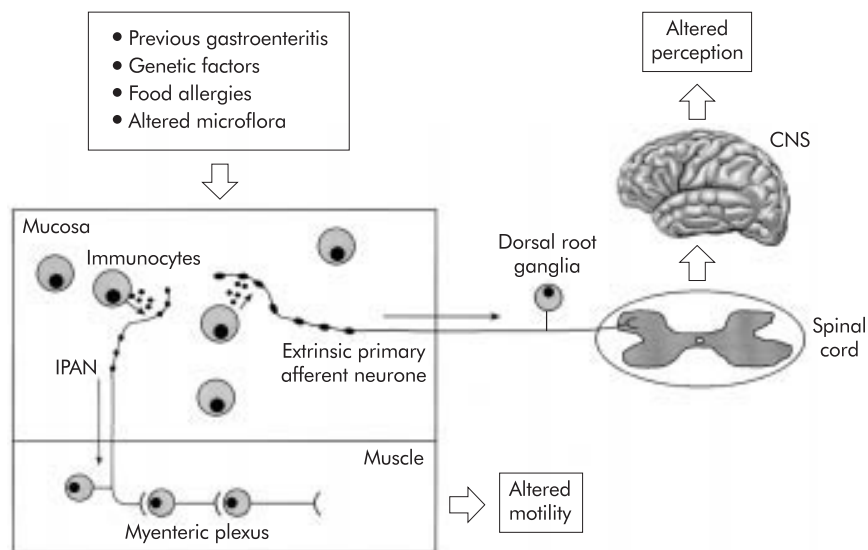


Figure 1 Working hypothesis on the role of low grade inflammation in the pathogenesis of irritable bowel syndrome. A wide array of factors (for example, previous episodes of infective gastroenteritis, genetic factors, food allergies, and altered intestinal microflora) evoke mucosal low grade inflammation which is capable of sensitising both intrinsic primary afferent neurones (IPANs) and extrinsic primary afferent neurones. Abnormal stimulation of IPANs leads to altered intestinal motor function while sensitisation of extrinsic primary afferent neurones evokes visceral hypersensitivity and symptom generation. CNS, central nervous system.

concept that even minimal inflammation can induce visceral hypersensitivity and symptoms.

The involvement of low grade inflammation in altered neuromotor function in IBS is also supported by the observation that in normal and inflamed intestinal mucosa immunocytes lie in close proximity to nerve fibres of the enteric nervous system.¹⁹ As this close anatomical relationship does not occur by chance, the existence of a functional interplay between neural and immune elements in the intestinal mucosa seems likely.¹⁹ As mentioned previously, preliminary data indicate that inflammatory cells are more strictly related to neurones supplying the bowel mucosa in IBS patients than in healthy subjects.²⁴ These findings indicate that altered neuroimmune interactions may play a role in sensorimotor dysfunction in IBS.

LESSONS FROM ANIMAL MODELS

Although animal models do not reliably reflect the pathogenetic complexity of IBS, they are none the less instrumental for our understanding of intestinal physiology and pathophysiology as well as for testing potentially useful therapies for human diseases. Research in animal models of intestinal inflammation has shown that inflammatory cells and their biological products can evoke visceral hyperalgesia by sensitising mucosal afferent nerve endings.⁸ We have recently demonstrated a significant increase in the sensory neuropeptide substance P in the dorsal root ganglia and the dorsal horn of the spinal cord in a rat model of transient mucosal inflammation induced by the nematode parasite *Trichinella spiralis*.⁴⁸ This increase very likely reflects over activation of the sensory afferent system in response to mucosal inflammation. Interestingly, intestinal inflammation was also found to result in altered visceral perception even in non-inflamed sites, suggesting the presence of abnormal viscerovisceral reflexes.⁴⁸

As some patients develop IBS after an acute episode of infectious enteritis, it has been postulated that ongoing inflammatory mechanisms may affect intestinal physiology and play a role in symptom generation.¹⁰ In selected strains of mice (that is, NIH Swiss), transient intestinal infection with *T spiralis* has been shown to evoke intestinal muscle dysfunction⁴⁹ and increased firing of primary afferents.⁵⁰ Both effects persist long after expulsion of the parasite from the gut and resolution of the acute mucosal inflammation. In this

model, which bears some similarities to human post-infective IBS, systemic corticosteroid treatment abolished the physiological dysfunction even if administered long after *T spiralis* had been completely expelled from the gut and acute inflammation had subsided.⁵¹ This evidence suggests that minimal inflammation may be a cause of persistent sensorimotor dysfunction.

On the basis of data showing that the muscularis externa has the potential to produce inflammatory mediators,⁵² attention has been focused on the synthesis and release of these mediators at the neuromuscular level. It has been demonstrated that persistent long term production of prostaglandin E₂ and increased expression of cyclooxygenase 2 (the inducible form involved in prostaglandin production) occurs at the neuromuscular level as an aftermath of acute *T spiralis* infection.⁵¹ More importantly, cyclooxygenase 2 inhibitors have been shown to attenuate the ongoing muscular dysfunction.⁵¹

CONCLUSIONS

There is increasing evidence of the presence of low grade inflammation in the intestinal mucosa of patients with IBS but the mechanisms involved in this process are by no means fully understood. As the available human data on low grade inflammation are often expressed as averages and are mainly focused on diarrhoea predominant IBS, it is unclear whether this event occurs only in selected subsets of patients with IBS (depending on symptom clusters, previous evidence of gastrointestinal infections, etc). Sex differences have so far generally been neglected which is an unfortunate omission given that IBS is more frequently observed in females,⁵³ and that visceral hypersensitivity following episodes of acute diarrhoea can be induced in female but not in male patients.⁵⁴

The stimulus for further studies may come from recent data in patients with severe impairment of intestinal motor function which suggest that the inflammatory changes may involve neuromuscular tissue as well as the mucosa.⁵⁵⁻⁵⁷ Preliminary data from patients with severe IBS symptoms indicated that an inflammatory infiltrate can sometimes be found in the myenteric plexus.⁵⁸ If confirmed, this interesting phenomenon may have important implications with respect to sensory and motor dysfunction of the intestinal tract. Another promising line of investigation concerns the role played by immunocytes other than mast cells in the production of low

grade inflammation and the interactions of these cells with the enteric sensory afferent system in patients with IBS.²⁴ Last, but not least, even though basic studies suggest that intestinal inflammation alters gut sensorimotor function, the actual pathogenetic role exerted by low grade inflammation in symptom generation in patients with IBS remains to be clarified. These represent just a few examples of how the evidence of low grade inflammation in the intestinal wall could open new lines of study into the pathophysiology of IBS. A working hypothesis on the role of low grade inflammation in IBS is summarised in figure 1.

ACKNOWLEDGEMENT

The authors wish to thank Dr Stephen M Collins for his extensive work in this field that inspired the present review.

Authors' affiliations

G Barbara, R De Giorgio, V Stanghellini, C Cremon, R Corinaldesi, Department of Internal Medicine and Gastroenterology, University of Bologna, Bologna, Italy

REFERENCES

- Camilleri M. Management of the irritable bowel syndrome. *Gastroenterology* 2001;**120**:652–68.
- Mertz H, Naliboff B, Munakata J, et al. Altered rectal perception is a biological marker of patients with irritable bowel syndrome. *Gastroenterology* 1995;**109**:40–52.
- Lembo T, Munakata J, Naliboff B, et al. Sigmoid afferent mechanisms in patients with irritable bowel syndrome. *Dig Dis Sci* 1997;**42**:1112–20.
- Schmulson M, Chang L, Naliboff B, et al. Correlation of symptom criteria with perception thresholds during rectosigmoid distension in irritable bowel syndrome patients. *Am J Gastroenterol* 2000;**95**:152–6.
- Ritchie J. Pain from distension of the pelvic colon by inflating a balloon in the irritable bowel syndrome. *Gut* 1973;**14**:125–32.
- Prior A, Maxton DG, Whorwell PJ. Anorectal manometry in irritable bowel syndrome: differences between diarrhoea and constipation predominant subjects. *Gut* 1990;**31**:458–62.
- Mayer EA, Gebhart GF. Basic and clinical aspects of visceral hyperalgesia. *Gastroenterology* 1994;**107**:271–93.
- Bueno L, Fioramonti J, Delvaux M, et al. Mediators and pharmacology of visceral sensitivity: from basic to clinical investigations. *Gastroenterology* 1997;**112**:1714–43.
- Collins SM. Irritable bowel syndrome could be an inflammatory disorder. *Eur J Gastroenterol Hepatol* 1994;**6**:478–82.
- Spiller RC, Jenkins D, Thornley JP, et al. Increased rectal mucosal enteroendocrine cells, T lymphocytes, and increased gut permeability following acute *Campylobacter* enteritis and in post-dysenteric irritable bowel syndrome. *Gut* 2000;**47**:804–11.
- Hiatt RB, Katz L. Mast cells in inflammatory conditions of the gastrointestinal tract. *Am J Gastroenterol* 1962;**37**:541–5.
- Lee E, Schiller LR, Fordtran JS. Quantification of colonic lamina propria cells by means of a morphometric point-counting method. *Gastroenterology* 1988;**94**:409–18.
- Salzmann JL, Peltier-Koch F, Bloch F, et al. Morphometric study of colonic biopsies: a new method of estimating inflammatory diseases. *Lab Invest* 1989;**60**:847–51.
- O'Sullivan M, Clayton N, Breslin NP, et al. Increased mast cells in the irritable bowel syndrome. *Neurogastroenterol Motil* 2000;**12**:449–57.
- Vassallo M, Camilleri M, Phillips SF, et al. Transit through the proximal colon influences stool weight in the irritable bowel syndrome. *Gastroenterology* 1992;**102**:102–8.
- Dapoigny M, Trolese JF, Bommelaer G, et al. Colonic response to the meal of the right colon, the left colon, the rectosigmoid and the rectosigmoidal junction in digestive functional disorders. *Gastroenterol Clin Biol* 1988;**12**:361–7.
- Kingham JG, Dawson AM. Origin of chronic right upper quadrant pain. *Gut* 1985;**26**:783–8.
- Swarbrick ET, Hegarty JE, Bat L, et al. Site of pain from the irritable bowel. *Lancet* 1980;**2**:443–6.
- Stead R, Tomioka M, Quinonez G, et al. Intestinal mucosal mast cells in normal and nematode-infected rat intestines are in intimate contact with peptidergic nerves. *Proc Natl Acad Sci USA* 1987;**84**:2975–9.
- Yonei Y, Oda M, Nakamura M. Evidence for direct interaction between the cholinergic nerve and mast cells in rat colonic mucosa. *J Clin Electron Microsc* 1985;**18**:560–1.
- Castro GA, Harari Y, Russell D. Mediators of anaphylaxis-induced ion transport changes in small intestine. *Am J Physiol* 1987;**253**:G540–8.
- Vermillion DL, Ernst PB, Scicchitano R, et al. Antigen-induced contraction of jejunal smooth muscle in the sensitized rat. *Am J Physiol* 1988;**255**:G701–8.
- Weston AP, Biddle WL, Bhatia PS, et al. Terminal ileal mucosal mast cells in irritable bowel syndrome. *Dig Dis Sci* 1993;**38**:1590–5.
- Barbara G, Stanghellini V, De Giorgio R, et al. Neuro-immune relationships in the colonic mucosa of irritable bowel syndrome patients. *Neurogastroenterol Motil* 2000;**12**:A272.
- Collins SM. The immunomodulation of enteric neuromuscular function: implications for motility and inflammatory disorders. *Gastroenterology* 1996;**111**:1683–99.
- Chan J, Gonsalkorale WM, Perrey C, et al. IL-10 and TGF- β genotypes in irritable bowel syndrome: evidence to support an inflammatory component? *Gastroenterology* 2000;**118**:A1191.
- Smout A, Azpiroz F, Coremans G, et al. Potential pitfalls in the differential diagnosis of irritable bowel syndrome. *Digestion* 2000;**61**:247–56.
- Barbara G, Corinaldesi R. Probiotics: could they turn out to be ineffective in irritable bowel syndrome? *Dig Liver Dis* 2000;**32**:302–4.
- Chaudhary NA, Truelove SC. The irritable colon syndrome. *Q J Med* 1962;**31**:307–22.
- Bergin AJ, Donnelly TC, McKendrick MW, et al. Changes in anorectal function in persistent bowel disturbance following salmonella gastroenteritis. *Eur J Gastroenterol Hepatol* 1993;**5**:617–20.
- McKendrick MW, Read NW. Irritable bowel syndrome—post salmonella infection. *J Infect* 1994;**29**:1–3.
- Gwee KA, Graham JC, McKendrick MW, et al. Psychometric scores and development of irritable bowel after infectious diarrhoea. *Lancet* 1996;**347**:150–3.
- Neal KR, Hebden J, Spiller R. Prevalence of gastrointestinal symptoms six months after bacterial gastroenteritis and risk factor for development of the irritable bowel syndrome: postal survey of patients. *BMJ* 1997;**314**:779–82.
- Gwee KA, Leong YL, Graham C, et al. The role of psychological and biological factors in postinfective gut dysfunction. *Gut* 1999;**44**:400–6.
- García Rodríguez LA, Ruigomez A. Increased risk of irritable bowel syndrome after bacterial gastroenteritis: cohort study. *BMJ* 1999;**318**:565–6.
- Barbara G, Stanghellini V, Berti-Ceroni C, et al. Role of antibiotic therapy on long-term germ faecal excretion and digestive symptoms after *Salmonella* infection. *Aliment Pharmacol Ther* 2000;**14**:1127–31.
- Morris-Yates A, Talley NY, Boyce PM, et al. Evidence of a genetic contribution to functional bowel disorder. *Am J Gastroenterol* 1998;**93**:1311–17.
- Maluenda C, Phillips AD, Briddon A, et al. Quantitative analysis of small intestinal mucosa in cows milk sensitive enteropathy. *J Pediatr Gastroenterol Nutr* 1984;**3**:349–56.
- Wershil BK, Furuta GT, Wang ZS, et al. Mast cell-dependent neutrophil and mononuclear cell recruitment in immunoglobulin E-induced gastric reactions in mice. *Gastroenterology* 1996;**110**:1482–90.
- Niec AM, Frankum B, Talley NJ. Are adverse food reactions linked to irritable bowel syndrome? *Am J Gastroenterol* 1998;**93**:2184–90.
- King TS, Elia M, Hunter JO. Abnormal colonic fermentation in irritable bowel syndrome. *Lancet* 1998;**352**:1187–9.
- Pimentel M, Chow EJ, Lin HC. Eradication of small intestinal bacterial overgrowth reduces symptoms of irritable bowel syndrome. *Am J Gastroenterol* 2000;**95**:3503–6.
- Balsari A, Ceccarelli A, Dubini F, et al. The faecal microbial population in the irritable bowel syndrome. *Microbiologica* 1982;**5**:185–94.
- Swidinski A, Klilkin M, Ortner M, et al. Alteration of bacterial concentration in colonic biopsies from patients with irritable bowel syndrome (IBS). *Gastroenterology* 1999;**116**:A1.
- Rao SS, Read NW, Brown C. Studies on the mechanism of bowel disturbance in ulcerative colitis. *Gastroenterology* 1987;**93**:934–40.
- Isgar B, Harman M, Kaye MD, et al. Symptoms of irritable bowel syndrome in ulcerative colitis in remission. *Gut* 1983;**24**:190–2.
- Loening-Baucke V, Metcalf AM, Shirazy S. Rectosigmoid motility in patients with quiescent and active ulcerative colitis. *Am J Gastroenterol* 1989;**84**:34–9.
- De Giorgio R, Barbara G, Blennerhassett P, et al. Intestinal inflammation and activation of sensory nerve pathways: a functional and morphological study in the nematode infected rat. *Gut* 2001;**49**:822–7.
- Barbara G, Vallance BA, Collins SM. Persistent intestinal neuromuscular dysfunction after acute nematode infection in mice. *Gastroenterology* 1997;**113**:1224–32.
- Mao Y, Wang L, Chen Y, et al. Hyperalgesic colonic sensory afferent pathways following *T. spiralis* enteritis: involvement of NK₁ receptors. *Gastroenterology* 2000;**118**:A701.
- Barbara G, De Giorgio R, Deng Y, et al. Role of immunologic factors and cyclooxygenase 2 in persistent postinfective enteric muscle dysfunction in mice. *Gastroenterology* 2001;**120**:1729–36.
- Van Assche G, Barbara G, Deng Y, et al. Neurotransmitters modulate cytokine-stimulated interleukin 6 secretion in rat intestinal smooth muscle cells. *Gastroenterology* 1999;**116**:346–53.
- Talley NJ, Zinsmeister AR, Melton LJ. Irritable bowel syndrome in a community: symptom subgroups, risk factors and healthcare utilization. *Am J Epidemiol* 1995;**142**:76–83.
- Houghton LA, Wych J, Whorwell PJ. Acute diarrhoea induces rectal sensitivity in women but not men. *Gut* 1995;**61**:435–9.
- Smith VV, Gregson N, Foggensteiner L, et al. Acquired intestinal anglionosis and circulating autoantibodies without neoplasia or other neural involvement. *Gastroenterology* 1998;**114**:421–2.
- De Giorgio R, Barbara G, Stanghellini V, et al. Idiopathic myenteric ganglionitis underlying intractable vomiting in a young adult. *Eur J Gastroenterol Hepatol* 2000;**12**:613–16.
- De Giorgio R, Stanghellini V, De Ponti F, et al. Primary enteric neuropathies underlying gastrointestinal motor dysfunction. *Scand J Gastroenterol* 2000;**35**:114–22.
- Tornblom H, Lindberg G, Veress B. Histopathological findings in the jejunum of patients with severe irritable bowel syndrome. *Gastroenterology* 2000;**118**:A140.