





# Spontaneous Transversal Changes of Lower Arch Following Palatal Skeletal Expansion

Francesca Cremonini<sup>1</sup>, Elena Adversi<sup>2</sup>, Paolo Albertini<sup>1</sup>, Giorgio Alfredo Spedicato<sup>3</sup>, Mario Palone<sup>1</sup>

<sup>1</sup>Department of Orthodontics, School of Dentistry, University of Ferrara, Ferrara, Italy.

<sup>2</sup>Private Practice, Pesaro, Italy.

<sup>3</sup>Department of Banking and Insurance, Catholic University of Milan, Milan, Italy.

**Correspondence:** Francesca Cremonini, Assistant Research Department of Orthodontics, School of Dentistry University of Ferrara, Ferrara, 44121, Italy. **E-mail:** [dr.ssafrancescacremonini@gmail.com](mailto:dr.ssafrancescacremonini@gmail.com)

**Academic Editor:** Alessandro Leite Cavalcanti

**Received:** 29 January 2021 / **Review:** 02 March 2021 / **Accepted:** 15 March 2021

**How to cite:** Cremonini F, Adversi E, Albertini P, Spedicato GA, Palone M. Spontaneous transversal changes of lower arch following palatal skeletal expansion. *Pesqui Bras Odontopediatria Clín Integr.* 2021; 21(supp1):e0019. <https://doi.org/10.1590/pboci.2021.087>

## ABSTRACT

**Objective:** To evaluate how the lower arch spontaneously change after upper rapid palatal expansion in a group of patients with transversal skeletal deficit. **Material and Methods:** Twenty-four patients treated by the same orthodontist with a rapid palatal expander (RPE) bounded on a deciduous molar have been selected. The sample was divided into two groups: no treatment was provided for group one, while group two was treated using a lip bumper or Schwarz appliance. For each patient, dental casts were collected when the RPE was bounded (T0) and at the end of treatment, 9 months  $\pm$  3 months later (T1). Each outcome was analyzed, providing descriptive statistics, main effects significance tests and post-hoc analyses with the objective to evaluate the variations between pre-treatment (T0) and post-treatment (T1) of each of them. **Results:** If the linear measurements are considered, a significant beneficial effect on both arches is observed. However, the upper arch always shows a major increase of all values at T1 with respect to the lower arch. Even though the post-hoc tables indicate that time differences are all statistically significant across considered partitions, the lower arch's increase is more pronounced in group two, where patients were treated in both arches. If the angular measurements are concerned, the increase of lingual crown inclination was found in all patients, independently from the type of treatment in lower arch. **Conclusion:** All patients show normalization of upper diameters, regardless of whether the lower arch was treated or not.

**Keywords:** Orthodontics; Palatal Expansion Technique; Orthodontics, Corrective.

## Introduction

Correction of transversal maxillary diameters is an important goal of orthodontic treatment: narrow arches and posterior crossbite are constant findings in daily practice [1-3]. A rapid palatal expander (RPE) is the most effective device at our disposal if the purpose is to obtain a widening of the median palatal suture and, consequently, skeletal expansion of the upper arch [4,5]. Some cases of maxillary transverse contraction do not show any posterior crossbite due to the establishment of lower premolars and molars compensations.

Because of reduced upper transversal diameters, posterior lower teeth tend to physiologically assume a negative torque to compensate the skeletal palatal deficit [6]. To obtain a recovery of lower arch transversal diameters and a decompensation of posterior teeth negative torque after expansion of upper arch, many devices have been proposed [7-9].

One of the most used is a removable lip bumper, particularly useful in those patients where buccal and labial muscles are quite contracted [10]. It is placed away from teeth and shield to the adjacent soft tissue forces. It must be worn full time to obtain the desired results. It also increases the arch length through passive lateral and anterior expansion, it's also effective in straightening teeth and gaining posterior space by distalizing the arch [11,12].

Murphy et al. [13] found that 50% of the mandibular expansion gained using lip-bumper is concentrated in the first 100 days and that 90% is obtained in the first 300 days [14]. This points out how the appliance is effective in decompensate the collapse of the lower arch after palatal expansion.

Alternatively, to expand the lower arch, a mandibular Schwarz appliance can be used. It fits along the lingual edge of the mandibular dentition and it extends along the gum line. An expansion screw is incorporated into the acrylic and should be activated once a week, with 0.25-0.50 of transversal vestibular crown tipping [15]. It has been demonstrated significant long-term stability of maxillary and mandibular perimeter augmentation (3.8-3.7 mm) using a Schwarz appliance and maxillary RPE [16-18].

Even if we don't use any mandibular devices, Haas stated that after a palatal expansion of 12-14 mm, a significant spontaneous expansion of the lower arch occurs due to an altered muscular balance between the tongue and the buccinators [19]. According to previous study [10], a permanent increase in the maxillary apical base leads to a significant and stable spontaneous increase in the mandibular arch's width.

Indeed, we intend to evaluate how the lower arch spontaneously changes after upper rapid palatal expansion in a group of patients with a transversal skeletal deficit. The null hypothesis claims that an untreated contracted lower arch allows the same upper expansion of a treated lower arch for its correct decompensation.

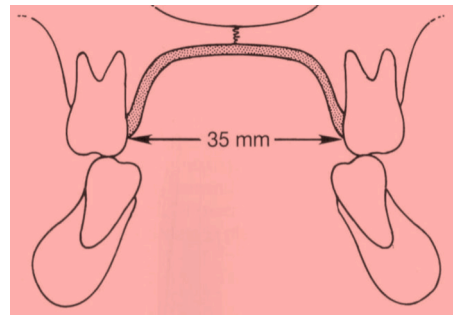
## Material and Methods

### Study Design and Sample

In this prospective study, twenty-four patients with mixed dentition in a pre-pubertal phase have been selected with the following inclusion criteria: 1) No previous orthodontic treatment; 2) ANB > 2°; 3) Cervical vertebral maturation stage: CVS1, according to Baccetti et al. [20]; 4) Upper transverse skeletal deficit; and 5) Compensatory contraction of the lower arch, with deep Wilson Curve. They have all been treated by the same orthodontist with a rapid palatal expander (Dentaurum Hyrax 10, Leone s.p.a, Sesto Fiorentino, Italy), bonded on deciduous second molar to minimize dental effects and any side effects on permanent teeth [21].

### Clinical Procedures

The activation of  $\frac{1}{4}$  round/day was performed since the contact of palatal cusps of the first upper molars with vestibular cusps of first lower molars (Figure 1).

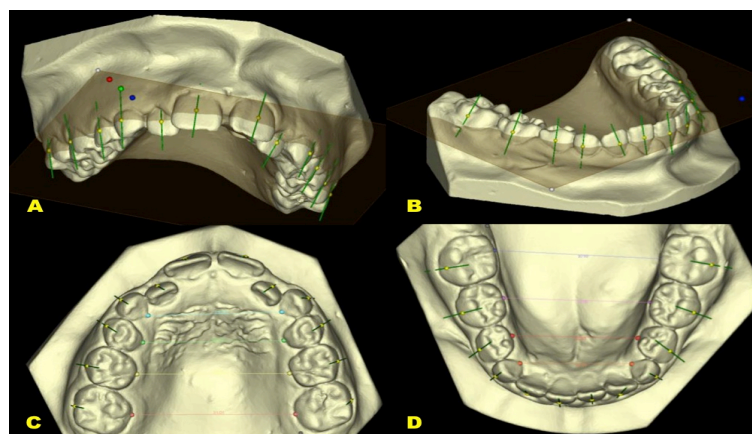


**Figure 1.** The limit of transversal palatal expansion is given by the contact with the lower arch.

At the end of palatal expansion, the total sample was divided into two groups, depending on the type of treatment chosen for lower arch:

- Group 1 (11 patients - 4 males and 7 females - 8 years and 6 months): spontaneous expansion of lower arch, with no appliances used;
- Group 2 (13 patients - 3 males and 10 females - 9 years and 4 months): a mandibular appliance was used to obtain a transversal expansion. Seven of these patients were treated with lip bumper, activated every month, and six with Schwarz appliance activated with  $\frac{1}{4}$  round/week.

Since it is not possible to structure such a double-blind study, the patients were divided into the two study groups based on when they arrived at our observation: the first patient was assigned to group one, and so on alternately. For each one, dental casts were collected when the RPE was bounded (T0) and at the end of treatment, 9 months  $\pm$  3 months later (T1). Then, all dental casts were scanned using an extraoral scanner (Optical ReVeng Orthodontic, Open Tech 3d srl, Italy). Virtual tridimensional scans (file.stl) were imported in NemoCast 3D (Nemotec Dental System, Dentauro Italia s.p.a, Bentivoglio, Italy) to make the following measurements: inter canine, inter molar, inter bicuspid diameters and the first permanent molar inclination in both arches. All measurements were made by the same operator, who was kept blind. Moreover, arch width was calculated from the lingual side of each tooth, considering the gingival margin at the lingual sulcus of the first permanent molar, as described by Brust and McNamara [22] (Figure 2). Finally, the numbers of appliance activations were registered to compare different protocols.



**Figure 2.** Reference points for width arch calculation.

## Statistical Analysis

A 13-rows dataset was collected on which the following outcomes were recorded: A) Inter canine distance; B) Inter first bicuspid distance; C) Inter second bicuspid distance; D) Inter molar distance; E) Torque right size; and F) Torque left size.

To simplify the analysis and interpretation of the results, each of the six variables was recalculated as the difference between T1 and T0: positive values indicate an increase in distances/degrees at T1. When close to zero, it points out stability between pre- and post-treatment. The study aims to statistically assess any differences between the two groups among times.

About the distances, descriptive statistics (number, average, and standard deviation) were carried out for each variable “distance” split by time, arch and group. It was verified whether the time, arch and group distances were different from each variable “distance” using a linear mixed model [23] and post-hoc tests on marginal means [24] using the Tukey approach. The linear mixed models included arch, group and time (when available) main effects and interaction, patient as a random effect (to allow for repeated measures). Normality test on the models’ residuals results was tested with the Shapiro-Wilk test. The statistical software R [25] and associated packages were used for statistical modeling. Statistical significance was assessed using a threshold of  $\alpha=0.05$  (5%).

## Results

According to the non-parametric Mann-Whitney test, the second group of patients, treated using lip bumper or Schwarz appliance, can be considered as one because none of the variables show any statistical significant difference.

If the linear measurements are considered, a significant beneficial effect on both arches is observed. However, the upper arch always shows a major increase of all values at T1 concerning the mandibular arch (Tables 1 to 4). Even though an increase in all diameters was confirmed, the increase in lower arch is more pronounced in group two, where patients were treated in both arches (Figure 3).

**Table 1. Inter canine distance: mean (SD) of the difference T1-T0.**

Time	Arch	Group	N	Mean	SD
T1	Upper	Upper + Lower	13	26.0	3.77
T1	Upper	Upper Only	11	26.3	4.46
T1	Lower	Upper + Lower	13	21.7	3.11
T1	Lower	Upper Only	11	22.7	3.07
T2	Upper	Upper + Lower	13	29.8	4.03
T2	Upper	Upper Only	11	30.4	4.10
T2	Lower	Upper + Lower	13	24.3	3.14
T2	Lower	Upper Only	11	23.7	3.27

**Table 2. Inter first bicuspid distance: mean (SD) of the difference T1-T0.**

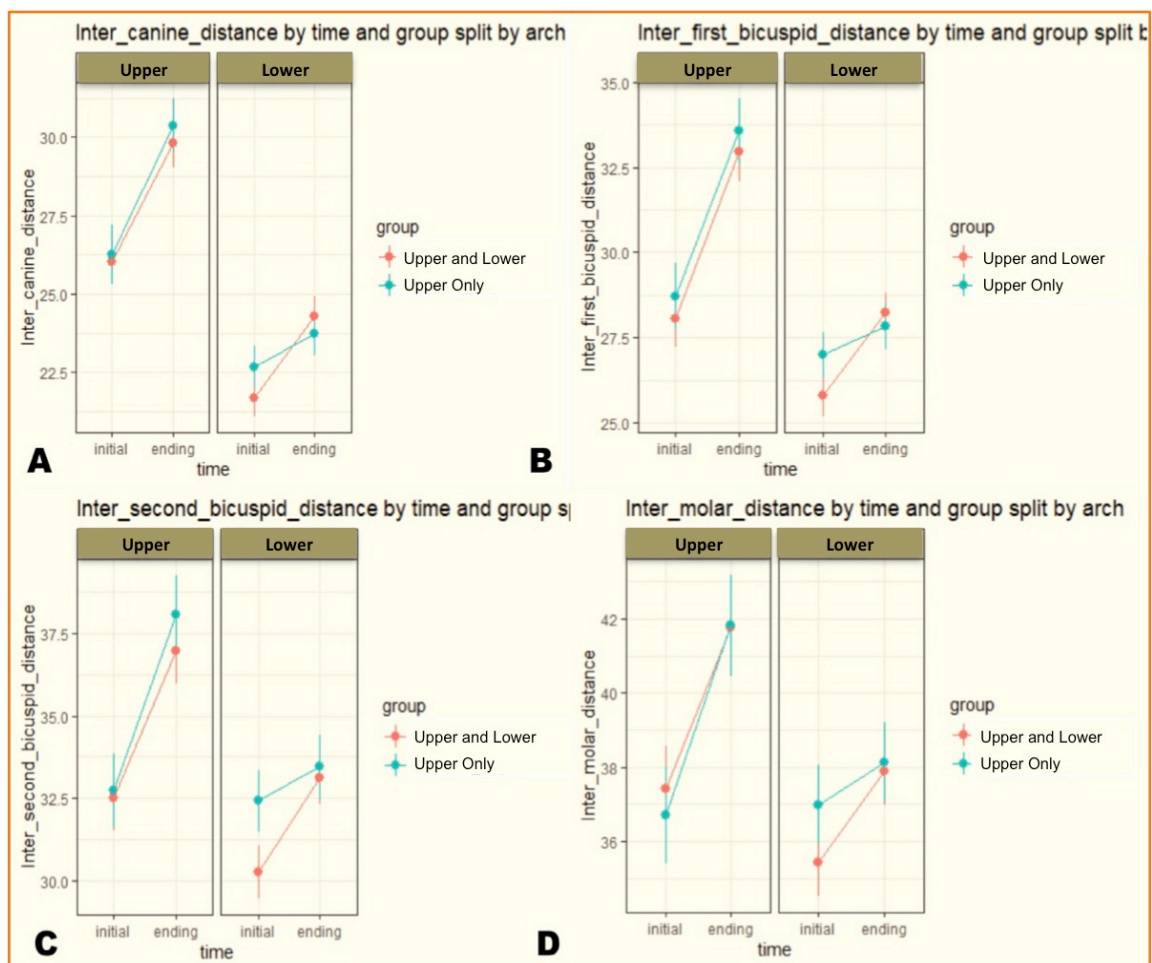
Time	Arch	Group	N	Mean	SD
T1	Upper	Upper + Lower	13	28.1	4.29
T1	Upper	Upper Only	11	28.7	4.55
T1	Lower	Upper + Lower	13	25.8	3.23
T1	Lower	Upper Only	11	27.0	3.18
T2	Upper	Upper + Lower	13	33.0	4.52
T2	Upper	Upper Only	11	33.6	4.53
T2	Lower	Upper + Lower	13	28.2	2.89
T2	Lower	Upper Only	11	27.8	3.24

**Table 3. Inter second bicuspid distance: mean (SD) of the difference T1-T0.**

Time	Arch	Group	N	Mean	SD
T1	Upper	Upper + Lower	13	32.5	5.11
T1	Upper	Upper Only	11	32.7	5.19
T1	Lower	Upper + Lower	13	30.3	4.12
T1	Lower	Upper Only	11	32.4	4.37
T2	Upper	Upper + Lower	13	37.0	5.06
T2	Upper	Upper Only	11	38.1	5.50
T2	Lower	Upper + Lower	13	33.1	4.10
T2	Lower	Upper Only	11	33.5	4.53

**Table 4. Inter molar distance: mean (SD) of the difference T1-T0.**

Time	Arch	Group	N	Mean	SD
T1	Upper	Upper + Lower	13	37.4	5.94
T1	Upper	Upper Only	11	36.7	6.23
T1	Lower	Upper + Lower	13	35.4	4.71
T1	Lower	Upper Only	11	37.0	5.02
T2	Upper	Upper + Lower	13	41.8	6.00
T2	Upper	Upper Only	11	41.8	6.43
T2	Lower	Upper + Lower	13	37.9	4.70
T2	Lower	Upper Only	11	38.1	5.08



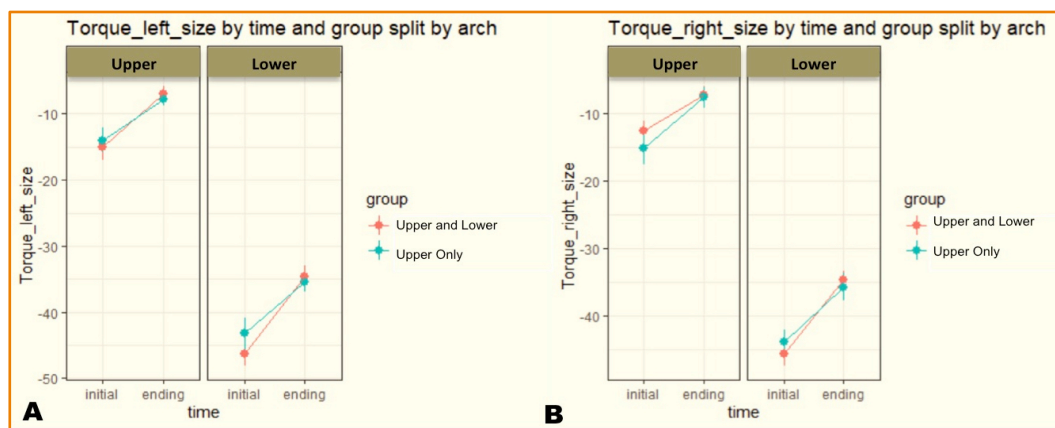
**Figure 3. Trend over time of the parameter: (A) Inter canine diameter; (B) Inter first bicuspid diameter; (C) Inter second bicuspid diameter; (D) Inter molar diameter.**



If the angular measurements of the lower arch are considered, the factor "arches" is the one that shows a greater significance: on average, crown inclination values of mandibular arch increase more than the crown inclination values of the upper arch (Table 5). The type of treatment does not determine any kind of variation in results (Figure 4).

**Table 5. Torque left and right side: mean (SD) of the difference T1-T0.**

Time	Arch	Group	N	Left Side		Right Side	
				Mean	SD	Mean	SD
T1	Upper	Upper + Lower	13	-15.06	6.86	-12.45	5.21
T1	Upper	Upper Only	11	-13.97	6.09	-15.16	7.60
T1	Lower	Upper + Lower	13	-46.33	6.56	-45.59	6.46
T1	Lower	Upper Only	11	-43.23	7.98	-43.84	5.82
T2	Upper	Upper + Lower	13	-6.98	4.42	-7.23	4.98
T2	Upper	Upper Only	11	-7.81	3.16	-7.58	5.29
T2	Lower	Upper + Lower	13	-34.61	5.75	-34.62	4.89
T2	Lower	Upper Only	11	-35.50	4.61	-35.70	6.79



**Figure 4. Trend over time of the parameter: (A) Torque left size; (B) Torque right size.**

The post-hoc tables indicate that time differences are statistically significant across considered partitions (Tables 7 to 12). Statistically significant differences between group 1 and group 2 were observed for each outcome, except for inter molar distance and torque right/left inclination (Figures 9 to 14). The post-hoc tables indicate that time differences are all statistically significant across considered partitions. The p-values of the Shapiro-Test ( $p > 0.05$ ) indicate that the normality assumptions on which the modeling approach is based hold for all variables (Table 13).

**Table 7. Post-hoc analysis: Inter canine distance.**

Contrast	Arch	Group	Estimate	SE	Df	Lower.CL	Upper.CL	T.ratio	p-value
T1-T0	Upper	Upper + Lower	3.78	0.362	162	3.062	4.49	10.43	0.000
T1-T0	Lower	Upper + Lower	2.60	0.362	162	1.885	3.31	7.18	0.000
T1-T0	Upper	Upper Only	4.13	0.394	162	3.350	4.90	10.49	0.000
T1-T0	Lower	Upper Only	1.06	0.394	162	0.284	1.84	2.70	0.008

**Table 8. Post-hoc analysis: Inter first bicuspid distance.**

Contrast	Arch	Group	Estimate	SE	Df	Lower.CL	Upper.CL	T.ratio	p-value
T1-T0	Upper	Upper + Lower	4.911	0.368	162	4.184	5.64	13.34	0.000
T1-T0	Lower	Upper + Lower	2.427	0.368	162	1.700	3.15	6.59	0.000
T1-T0	Upper	Upper Only	4.867	0.400	162	4.077	5.66	12.16	0.000
T1-T0	Lower	Upper Only	0.845	0.400	162	0.055	1.64	2.11	0.036

**Table 9. Post-hoc analysis: Inter second bicuspid distance.**

Contrast	Arch	Group	Estimate	SE	Df	Lower.CL	Upper.CL	T.ratio	p-value
T1-T0	Upper	Upper + Lower	4.46	0.409	162	3.650	5.26	10.91	0.000
T1-T0	Lower	Upper + Lower	2.84	0.409	162	2.029	3.64	6.94	0.000
T1-T0	Upper	Upper Only	5.35	0.444	162	4.475	6.23	12.05	0.000
T1-T0	Lower	Upper Only	1.02	0.444	162	0.145	1.90	2.30	0.023

**Table 10. Post-hoc analysis: Inter molar distance.**

Contrast	Arch	Group	Estimate	SE	Df	Lower.CL	Upper.CL	T.ratio	p-value
T1-T0	Upper	Upper + Lower	4.37	0.423	162	3.530	5.20	10.32	0.000
T1-T0	Lower	Upper + Lower	2.46	0.423	162	1.629	3.30	5.83	0.000
T1-T0	Upper	Upper Only	5.12	0.460	162	4.213	6.03	11.13	0.000
T1-T0	Lower	Upper Only	1.13	0.460	162	0.223	2.04	2.46	0.015

**Table 11. Post-hoc analysis: Torque left side.**

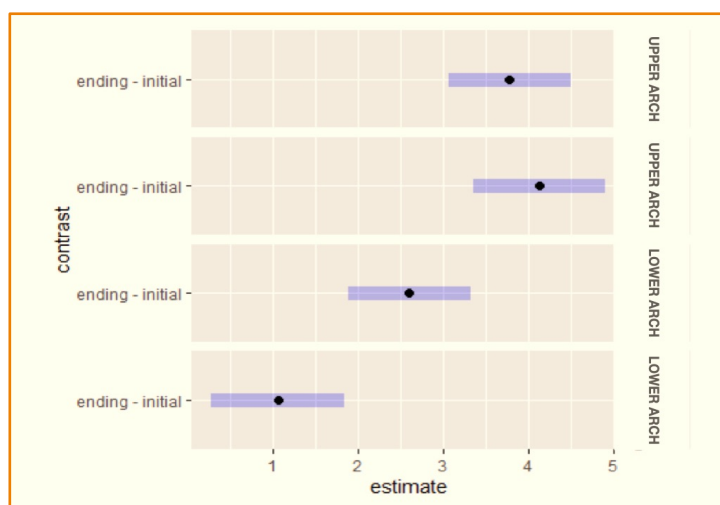
Contrast	Arch	Group	Estimate	SE	Df	Lower.CL	Upper.CL	T.ratio	p-value
T1-T0	Upper	Upper + Lower	-8.09	1.66	67	-11.40	-4.77	-4.87	0.000
T1-T0	Lower	Upper + Lower	-11.72	1.66	67	-15.04	-8.41	-7.07	0.000
T1-T0	Upper	Upper Only	-6.16	1.80	67	-9.76	-2.56	-3.42	0.001
T1-T0	Lower	Upper Only	-7.73	1.80	67	-11.33	-4.13	-4.28	0.000

**Table 12. Post-hoc analysis: Torque right side.**

Contrast	Arch	Group	Estimate	SE	Df	Lower.CL	Upper.CL	T.ratio	p-value
T1-T0	Upper	Upper + Lower	-5.21	2.00	67.1	-9.21	-1.22	-2.61	0.011
T1-T0	Lower	Upper + Lower	-10.97	2.00	67.1	-14.96	-6.98	-5.48	0.000
T1-T0	Upper	Upper Only	-7.58	2.17	67.1	-11.92	-3.24	-3.49	0.001
T1-T0	Lower	Upper Only	-8.14	2.17	67.1	-12.48	-3.80	-3.74	0.000

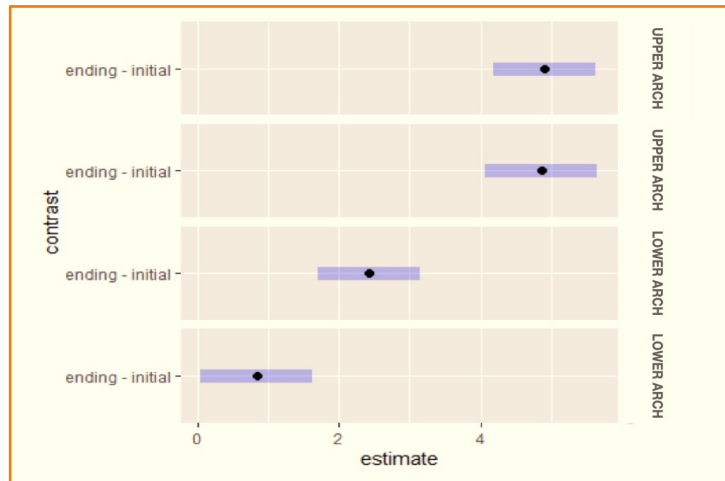
**Table 13. Shapiro-Wilk test p-values on model's residuals.**

Variables	p-value
Inter Canine Distance	0.437
Inter First Bicuspid Distance	0.701
Inter Second Bicuspid Distance	0.300
Inter Molar Distance	0.828
Torque Right Size	0.048
Torque Left Size	0.273



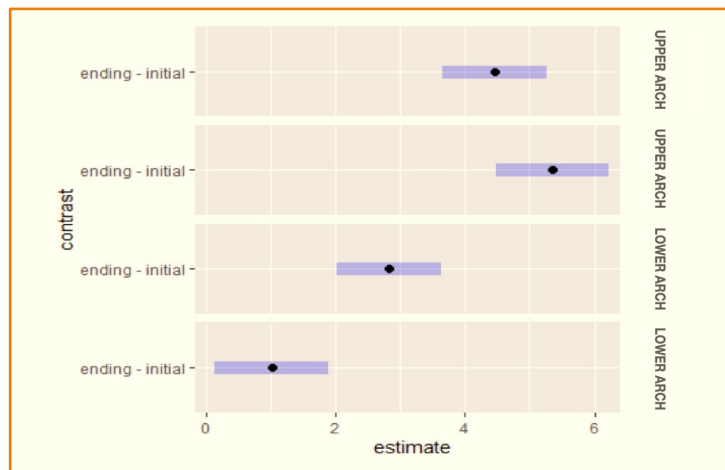
On the abscissa, the estimated values of the marginal effects of the model, while on the ordinate the time differences in relation to the arch and the group.

**Figure 9. Post hoc analysis for inter-canine diameter with confidence bands.**



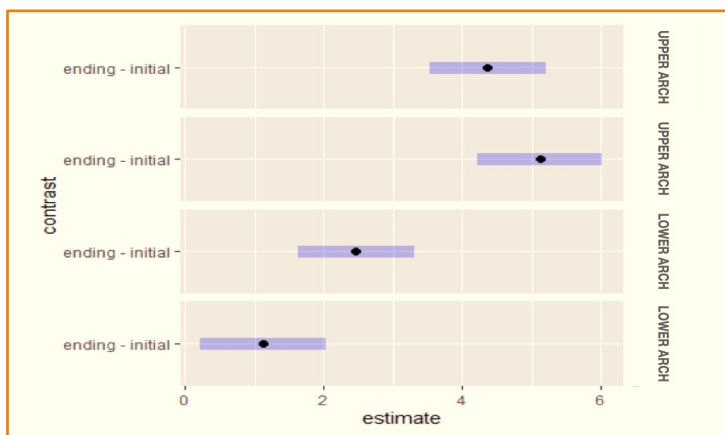
On the abscissa, the estimated values of the marginal effects of the model, while on the ordinate the time differences in relation to the arch and the group.

**Figure 10. Post hoc analysis for inter first bicuspid diameter with confidence bands.**



On the abscissa, the estimated values of the marginal effects of the model, while on the ordinate the time differences in relation to the arch and the group.

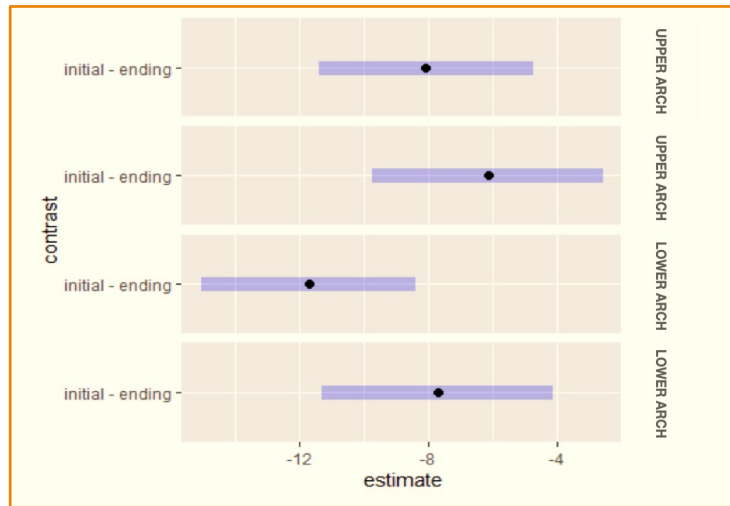
**Figure 11. Post hoc analysis for inter second bicuspid diameter with confidence bands.**



On the abscissa, the estimated values of the marginal effects of the model, while on the ordinate the time differences in relation to the arch and the group.

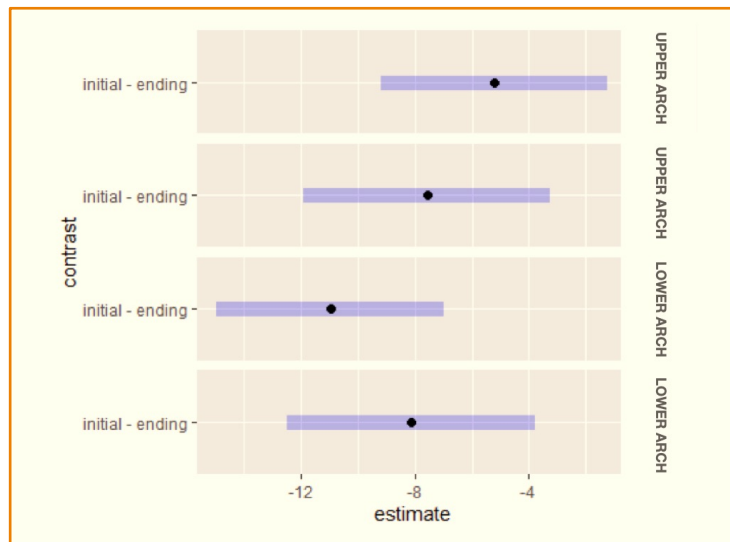
**Figure 12. Post hoc analysis for inter molar diameter with confidence bands.**





On the abscissa, the estimated values of the marginal effects of the model, while on the ordinate the time differences in relation to the arch and the group.

**Figure 13. Post hoc analysis for torque left size with confidence bands.**



On the abscissa, the estimated values of the marginal effects of the model, while on the ordinate the time differences in relation to the arch and the group.

**Figure 14. Post hoc analysis for torque right size with confidence bands.**

## Discussion

The objective of orthopedic treatment is to obtain an ideal skeletal relationship between the maxillaries. Rapid maxillary expansion (RME) has always been the election treatment for the correction of posterior crossbite and transverse deficiency, thanks to the possibility of separating the mid-palatal suture before its ossification [16].

Although orthopedic treatment effects with RPE have been widely studied, little is known about dentoalveolar effects of RME in mandibular arch [26]. The assumption has been that upper expansion could induce functional uprighting of mandibular posterior teeth. However, some studies have confirmed [27], while others have refuted [28], the spontaneous increase in lower inter molar and inter canine widths, no definitive consensus was reached.

Indeed, the maxillary skeletal morphology seems to influence the mandibular dentition position more than the lower jaw's size and shape. Weak evidence suggests that using a lower appliance, such as a lip bumper, can determine a further increase in mandibular arch perimeter after rapid upper expansion [29]. Another conclusion was made by O'Grady et al. [16], who stated that Schwarz appliance's use leads to a major expansion of mandibular arch in the long term. In the current study, although all patients show an increase of lower diameters, the ones treated with lip bumper or Schwarz appliance gained a more statistically significant expansion.

The graphical interpretation of the post hoc analysis highlights that all outcomes have a higher estimated value at T1 concerning T0, which is statistically significant just in the lower arch for inter canine, inter first and second bicuspid diameter. However, the difference in linear distances at T1 and T0 are positive in both groups, indicating that in any case, an increase of mandibular widths is observed, independently from the kind of lower treatment. This result is comparable to the conclusions made by Lima et al. [27], who pointed out that the mandibular arch tends to fit the upper arch once expanded. They hypothesize that occlusal forces and tongue/perioral muscles balance to play the most important role.

Handelman et al. [30] and McNamara et al. [31] found very similar improvements concerning the maxillary molars and bicuspids (between 4.8 and 3.7 mm for molars and first bicuspids, and between 2.3 and 2.2 mm for second bicuspids). For the mandibular arch widths, much less expansion was found in the first study. A possible explanation is that the sample of Handelman et al. [30] was made of adult patients, whereas McNamara's sample was made of adolescents. Moussa et al. [32] also concluded that the lower inter molar and inter cuspid widths in adult patients presented a greater relapse tendency because structures are less adaptable in adult patients. However, in this study, the patients were examined at the end of the second phase of treatment using a fixed appliance. Currently, we analyzed just short-term effects.

It is crucial that the upper expansion stops when the first upper molar palatal cusp encounters the first lower molar vestibular cusp. This contact creates a slide surface, which allows a lower self-expansion through masticatory forces and neuromuscular system [6]. Even the tongue pressure, maintained low by the presence of RPE, could be a further stimulation to lower expansion. In the alternative, many different functional appliances are available to remove possible external pressure to spontaneous expansion.

A great limit of the current study is the sample and variable sample considered. The number of predictors and the model design (mixed effect models with interaction and control variables) do not permit to use close-form analytical formulas to assess numerically the sample adequacy.

Future studies may have the goal of including an increased number of patients treated with the same expansion protocol in both arches. Moreover, it would also be interesting to evaluate the long-term effects of maxillary and mandibular skeletal expansion obtained at this age.






It must be pointed out that the present study tested just conventional palatal expander. Recently, miniscrew supported expanders have been proposed, showing excellent mechanical properties with miniscrews of different diameters and materials [33-35] and reducing the risk of root resorption [36].

Previous evidence confirmed that skeletal anchorage could increase the skeletal effect of RME, extending the benefits of this therapy to late adolescence and adulthood. Also, it appeared that bone-borne RME limited the tipping of posterior maxillary teeth. However, just one CBCT study has assessed the potential effects of bone-borne RME on the mandibular arch compared to conventional tooth-borne RME. From a clinical perspective, the conclusion was that the small amount of post-treatment expansion in the mandible would not determine a significant gain of space in the lower arch after RME.

## Conclusion

All patients show normalization of upper diameters, regardless of whether the mandibular arch was treated or not. However, it is pointed out that if the patients where mandibular arch was treated by means of Lip bumper or Schwarz appliance, the lower dentoalveolar effects were pronounced. This means that the null hypothesis cannot be accepted. The major lower expansion allowed after using lip bumper or Schwarz appliance is statistically significant but not clinically relevant. This is confirmed by the fact that the mandibular arch's decompensation was equally obtained in all patients.

## Authors' Contributions

FC		<a href="https://orcid.org/0000-0002-4641-2196">https://orcid.org/0000-0002-4641-2196</a>	Conceptualization, Methodology, Formal Analysis, Investigation, Writing - Original Draft and Writing - Review and Editing.
EA		—	Data Curation and Writing - Review and Editing.
PA		<a href="https://orcid.org/0000-0002-4020-5065">https://orcid.org/0000-0002-4020-5065</a>	Formal Analysis and Writing - Review and Editing.
GAS		<a href="https://orcid.org/0000-0002-0315-8888">https://orcid.org/0000-0002-0315-8888</a>	Formal Analysis.
MP		<a href="https://orcid.org/0000-0001-6198-3053">https://orcid.org/0000-0001-6198-3053</a>	Conceptualization and Writing - Review and Editing.
All authors declare that they contributed to critical review of intellectual content and approval of the final version to be published.			

## Financial Support

None.

## Conflict of Interest

The authors declare no conflicts of interest.

## Data Availability

The data used to support the findings of this study can be made available upon request to the corresponding author.

## References

- [1] Thilander B, Wahlund S, Lennartsson B. The effect of early interceptive treatment in children with posterior cross-bite. *Eur J Orthod* 1984; 6(1):25-34. <https://doi.org/10.1093/ejo/6.1.25>.
- [2] Kuroi J, Berglund L. Longitudinal study and cost-benefit analysis of the effect of early treatment of posterior cross-bites in the primary dentition. *Eur J Orthod* 1992; 14(3):173-9. <https://doi.org/10.1093/ejo/14.3.173>
- [3] Arreghini A, Lombardo L, Mollica F, Siciliani G. Torque expression capacity of 0.018 and 0.022 bracket slots by changing archwire material and cross section. *Prog Orthod* 2014; 15(1):53. <https://doi.org/10.1186/s40510-014-0053-x>
- [4] Gracco A, Luca L, Cozzani M, Siciliani G. Assessment of palatal bone thickness in adults with cone beam computerised tomography. *Aust Orthod J* 2007; 23(2):109-13.
- [5] Zhou Y, Long H, Ye N, Xue J, Yang X, Liao L, et al. The effectiveness of non-surgical maxillary expansion: a meta-analysis. *Eur J Orthod* 2014; 36(2):233-42. <https://doi.org/10.1093/ejo/cjt044>
- [6] Mutinelli S, Manfredi M, Cozzani M. A mathematic-geometric model to calculate variation in mandibular arch form. *Eur J Orthod* 2000; 22(2):113-25. <https://doi.org/10.1093/ejo/22.2.113>
- [7] Haas AJ. Rapid expansion of the maxillary dental arch and nasal cavity by opening the midpalatal suture. *Angle Orthod* 1961; 31(2):73-90.
- [8] Pisani L, Bonaccorso L, Fastuca R, Spina R, Lombardo L, Caprioglio A. Systematic review for orthodontic and orthopedic treatments for anterior open bite in the mixed dentition. *Prog Orthod* 2016; 17(1):28. <https://doi.org/10.1186/s40510-016-0142-0>
- [9] Lombardo L, Toni G, Stefanoni F, Mollica F, Guarneri MP, Siciliani G. The effect of temperature on the mechanical behavior of nickel-titanium orthodontic initial archwires. *Angle Orthod* 2013; 83(2):298-305. <https://doi.org/10.2319/040612-287.1>
- [10] Greenfield RL. Clinical application of a modified lip bumper. *J Clin Orthod* 2011; 45(2):99-111.
- [11] Buschang PH. Maxillomandibular expansion: short-term relapse potential and long-term stability. *Am J Orthod Dentofacial Orthop* 2006; 129(4 Suppl):S75-S79. <https://doi.org/10.1016/j.ajodo.2005.09.019>
- [12] Di Fazio D, Lombardo L, Gracco A, D'Amico P, Siciliani G. Lip pressure at rest and during function in 2 groups of patients with different occlusions. *Am J Orthod Dentofacial Orthop* 2011; 139(1):e1-e6. <https://doi.org/10.1016/j.ajodo.2010.02.030>

- [13] Murphy CC, Magness WB, English JD, Frazier-Bowers SA, Salas AM. A longitudinal study of incremental expansion using a mandibular lip bumper. *Angle Orthod* 2003; 73(4):396-400.
- [14] Arreghini A, Trigila S, Lombardo L, Siciliani G. Objective assessment of compliance with intra- and extraoral removable appliances. *Angle Orthod* 2017; 87(1):88-95. <https://doi.org/10.2319/020616-104.1>
- [15] Motoyoshi M, Hirabayashi M, Shimazaki T, Namura S. An experimental study on mandibular expansion: increases in arch width and perimeter. *Eur J Orthod* 2002; 24(2):125-30. <https://doi.org/10.1093/ejo/24.2.125>
- [16] O'Grady PW, McNamara JA Jr, Baccetti T, Franchi L. A long-term evaluation of the mandibular Schwarz appliance and the acrylic splint expander in early mixed dentition patients. *Am J Orthod Dentofacial Orthop* 2006; 130(2):202-13. <https://doi.org/10.1016/j.ajodo.2004.12.023>
- [17] Lopez MA, Andreasi Bassi M, Confalone L, Gaudio RM, Lombardo L, Lauritano D. Retrospective study on bone-level and soft-tissue-level cylindrical implants. *J Biol Regul Homeost Agents* 2016; 30(2 Suppl 1):43-8.
- [18] Lopez MA, Andreasi Bassi M, Confalone L, Gaudio RM, Lombardo L, Lauritano D. Clinical outcome of 215 transmucosal implants with a conical connection: a retrospective study after 5-year follow-up. *J Biol Regul Homeost Agents* 2016; 30(2 Suppl 1):55-60.
- [19] Haas AJ. Long-term posttreatment evaluation of rapid palatal expansion. *Angle Orthod* 1980; 50(3):189-217.
- [20] Baccetti T, Franchi L, McNamara Jr JA. The cervical vertebral maturation (CVM) method for the assessment of optimal treatment timing in dentofacial orthopedics. *Semin Orthod* 2005; 11(3):119-29.
- [21] Cozzani M, Rosa M, Cozzani P, Siciliani G. Deciduous dentition-anchored rapid maxillary expansion in crossbite and non-crossbite mixed dentition patients: reaction of the permanent first molar. *Prog Orthod* 2003; 4:15-22. <https://doi.org/10.1034/j.1600-9975.2002.02034.x>
- [22] Brust EW, McNamara JA Jr. Arch Dimensional Changes Concurrent with Expansion in Mixed Dentition Patients. In: Trotman CA, McNamara JA Jr, Editors. *Orthodontic Treatment: Outcome and Effectiveness. Monograph 30. Craniofacial Growth Series.* Ann Arbor: Center for Human Growth and Development; University of Michigan; 1995.
- [23] Bates D, Machler M, Bolker B, Walker S. Fitting linear mixed-effects Models using Ime4. *J Stat Softw* 2015; 67(1):1-48.
- [24] Ghasemi A, Zahediasl S. Normality tests for statistical analysis: A guide for Non-statisticians. *Ann Stat* 2001; 29(4):1165-88.
- [25] R Core Team. 2020. R: A Language and Environment for Statistical Computing. Vienna, Austria: R Foundation for Statistical Computing. Available from: <https://www.R-project.org/>. [Accessed on January 10, 2021].
- [26] Küçükkeleş N, Ceylanoglu C. Changes in lip, cheek, and tongue pressures after rapid maxillary expansion using a diaphragm pressure transducer. *Angle Orthod* 2003; 73(6):662-8.
- [27] Lima AC, Lima AL, Lima Filho RM, Oyen OJ. Spontaneous mandibular arch response after rapid palatal expansion: a long-term study on Class I malocclusion. *Am J Orthod Dentofacial Orthop* 2004; 126(5):576-82.
- [28] Petrén S, Bondemark L. Correction of unilateral posterior crossbite in the mixed dentition: a randomized controlled trial. *Am J Orthod Dentofacial Orthop* 2008; 133(6):790.e7-13. <https://doi.org/10.1016/j.ajodo.2007.11.021>
- [29] Santana LG, de Campos França E, Flores-Mir C, Abreu LG, Marques LS, Martins-Junior PA. Effects of lip bumper therapy on the mandibular arch dimensions of children and adolescents: A systematic review. *Am J Orthod Dentofacial Orthop* 2020; 157(4):454-465.e1. <https://doi.org/10.1016/j.ajodo.2019.10.014>
- [30] Handelman CS, Wang L, BeGole EA, Haas AJ. Nonsurgical rapid maxillary expansion in adults: report on 47 cases using the Haas expander. *Angle Orthod* 2000; 70(2):129-44.
- [31] McNamara JA Jr, Baccetti T, Franchi L, Herberger TA. Rapid maxillary expansion followed by fixed appliances: a long-term evaluation of changes in arch dimensions. *Angle Orthod* 2003; 73(4):344-53.
- [32] Moussa R, O'Reilly MT, Close JM. Long-term stability of rapid palatal expander treatment and edgewise mechanotherapy. *Am J Orthod Dentofacial Orthop* 1995; 108(5):478-88. [https://doi.org/10.1016/s0889-5406\(95\)70048-x](https://doi.org/10.1016/s0889-5406(95)70048-x)
- [33] Sfondrini MF, Gandini P, Alcozer R, Vallittu PK, Scribante A. Failure load and stress analysis of orthodontic miniscrews with different transmucosal collar diameter. *J Mech Behav Biomed Mater* 2018; 87:132-7. <https://doi.org/10.1016/j.jmbbm.2018.07.032>
- [34] Krüsi M, Eliades T, Papageorgiou SN. Are there benefits from using bone-borne maxillary expansion instead of tooth-borne maxillary expansion? A systematic review with meta-analysis. *Prog Orthod* 2019; 20(1):9. <https://doi.org/10.1186/s40510-019-0261-5>
- [35] Lo Giudice A, Ronsivalle V, Lagravere M, Leonardi R, Martina S, Isola G. Transverse dentoalveolar response of mandibular arch after rapid maxillary expansion (RME) with tooth-borne and bone-borne appliances. *Angle Orthod* 2020; 90(5):680-7. <https://doi.org/10.2319/042520-353.1>
- [36] Lombardo L, Carinci F, Martini M, Gemmati D, Nardone M, Siciliani G. Quantitative evaluation of dentin sialoprotein (DSP) using microbeads - a potential early marker of root resorption. *Oral Implantol* 2016; 9(3):132-42. <https://doi.org/10.11138/orl/2016.9.3.132>