

# Deep anterior lamellar keratoplasty for keratoconus: Elements for success

Marco Pellegrini<sup>1,2,3</sup>, Angeli Christy Yu<sup>1,2,3</sup>, Massimo Busin<sup>1,2,3</sup>

<b>Access this article online</b>
Quick Response Code:

<b>Website:</b> www.saudijophthalmol.org
<b>DOI:</b> 10.4103/sjopt.sjopt_100_21

## Abstract:

Advanced keratoconus may require keratoplasty when the patient can no longer achieve functional vision with glasses and contact lenses. Deep anterior lamellar keratoplasty (DALK) has become the surgical treatment of choice due to its undisputed advantages over penetrating keratoplasty including the reduced risk of intraoperative complications, the absence of endothelial immune rejection, and the longer graft survival. Albeit “big-bubble” DALK still represents the most popular surgical method, several modifications have been developed over the years. This allowed standardization of the technique, with improved success rates and clinical outcomes. This review presents an overview on the literature on DALK surgery for keratoconus. We discuss state-of-the art surgical techniques, current evidence on the clinical outcomes and complications as well as possible future directions.

## Keywords:

DALK; Deep anterior lamellar keratoplasty; Keratoconus

## INTRODUCTION

Keratoconus is a progressive ectatic disorder in which the cornea assumes a conical shape due to thinning and protrusion. This leads to irregular astigmatism, myopia, and visual impairment.<sup>[1]</sup> Keratoplasty is usually required in advanced stages of the disease when the patient can no longer achieve functional vision with glasses and contact lenses.<sup>[2]</sup>

Penetrating keratoplasty (PK) has been considered the mainstay of surgical treatment for decades.<sup>[3]</sup> More recently, deep anterior lamellar keratoplasty (DALK) has become an alternative to PK, with the advantages of eliminating the risk of endothelial rejection and avoiding the complications associated with open-sky surgery.<sup>[4]</sup>

Despite these undisputed advantages, the uptake of DALK among corneal surgeons has been relatively slow, particularly in the U.S.<sup>[5]</sup> Longer surgical time, steep learning curve, and low patient volume and have been reported as the most important barriers to adoption of

DALK.<sup>[6]</sup> Nevertheless, recent innovations in surgical technique, instrumentation and tissue preparation allowed standardization of DALK, with improved success rates even for inexperienced surgeons.<sup>[7]</sup>

This review provides an update on lamellar keratoplasty for keratoconus. Three key aspects will be covered: The rapidly changing techniques of modern lamellar surgery; the current evidence on the clinical outcomes and complications; the possible future developments in this evolving specialty.

## SURGICAL TECHNIQUE

Different techniques to perform DALK have been proposed, including layer-by-layer manual dissection, pneumatic dissection, and viscoelastic-assisted dissection.<sup>[8-10]</sup> The method of pneumatic dissection through injection of a “big bubble” described by Anwar<sup>[9]</sup> represents the most popular surgical method. The technique involves partial-thickness trephination of the corneal stroma followed by forceful injection of air into the deep stroma through a needle or cannula to form a “big bubble” [Figure 1a and b]. After anterior keratectomy, the roof of the bubble is then incised under viscoelastic protection and

<sup>1</sup>Department of Translational Medicine, University of Ferrara,  
<sup>2</sup>Department of Ophthalmology, Ospedali Privati Forlì “Villa Igea”  
<sup>3</sup>Istituto Internazionale per la Ricerca e Formazione in Oftalmologia (IRFO), Forlì, Italy

### Address for correspondence:

Prof. Massimo Busin,  
Ospedali Privati Forlì ‘Villa Igea’, Forlì 47122, Italy.  
E-mail: mbusin@yahoo.com

Submitted: 03-May-2021

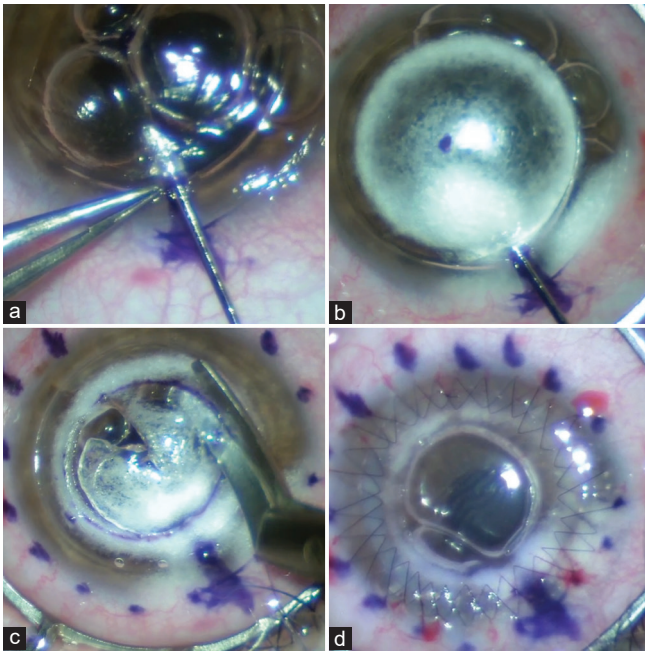
Accepted: 20-Dec-2021

Published: 11-Jul-2022

This is an open access journal, and articles are distributed under the terms of the Creative Commons Attribution-NonCommercial-ShareAlike 4.0 License, which allows others to remix, tweak, and build upon the work non-commercially, as long as appropriate credit is given and the new creations are licensed under the identical terms.

For reprints contact: WKHLRPMedknow\_reprints@wolterskluwer.com

**How to cite this article:** Pellegrini M, Yu AC, Busin M. Deep anterior lamellar keratoplasty for keratoconus: Elements for success. Saudi J Ophthalmol 2022;36:36-41.



**Figure 1:** Surgical technique for deep anterior lamellar keratoplasty. After 9 mm partial thickness trephination, a Fogla cannula is inserted at the base of trephination and advanced centripetally (a); air is injected into the deep stroma to obtain a big bubble (b); after anterior keratectomy, the roof of the bubble is excised with corneal scissors limiting the stromal clearance to the central 6 mm optical zone (c); the graft is sutured into place using 16-bite double running sutures (d)

the remaining stroma is excised using blunt scissors [Figure 1c]. Finally, the donor tissue is punched and sutured into place using interrupted or running sutures [Figure 1d].<sup>[11,12]</sup>

To maximize the likelihood of pneumatic dissection, the cannula should be inserted as deep as possible, with over 90% success rate if air is injected within 100  $\mu\text{m}$  of the posterior corneal surface.<sup>[13]</sup> The feeling of decreased tissue resistance to the advancement of the cannula usually indicates that depth is appropriate. Pupil dilation and use of the intraoperative red reflex may also help to judge the depth of dissection.<sup>[14]</sup> To standardize this surgical step, preoperative anterior segment optical coherence topography (OCT) is useful to map corneal thickness and calibrate the trephine within 100  $\mu\text{m}$  from the thinnest pachymetric value at the site of trephination.<sup>[15,16]</sup> This allows insertion of the cannula at the appropriate depth, thus limiting the required centripetal advancement to 1–2 mm.<sup>[16]</sup>

The separation plane obtained with pneumatic dissection may differ, with three possible bubble types: type 1 bubble starts at the center, extends centrifugally, and consists of a plane of separation between the stroma and the pre-Descemet's layer; type 2 bubble starts at the periphery, extends centripetally and consists of a plane of separation between the pre-Descemet's layer and the Descemet's membrane; finally, both types can coexist to form a mixed-bubble.<sup>[17,18]</sup> Type 2 bubbles are very fragile due to the floor consisting only of Descemet's membrane, and this results in a high rate of perforation and conversion to PK.<sup>[19]</sup> Moreover, they are associated with

increased risk of postoperative double anterior chamber formation.<sup>[20]</sup> Older age and advanced stages of keratoconus were recently recognized as important predictors of type 2 bubble formation.<sup>[21]</sup>

When pneumatic dissection fails, viscoelastic may be injected into the stromal tunnel used for pneumatic dissection to obtain a viscobubble.<sup>[22,23]</sup> Although retained viscoelastic in the interface may transiently reduce visual acuity in the 1<sup>st</sup> month after surgery, the long-term outcomes are comparable to those obtained with pneumo-dissection.<sup>[23]</sup> In case viscoelastic-assisted dissection also fails, careful layer-by-layer manual dissection may be attempted.<sup>[24]</sup> This technique is associated with increased risk of perforation but can achieve good visual outcomes if the residual stromal bed is <20  $\mu\text{m}$ .<sup>[25]</sup>

Performing large 9 mm DALK offers several advantages including providing superior refractive outcomes with more regular astigmatism<sup>[11,26]</sup> and maximizing removal of the ectatic with lower risk of late recurrence of ectasia.<sup>[27]</sup> Following large trephination, removal of the deep stroma may be limited to the central 6 mm optical zone.<sup>[11]</sup> This reduces the risk of perforation during hand dissection when the bubble does not reach the trephination. Moreover, the crown of deep stroma surrounding the central optical zone protects from inadvertent recipient bed perforation during suturing and confers higher mechanical stability due to the large surface of contact between the host and donor tissue.<sup>[11]</sup> Figure 2 shows a representative case of a patient with keratoconus treated with 9 mm DALK with clearance of a 6-mm optical zone.

Intraoperative macroperforation of the Descemet's membrane may require conversion to PK in 15%–35% of cases.<sup>[28-31]</sup> Occurrence of a type 2 bubble, manual dissection, presence of scarring and surgeon inexperience have been identified as independent risk factors for the need to conversion of intended DALK to PK.<sup>[31]</sup> Should conversion to PK be required, rather than a 9-mm PK, a two-piece mushroom keratoplasty may be performed.<sup>[32]</sup> This technique minimizes the endothelial transplant to the posterior 6 mm lamella while benefitting from the refractive advantages of a large 9 mm anterior lamella with excellent 5-year visual outcomes.<sup>[33]</sup>

## CLINICAL OUTCOMES

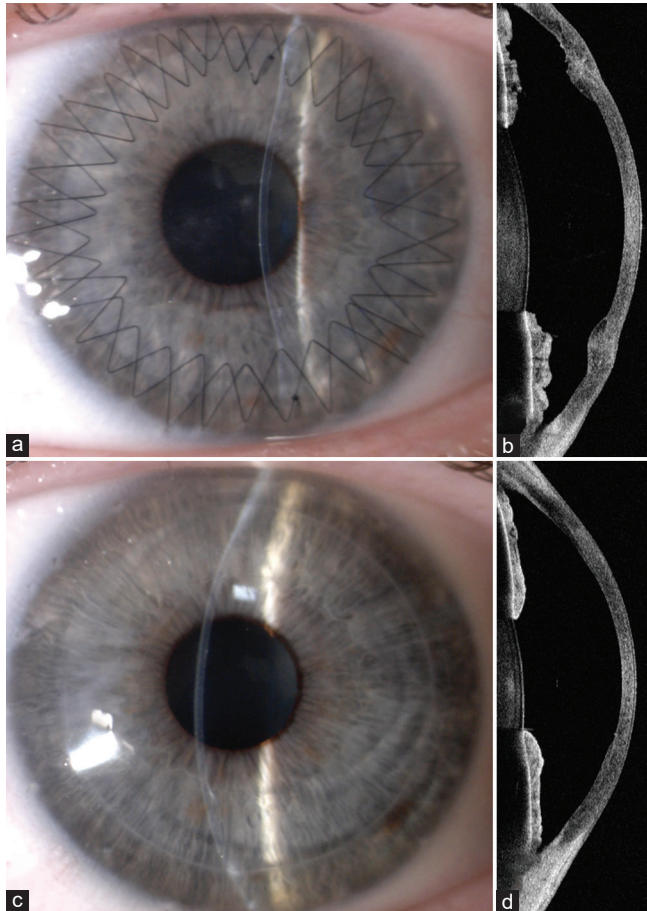
One of the potential concerns of DALK is the presence of a graft-host interface which may cause light scattering and affect vision.<sup>[34]</sup> Studies comparing the visual outcomes after PK and DALK have been inconsistent.<sup>[35-43]</sup> Early reports documented inferior visual outcomes with DALK.<sup>[35-37]</sup> However, advancement in surgical techniques have allowed to obtain a thin residual stroma and a smooth interface with improved vision.<sup>[9,34,42]</sup> Three randomized controlled trials comparing big-bubble DALK and PK have demonstrated similar visual outcomes of the two procedures [Table 1].<sup>[38,39,43]</sup>

Although several studies have shown comparable short-term graft survival between DALK and PK,<sup>[35,40,41,44]</sup> patients with

**Table 1: Randomized controlled trials comparing big bubble deep anterior lamellar keratoplasty and penetrating keratoplasty in patients with keratoconus**

Study	Country	Number eyes	Final BCVA	Corneal astigmatism
Javadi <i>et al.</i> 2011	Iran	42/35	0.18 versus 0.15 logMAR (NS)	3.89 verses 4.36 D (NS)
Cheng <i>et al.</i> 2011	Netherlands	28/28	0.39 versus 0.31 logMAR (NS)	3.57 verses 4.16 (NS)
Söğütü Sari <i>et al.</i> 2012	Turkey	99/75	0.18 versus 0.14 logMAR ( $P=0.09$ )	3.16 verses 3.67 (NS)

BCVA: Best-corrected visual acuity, NS: Not significant



**Figure 2:** Representative case of a patient with keratoconus treated with deep anterior lamellar keratoplasty. 1 month postoperatively with both running sutures still in place (a); anterior segment optical coherence tomography showing the peripheral stromal shoulder surrounding the 6 mm central optical zone (b); 2 years postoperatively after complete suture removal (c); anterior segment optical coherence tomography showing disappearance of the peripheral shoulder due to stromal thinning and remodeling (d)

keratoconus undergoing keratoplasty are usually young, which makes long-term survival necessary. A recent large series demonstrated a significantly higher 10-year survival rate for DALK (94%) compared to PK (72%).<sup>[45]</sup> Moreover, based on the rate of endothelial cell loss, a statistical model was used to predict a median survival of 49 years for DALK versus 17 years for PK.<sup>[46]</sup>

Regarding refractive outcomes, most studies reported no significant differences between DALK and PK.<sup>[35,39-41]</sup> Nevertheless, high astigmatism is common after DALK,

representing an important cause of suboptimal vision despite a clear graft.<sup>[47-49]</sup> Various interventions including photorefractive keratectomy,<sup>[50]</sup> laser *in situ* keratomileusis,<sup>[51]</sup> intrastromal corneal ring segments,<sup>[52]</sup> and manual<sup>[53]</sup> or femtosecond laser-assisted<sup>[54]</sup> relaxing incisions have been used to treat postkeratoplasty astigmatism. Our DALK technique with clearance of the deep stroma limited to the central 6 mm allows deep arcuate blunt relaxing incisions within the stepped graft–host junction with minimal risk of perforation.<sup>[53]</sup> In the presence of a cataract, phacoemulsification with toric intraocular lens implantation can be performed with good visual and refractive outcomes.<sup>[55,56]</sup>

One of the advantages of DALK over PK is the excellent safety profile. In particular, the potentially serious complications that can occur during the open sky surgery (e.g., iris prolapse, choroidal effusions, and expulsive hemorrhage) are avoided with DALK.<sup>[4]</sup> The risk of immune endothelial rejection is also eliminated. Moreover, since topical steroids are usually discontinued earlier after DALK, the incidence of steroid side effects is lower. In agreement with this, a recent meta-analysis demonstrated a reduced risk of cataract and intraocular pressure elevation after DALK compared to PK.<sup>[57]</sup>

Nevertheless, there are some complications that are unique to DALK such as intraoperative perforation of the Descemet's membrane which may lead to endothelial decompensation and/or postoperative detachment of the recipient bed with double anterior chamber formation.<sup>[58]</sup> Our group has previously reported that double anterior chamber formation may also occur without a perforation and is more frequent in scarred corneas and in case of occurrence a type 2 bubble.<sup>[20]</sup> In most cases, this complication requires rebubbling of the anterior chamber to reattach Descemet's membrane.

## KEY ISSUES MOVING FORWARD

Over the past decade, several intraoperative OCT platforms capable of providing the surgeon with extra intraoperative information have become available. Some of the potential applications of intraoperative OCT for DALK are the capacity of assessing the depth reached by the cannula prior to pneumatic dissection,<sup>[13]</sup> the thickness of the residual stromal bed,<sup>[59]</sup> as well as confirming that pneumatic dissection has successfully occurred.<sup>[60]</sup> These information have been shown to be useful in aiding surgical decision-making.<sup>[61]</sup> However, the utility of intraoperative OCT is still limited by the shadowing produced by metal instruments, the motion artifacts, and the latency

between surgeon hand movements and image motion on the screen.

The femtosecond laser is a neodymium glass laser employing ultrashort pulse durations that allows making corneal incisions at the desired depth.<sup>[62]</sup> Several previous studies have described the use of the femtosecond laser during DALK to create lamellar side cuts<sup>[63-66]</sup> and an intrastromal channel for the air injection.<sup>[67-69]</sup> To date, the additional costs associated with this technology do not seem justified by the gains in patient outcomes. In fact, a recent comparative study demonstrated similar results of manual and femtosecond laser-assisted DALK in terms of visual recovery and corneal astigmatism.<sup>[70]</sup> However, a randomized clinical trial comparing manual and femtosecond laser-assisted DALK is currently ongoing (NCT03732599).

Several years after PK for keratoconus, ectasia can re-emerge in the recipient after a period of latency.<sup>[71]</sup> DALK can be performed in these eyes to selectively replace the diseased stroma while leaving the functional endothelium in place.<sup>[72]</sup> We have recently developed a technique for DALK by simple peeling of the PK graft without any need for lamellar dissection. The technique involves 9 mm trephination followed by opening of the stromal component of the old PK wound until a natural plane of separation is found. Stromal peeling can then be performed due to the lack of adherence between the stroma of the PK graft and the underlying layers. This technique results in excellent visual outcomes while minimizing endothelial cell loss.<sup>[73]</sup>

There is an overwhelming imbalance between corneal tissue availability and demand worldwide.<sup>[74]</sup> Since corneas preserved through hypothermic storage and organ culture remain viable only for 2 and 4 weeks, techniques that can extend storage are of great interest.<sup>[75-77]</sup> In the current scenario of COVID-19 pandemic, long-term preservation of unused corneas due to cancellation of elective surgery may be particularly important to avoid tissue wastage.<sup>[78,79]</sup> Silica gel dehydration allows preservation of donor corneal stroma with maintenance of thickness, transparency, and biomechanical properties after rehydration.<sup>[80]</sup> The Veneto Eye Bank Foundation is storing and distributing dehydrated corneas for possible use in DALK. A randomized controlled trial comparing the outcomes of DALK using dehydrated versus standard organ culture stored donor corneas is currently ongoing in our center (NCT04430244).

Alternative solutions to overcome the shortage of donor corneas include the use of biocompatible materials<sup>[81]</sup> and xenograft tissues.<sup>[82]</sup> Although *in vitro* and studies with collagen-based engineered matrices and synthetic polymers have shown promising results,<sup>[83]</sup> clinical data regarding the use of these materials are still lacking. Decellularized porcine corneas have the potential to provide a scaffold for host keratocyte migration without inducing immune rejection due to the elimination of major immunogenic components.<sup>[84]</sup> Three clinical trials evaluating DALK using decellularized

porcine corneas reported improved corneal transparency and visual acuity in patients with fungal<sup>[85,86]</sup> and herpetic keratitis.<sup>[87]</sup> Nevertheless, xenotransplantation is associated with important ethical dilemmas and safety concerns due to the risk of xenogenic rejection and xenozoonosis.<sup>[82]</sup>

## CONCLUSIONS

DALK represents the surgical procedure of choice for advanced keratoconus. The main advantages over PK include the reduced risk of intraoperative complications and the absence of endothelial immune rejections. Big-bubble DALK is still the most popular surgical method. Recent advances in the surgical procedure have allowed standardization of the technique with improved success rates even for inexperienced surgeons.

## Financial support and sponsorship

Nil.

## Conflicts of interest

There are no conflicts of interest.

## REFERENCES

- Gomes JA, Tan D, Rapuano CJ, Belin MW, Ambrósio R Jr., Guell JL, *et al.* Global consensus on keratoconus and ectatic diseases. *Cornea* 2015;34:359-69.
- Garcia-Ferrer FJ, Akpek EK, Amescua G, Farid M, Lin A, Rhee MK, *et al.* Corneal Ectasia Preferred Practice Pattern®. *Ophthalmology* 2019;126:P170-215.
- Parker JS, van Dijk K, Melles GR. Treatment options for advanced keratoconus: A review. *Surv Ophthalmol* 2015;60:459-80.
- Reinhart WJ, Musch DC, Jacobs DS, Lee WB, Kaufman SC, Shtein RM. Deep anterior lamellar keratoplasty as an alternative to penetrating keratoplasty a report by the american academy of ophthalmology. *Ophthalmology* 2011;118:209-18.
- Eye Bank Association of America. 2019 Eye Banking Statistical Report. Washington, DC, USA: Eye Bank Association of America; 2019. Available from: <https://restoresight.org/wpcontent/uploads/2020/04/2019-EBAA-Stat-Report-FINAL.pdf>. [Last accessed on 2021 Apr 15].
- Thanitcul C, Mathews P, Woreta FA, Akpek EK, Varadaraj V, Srikumaran D. Surgeon preference for keratoplasty techniques and barriers to performing deep anterior lamellar keratoplasty. *Cornea* 2021;40:1406-12.
- Myerscough J, Bovone C, Scorcio V, Ricci-Filipovic B, Leon P, Mimouni M, *et al.* Deep trephination allows high rates of successful pneumatic dissection for DALK Independent of surgical experience. *Cornea* 2019;38:645-7.
- Anwar M. Technique in lamellar keratoplasty. *Trans Ophthalmol Soc UK* 1974;94:163-71.
- Anwar M, Teichmann KD. Big-bubble technique to bare Descemet's membrane in anterior lamellar keratoplasty. *J Cataract Refract Surg* 2002;28:398-403.
- Melles GR, Remeijer L, Geerards AJ, Beekhuis WH. A quick surgical technique for deep, anterior lamellar keratoplasty using visco-dissection. *Cornea* 2000;19:427-32.
- Busin M, Leon P, Nahum Y, Scorcio V. Large (9 mm) deep anterior lamellar keratoplasty with clearance of a 6-mm optical zone optimizes outcomes of keratoconus surgery. *Ophthalmology* 2017;124:1072-80.
- Busin M, Mönks T, Al-Nawaiseh I. Different suturing techniques variously affect the regularity of postkeratoplasty astigmatism. *Ophthalmology* 1998;105:1200-5.
- Scorcio V, Busin M, Lucisano A, Beltz J, Carta A, Scorcio G. Anterior segment optical coherence tomography-guided big-bubble technique.

- Ophthalmology 2013;120:471-6.
14. Scorcia V, Lucisano A, Pietropaolo R, Savoca Corona V, Scorcia G, Busin M. Red reflex-guided big-bubble deep anterior lamellar keratoplasty: A simple technique to judge dissection depth. *Cornea* 2015;34:1035-8.
  15. Riss S, Heindl LM, Bachmann BO, Kruse FE, Cursiefen C. Pentacam-based big bubble deep anterior lamellar keratoplasty in patients with keratoconus. *Cornea* 2012;31:627-32.
  16. Busin M, Scorcia V, Leon P, Nahum Y. Outcomes of air injection within 2 mm inside a deep trephination for deep anterior lamellar keratoplasty in eyes with keratoconus. *Am J Ophthalmol* 2016;164:6-13.
  17. Dua HS, Faraj LA, Said DG, Gray T, Lowe J. Human corneal anatomy redefined: A novel pre-Descemet's layer (Dua's layer). *Ophthalmology* 2013;120:1778-85.
  18. Abdelkader A, Kaufman HE. Descemet versus pre-descemet lamellar keratoplasty: Clinical and confocal study. *Cornea* 2011;30:1244-52.
  19. Goweida MB. Intraoperative review of different bubble types formed during pneumodissection (big-bubble) deep anterior lamellar keratoplasty. *Cornea* 2015;34:621-4.
  20. Myerscough J, Bovone C, Mimouni M, Elkadim M, Rimondi E, Busin M. Factors predictive of double anterior chamber formation following deep anterior lamellar keratoplasty. *Am J Ophthalmol* 2019;205:11-6.
  21. Scorcia V, Giannaccare G, Lucisano A, Soda M, Scalzo GC, Myerscough J, *et al.* Predictors of bubble formation and type obtained with pneumatic dissection during deep anterior lamellar keratoplasty in keratoconus. *Am J Ophthalmol* 2020;212:127-33.
  22. Muftuoglu O, Toro P, Hogan RN, Bowman RW, Cavanagh HD, McCulley JP, *et al.* Sarnicola air-visco bubble technique in deep anterior lamellar keratoplasty. *Cornea* 2013;32:527-32.
  23. Scorcia V, De Luca V, Lucisano A, Carnevali A, Carnovale Scalzo G, Bovone C, *et al.* Results of viscobubble deep anterior lamellar keratoplasty after failure of pneumatic dissection. *Br J Ophthalmol* 2018;102:1288-92.
  24. Bhatt UK, Fares U, Rahman I, Said DG, Maharajan SV, Dua HS. Outcomes of deep anterior lamellar keratoplasty following successful and failed 'big bubble'. *Br J Ophthalmol* 2012;96:564-9.
  25. Ardjomand N, Hau S, McAlister JC, Bunce C, Galaretta D, Tuft SJ, *et al.* Quality of vision and graft thickness in deep anterior lamellar and penetrating corneal allografts. *Am J Ophthalmol* 2007;143:228-35.
  26. Seitz B, Langenbacher A, Kühle M, Naumann GO. Impact of graft diameter on corneal power and the regularity of postkeratoplasty astigmatism before and after suture removal. *Ophthalmology* 2003;110:2162-7.
  27. Yoshida J, Murata H, Miyai T, Shirakawa R, Toyono T, Yamagami S, *et al.* Characteristics and risk factors of recurrent keratoconus over the long term after penetrating keratoplasty. *Graefes Arch Clin Exp Ophthalmol* 2018;256:2377-83.
  28. Gadhvi KA, Romano V, Fernández-Vega Cueto L, Aiello F, Day AC, Allan BD. Deep anterior lamellar keratoplasty for keratoconus: Multisurgeon results. *Am J Ophthalmol* 2019;201:54-62.
  29. Donoso R, Díaz C, Villavicencio P. Comparative study of keratoconus between Anwar's deep anterior lamellar keratoplasty versus converted penetrating keratoplasty. *Arch Soc Esp Oftalmol* 2015;90:257-63.
  30. Huang OS, Htoon HM, Chan AM, Tan D, Mehta JS. Incidence and outcomes of intraoperative descemet membrane perforations during deep anterior lamellar keratoplasty. *Am J Ophthalmol* 2019;199:9-18.
  31. Myerscough J, Roberts H, Yu AC, Elkadim M, Bovone C, Busin M. Five-year outcomes of converted mushroom keratoplasty from intended deep anterior lamellar keratoplasty (DALK) mandate 9-mm diameter DALK as the optimal approach to keratoconus. *Am J Ophthalmol* 2020;220:9-18.
  32. Busin M, Madi S, Scorcia V, Santorum P, Nahum Y. A two-piece microkeratome-assisted mushroom keratoplasty improves the outcomes and survival of grafts performed in eyes with diseased stroma and healthy endothelium (An American Ophthalmological Society Thesis). *Trans Am Ophthalmol Soc* 2015;113:T1.
  33. Myerscough J, Friehmann A, Bovone C, Mimouni M, Busin M. Evaluation of the risk factors associated with conversion of intended deep anterior lamellar keratoplasty to penetrating keratoplasty. *Br J Ophthalmol* 2020;104:764-7.
  34. Fontana L, Parente G, Sincich A, Tassinari G. Influence of graft-host interface on the quality of vision after deep anterior lamellar keratoplasty in patients with keratoconus. *Cornea* 2011;30:497-502.
  35. Watson SL, Ramsay A, Dart JK, Bunce C, Craig E. Comparison of deep lamellar keratoplasty and penetrating keratoplasty in patients with keratoconus. *Ophthalmology* 2004;111:1676-82.
  36. Funnell CL, Ball J, Noble BA. Comparative cohort study of the outcomes of deep lamellar keratoplasty and penetrating keratoplasty for keratoconus. *Eye* 2006;20:527-32.
  37. Coster DJ, Lowe MT, Keane MC, Williams KA; Australian Corneal Graft Registry Contributors. A comparison of lamellar and penetrating keratoplasty outcomes: A registry study. *Ophthalmology* 2014;121:979-87.
  38. Söğütü Sari E, Kubaloğlu A, Ünal M, Piñero Llorens D, Koytak A, Ofluoglu AN, *et al.* Penetrating keratoplasty versus deep anterior lamellar keratoplasty: Comparison of optical and visual quality outcomes. *Br J Ophthalmol* 2012;96:1063-7.
  39. Javadi MA, Feizi S, Yazdani S, Mirbabaee F. Deep anterior lamellar keratoplasty versus penetrating keratoplasty for keratoconus: A clinical trial. *Cornea* 2010;29:365-71.
  40. Shimazaki J, Shimmura S, Ishioka M, Tsubota K. Randomized clinical trial of deep lamellar keratoplasty vs. penetrating keratoplasty. *Am J Ophthalmol* 2002;134:159-65.
  41. Han DC, Mehta JS, Por YM, Htoon HM, Tan DT. Comparison of outcomes of lamellar keratoplasty and penetrating keratoplasty in keratoconus. *Am J Ophthalmol* 2009;148:744-51.e1.
  42. Feizi S, Javadi MA, Jamali H, Mirbabaee F. Deep anterior lamellar keratoplasty in patients with keratoconus: Big-bubble technique. *Cornea* 2010;29:177-82.
  43. Cheng YY, Visser N, Schouten JS, Wijdh RJ, Pels E, van Cleynenbreugel H, *et al.* Endothelial cell loss and visual outcome of deep anterior lamellar keratoplasty versus penetrating keratoplasty: A randomized multicenter clinical trial. *Ophthalmology* 2011;118:302-9.
  44. Jones MN, Armitage WJ, Ayliffe W, Larkin DF, Kaye SB; NHSBT Ocular Tissue Advisory Group and Contributing Ophthalmologists (OTAG Audit Study 5). Penetrating and deep anterior lamellar keratoplasty for keratoconus: A comparison of graft outcomes in the United Kingdom. *Invest Ophthalmol Vis Sci* 2009;50:5625-9.
  45. Arundhati A, Chew MC, Lim L, Mehta JS, Lang SS, Htoon HM, *et al.* Comparative study of long-term graft survival between penetrating keratoplasty and deep anterior lamellar keratoplasty. *Am J Ophthalmol* 2021;224:207-16.
  46. Borderie VM, Sandali O, Bullet J, Gaujoux T, Touzeau O, Laroche L. Long-term results of deep anterior lamellar versus penetrating keratoplasty. *Ophthalmology* 2012;119:249-55.
  47. Elkadim M, Myerscough J, Bovone C, Busin M. Astigmatism orientation after deep anterior lamellar keratoplasty for keratoconus and its correlation with preoperative peripheral corneal astigmatism. *Cornea* 2020;39:192-5.
  48. Feizi S, Zare M. Current approaches for management of postpenetrating keratoplasty astigmatism. *J Ophthalmol* 2011;2011:708736.
  49. Romano V, Iovieno A, Parente G, Soldani AM, Fontana L. Long-term clinical outcomes of deep anterior lamellar keratoplasty in patients with keratoconus. *Am J Ophthalmol* 2015;159:505-11.
  50. Bilgihan K, Ozdek SC, Akata F, Hasanreisoglu B. Photorefractive keratectomy for post-penetrating keratoplasty myopia and astigmatism. *J Cataract Refract Surg* 2000;26:1590-5.
  51. Kovoov TA, Mohamed E, Cavanagh HD, Bowman RW. Outcomes of LASIK and PRK in previous penetrating corneal transplant recipients. *Eye Contact Lens* 2009;35:242-5.
  52. Arantes JC, Coscarelli S, Ferrara P, Araújo LP, Ávila M, Torquetti L. Intrastromal corneal ring segments for astigmatism correction after deep anterior lamellar keratoplasty. *J Ophthalmol* 2017;2017:8689017.
  53. Elkadim M, Myerscough J, Bovone C, Busin M. A novel blunt dissection technique to treat modified deep anterior lamellar keratoplasty (DALK)-associated high astigmatism. *Eye (Lond)* 2020;34:1432-7.
  54. anNakhli F, Khattak A. Vector analysis of femtosecond laser-assisted astigmatic keratotomies after deep anterior lamellar keratoplasty and penetrating keratoplasty. *Int Ophthalmol* 2019;39:189-98.

55. Wade M, Steinert RF, Garg S, Farid M, Gaster R. Results of toric intraocular lenses for post-penetrating keratoplasty astigmatism. *Ophthalmology* 2014;121:771-7.
56. Lockington D, Wang EF, Patel DV, Moore SP, McGhee CN. Effectiveness of cataract phacoemulsification with toric intraocular lenses in addressing astigmatism after keratoplasty. *J Cataract Refract Surg* 2014;40:2044-9.
57. Liu H, Chen Y, Wang P, Li B, Wang W, Su Y, *et al.* Efficacy and safety of deep anterior lamellar keratoplasty vs. penetrating keratoplasty for keratoconus: A meta-analysis. *PLoS One* 2015;10:e0113332.
58. Den S, Shimmura S, Tsubota K, Shimazaki J. Impact of the descemet membrane perforation on surgical outcomes after deep lamellar keratoplasty. *Am J Ophthalmol* 2007;143:750-4.
59. De Benito-Llopis L, Mehta JS, Angunawela RI, Ang M, Tan DT. Intraoperative anterior segment optical coherence tomography: A novel assessment tool during deep anterior lamellar keratoplasty. *Am J Ophthalmol* 2014;157:334-41.e3.
60. Myerscough J, Friehmann A, Busin M, Goor D. Successful visualization of a big bubble during deep anterior lamellar keratoplasty using intraoperative OCT. *Ophthalmology* 2019;126:1062.
61. Au J, Goshe J, Dupps WJ Jr., Srivastava SK, Ehlers JP. Intraoperative optical coherence tomography for enhanced depth visualization in deep anterior lamellar keratoplasty from the PIONEER study. *Cornea* 2015;34:1039-43.
62. Han SB, Liu YC, Mohamed-Noriega K, Mehta JS. Application of femtosecond laser in anterior segment surgery. *J Ophthalmol* 2020;2020:8263408.
63. Price FW Jr., Price MO, Grandin JC, Kwon R. Deep anterior lamellar keratoplasty with femtosecond-laser zigzag incisions. *J Cataract Refract Surg* 2009;35:804-8.
64. Farid M, Steinert RF. Deep anterior lamellar keratoplasty performed with the femtosecond laser zigzag incision for the treatment of stromal corneal pathology and ectatic disease. *J Cataract Refract Surg* 2009;35:809-13.
65. Li S, Wang T, Bian J, Wang F, Han S, Shi W. Precisely controlled side cut in femtosecond laser-assisted deep lamellar keratoplasty for advanced keratoconus. *Cornea* 2016;35:1289-94.
66. Kopani KR, Page MA, Holiman J, Parodi A, Iliakis B, Chamberlain W. Femtosecond laser-assisted keratoplasty: Full and partial-thickness cut wound strength and endothelial cell loss across a variety of wound patterns. *Br J Ophthalmol* 2014;98:894-9.
67. Liu YC, Wittwer VV, Yusoff NZ, Lwin CN, Seah XY, Mehta JS, *et al.* Intraoperative optical coherence tomography-guided femtosecond laser-assisted deep anterior lamellar keratoplasty. *Cornea* 2019;38:648-53.
68. Lucisano A, Giannaccare G, Pellegrini M, Bernabei F, Yu AC, Carnevali A, *et al.* Preliminary results of a novel standardized technique of femtosecond laser-assisted deep anterior lamellar keratoplasty for keratoconus. *J Ophthalmol* 2020;2020:5496162.
69. Pedrotti E, Bonacci E, De Rossi A, Bonetto J, Chiarego C, Fasolo A, *et al.* Femtosecond laser-assisted big-bubble deep anterior lamellar keratoplasty. *Clin Ophthalmol* 2021;15:645-50.
70. Salouti R, Zamani M, Ghoreyshi M, Dapena I, Melles GR, Nowroozzadeh MH. Comparison between manual trephination versus femtosecond laser-assisted deep anterior lamellar keratoplasty for keratoconus. *Br J Ophthalmol* 2019;103:1716-23.
71. Bergmanson JP, Goosey JD, Patel CK, Mathew JH. Recurrence or re-emergence of keratoconus – What is the evidence telling us? Literature review and two case reports. *Ocul Surf* 2014;12:267-72.
72. Lake D, Hamada S, Khan S, Daya SM. Deep anterior lamellar keratoplasty over penetrating keratoplasty for host rim thinning and ectasia. *Cornea* 2009;28:489-92.
73. Bovone C, Nahum Y, Scoria V, Giannaccare G, Spina R, Myerscough J, *et al.* Stromal peeling for deep anterior lamellar keratoplasty in post-penetrating keratoplasty eyes. *Br J Ophthalmol* 2020;bjophthalmol-2020-316653.
74. Gain P, Jullienne R, He Z, Aldossary M, Acquart S, Cognasse F, *et al.* Global survey of corneal transplantation and eye banking. *JAMA Ophthalmol* 2016;134:167-73.
75. Busin M, Halliday BL, Arffa RC, McDonald MB, Kaufman HE. Precarved lyophilized tissue for lamellar keratoplasty in recurrent pterygium. *Am J Ophthalmol* 1986;102:222-7.
76. Arffa RC, Busin M, Barron BA, McDonald MB, Kaufman HE. Epikeratophakia with commercially prepared tissue for the correction of aphakia in adults. *Arch Ophthalmol* 1986;104:1467-72.
77. Chaurasia S, Das S, Roy A. A review of long term corneal preservation techniques: Relevance and renewed interests in the COVID-19 era. *Indian J Ophthalmol* 2020;68:1357-63.
78. Busin M, Yu AC, Ponzin D. Coping with COVID-19: An Italian perspective on corneal surgery and eye banking in the time of a pandemic and beyond. *Ophthalmology* 2020;127:e68-9.
79. Parekh M, Ferrari S, Romano V, Myerscough J, Jones G, Griffoni C, *et al.* Impact of COVID-19 on corneal donation and distribution. *Eur J Ophthalmol* 2022;32:NP269-NP270.
80. Romano V, Levis HJ, Gallon P, Lacey R, Borroni D, Ponzin D, *et al.* Biobanking of dehydrated human donor corneal stroma to increase the supply of anterior lamellar grafts. *Cornea* 2019;38:480-4.
81. Doillon CJ, Watsky MA, Hakim M, Wang J, Munger R, Laycock N, *et al.* A collagen-based scaffold for a tissue engineered human cornea: Physical and physiological properties. *Int J Artif Organs* 2003;26:764-73.
82. Yoon CH, Choi HJ, Kim MK. Corneal xenotransplantation: Where are we standing? *Prog Retin Eye Res* 2021;80:100876.
83. Matthyssen S, Van den Bogerd B, Dhubbhghail SN, Koppen C, Zakaria N. Corneal regeneration: A review of stromal replacements. *Acta Biomater* 2018;69:31-41.
84. Hashimoto Y, Funamoto S, Sasaki S, Negishi J, Honda T, Hattori S, *et al.* Corneal regeneration by deep anterior lamellar keratoplasty (DALK) using decellularized corneal matrix. *PLoS One* 2015;10:e0131989.
85. Zhang MC, Liu X, Jin Y, Jiang DL, Wei XS, Xie HT. Lamellar keratoplasty treatment of fungal corneal ulcers with acellular porcine corneal stroma. *Am J Transplant* 2015;15:1068-75.
86. Zheng Q, Zhang Y, Ren Y, Zhao Z, Hua S, Li J, *et al.* Deep anterior lamellar keratoplasty with cross-linked acellular porcine corneal stroma to manage fungal keratitis. *Xenotransplantation* 2021;28:e12655.
87. Zheng J, Huang X, Zhang Y, Wang Y, Qin Q, Lin L, *et al.* Short-term results of acellular porcine corneal stroma keratoplasty for herpes simplex keratitis. *Xenotransplantation* 2019;26:e12509.