

Accepted Manuscript

Pre-loaded tissues for Descemet Membrane Endothelial Keratoplasty

Mohit Parekh, Alessandro Ruzza, Stefano Ferrari, Massimo Busin, Diego Ponzin

PII: S0002-9394(16)30152-0

DOI: [10.1016/j.ajo.2016.03.048](https://doi.org/10.1016/j.ajo.2016.03.048)

Reference: AJOPHT 9702

To appear in: *American Journal of Ophthalmology*

Received Date: 24 November 2015

Revised Date: 29 March 2016

Accepted Date: 31 March 2016

Please cite this article as: Parekh M, Ruzza A, Ferrari S, Busin M, Ponzin D, Pre-loaded tissues for Descemet Membrane Endothelial Keratoplasty, *American Journal of Ophthalmology* (2016), doi: 10.1016/j.ajo.2016.03.048.

This is a PDF file of an unedited manuscript that has been accepted for publication. As a service to our customers we are providing this early version of the manuscript. The manuscript will undergo copyediting, typesetting, and review of the resulting proof before it is published in its final form. Please note that during the production process errors may be discovered which could affect the content, and all legal disclaimers that apply to the journal pertain.



1 **Abstract**

2 **Introduction:** To determine the feasibility of pre-loading endothelial tissues for
3 Descemet Membrane Endothelial Keratoplasty (DMEK).

4 **Design:** Laboratory investigation.

5 **Methods:**

6 **Settings:** Institutional

7 **Participants:** Twenty human donor corneas unsuitable for transplantation with
8 endothelial cell density in a range of 1600-2700 cells/mm².

9 **Intervention:** The endothelium was punched, stripped (8.5 mm diameter) and
10 manually tri-folded with the endothelial side inwards. The excised membranes were
11 gently moved in a 2.2 intra ocular lens (IOL) cartridge and pulled further in the funnel
12 using 25G endgrasping forceps. The cartridge was filled with transport media (TM)
13 (sealed at its funnel and back entrance with a stopper) and the tissue was preserved
14 for 4 days at room temperature (RT) in the bottles containing TM.

15 **Main outcome measures:** Success rate of preparation, processing time, endothelial
16 cell loss (ECL) and active metabolism.

17 **Results:** The tissues were peeled and loaded successfully in all cases. Average
18 stripping and loading time was 20 and 4.5 minutes respectively. ECL after
19 preservation was 4.35% with 3.55(±5.89)% mortality and 7.80(±14.12)% uncovered
20 areas. 0.55(±0.26) mg/mL of glucose was consumed by the cells showing active
21 metabolism.

22 **Conclusions:** Tri-folded (endothelium in) DMEK grafts can be pre-loaded using TM
23 in an IOL cartridge and stored up to 4 days with limited endothelial damage. Direct
24 injection of TM should be avoided due to the presence of bovine serum, but the
25 tissue can be washed using balanced salt solution (BSS) and gently injected.
26 Alternatively, the graft can be easily delivered using a bimanual pull-through
27 technique. Pre-loading DMEK grafts will simplify the surgery with reproducibility,
28 reduced surgical time and tissue wastage, costs and logistic requirements.
29

30

Pre-loaded tissues for Descemet Membrane Endothelial Keratoplasty**Authors**

Mohit Parekh¹, Alessandro Ruzza¹, Stefano Ferrari¹, Massimo Busin² and Diego Ponzin¹

Affiliations

¹International Center for Ocular Physiopathology, Fondazione Banca Degli Occhi Del Veneto Onlus, Venice, Italy

²Department of Ophthalmology, Villa Igea Hospital, Forli, Italy

Address of Correspondence

Mohit Parekh

International Center for Ocular Physiopathology,
Fondazione Banca Degli Occhi Del Veneto Onlus,
Via Paccagnella 11, Padiglione Rama,
Zelarino, 30174, Venice, Italy

Tel: +39 0419656473

Fax: +39 0419656471

Email: mohit.parekh@fbov.it

Short title

Pre-loaded Descemet Membrane Endothelial Keratoplasty

Introduction

Endothelial Keratoplasty (EK) is a selective transplantation technique and an effective alternative to Penetrating Keratoplasty (PK) for the management of corneal endothelial failure. Descemet Membrane Endothelial Keratoplasty (DMEK) is a sub-type of EK which foresees the transplantation of Descemet membrane and endothelium exclusively [1-4] and offers an extremely fast recovery of vision often at the 20/20 level.

Similar to other lamellar keratoplasty procedures, DMEK is gaining popularity and eye banks are confronted with new requirements from corneal surgeons. Recently, they have started the preparation and transportation of pre-cut donor tissues with a desired diameter for Descemet Stripping Automated Endothelial Keratoplasty (DSAEK), Ultra-Thin DSAEK (UT-DSAEK) and pre-stripped tissues for DMEK [5-7].

As this reduces the efforts, time and cost in the surgical theatre, the popularity of pre-cut/pre-stripped tissues is increasing rapidly. Moreover, it allows validation of the tissue to be grafted, a quality control that cannot be done in the surgical theater, when the surgeons prepare the tissue themselves. The Veneto Eye Bank Foundation has now started providing pre-loaded tissues, a step further to pre-cut tissues for DSAEK and UT-DSAEK surgeries [8]. This further reduces the time and efforts in the surgical theater, increases the efficiency of DSAEK surgery and allows the use of a validated tissue. DMEK tissues can be pre-stripped [7] or pre-bubbled [9] at the eye bank and shipped to the operating room with the full cornea as a base support. Instead, if the DMEK tissue is stored without corneal support, it rolls with the endothelium facing outwards in contact with the solid walls of the cartridge, thus possibly being negatively affected by the storage process. We have investigated the possibility of preserving DMEK tissue rolled with the endothelium inwards to avoid any damage caused by the contact with the cartridge wall and providing a ready-to-use tissue to the surgeons for direct transplantation. This paper is a proof of concept for a pre-loaded DMEK and the clinical relevance still needs to be tested.

Materials and Methods

Ethical statement

Twenty human donor corneal tissues were collected from The Veneto Eye Bank Foundation, Venice, Italy to be used for research with a written consent from the donor's next of kin.

Donor characteristics

The average age of the donors was 67.6(\pm 7.47) years with Male:Female donor ratio of 14:6. The average post-mortem time of 15.99(\pm 5.56) hours and preservation time of 14.5(\pm 4.83) days in tissue culture medium [TCM] were recorded followed by 4.6(\pm 6.27) days in transport medium [TM]. TCM was composed of 2% new-born calf serum with MEM-Earle as a base medium along with 25 mM Hepes buffer, 26 mM sodium bicarbonate, 1 mM pyruvate, 2 mM glutamine, 250 ng/mL amphotericin B, 100 IU/mL penicillin G and 100 mg/mL streptomycin. TM was composed of TCM+6% Dextran T500. TCM and TM were prepared in-house (FBOV, Mestre, Italy) with full regulatory compliance. The endothelial cells were determined using a hypotonic sucrose solution and the mortality was estimated using Trypan blue staining. The endothelial cells were checked using an inverted microscope (Zeiss, Jena,

Germany). The average endothelial cell density recorded was 2070(\pm 374.31) cells/mm² with no initial mortality or uncovered areas.

Stripping method

The [n=20] corneas were centered on a punch base of the suction. Vacuum was created using a syringe and the cornea was secured on the base. A 9.5 mm [Moria, Antony, France] trephine was used to make a superficial cut using gentle tapping method. The endothelium was stained with Trypan blue for about 20 seconds to determine the area of the cut. Excess peripheral membrane was removed using 120mm acute forceps (e.janach, Como, Italy). The endothelium was kept moist during the entire procedure using TM to create a film of fluid on the top of the corneal-scleral ring. The membrane was slightly lifted using a cleavage hook and the procedure was carried on along the entire circumference of the cut to ensure limited tearing of the very fragile DMEK tissue. The peripheral membrane was stripped with a longitudinal movement using a 3 quadrant method, ensuring no torsions were generated during this phase to limit the mortality. Once the tissue was stripped completely, it was re-stored on the corneal stroma.

Loading method

The pre-stripped membrane (9.5 mm) was trephined again with an 8.5 mm punch [Moria, Antony, France] and the excess periphery was excised maintaining the endothelial side facing the air. The membrane was folded manually from two ends using an acute forceps, touching the Descemet side to avoid as much endothelial damage as possible (figure 1 top left) [Supplementary video 1]. A small drop of liquid was added on the membrane to keep the tissue moist during the entire procedure. The purpose of the drop was only to support the moisture and not the opening of the membrane as this may change the orientation. The membrane was gently moved from the tissue base to a 2.2 IOL (Intra Ocular Lens) cartridge (Viscoject, Wolfhalden, Switzerland) preservation chamber (figure 1 top middle). This step can be performed either using a contact lens as a scaffold as showed by Busin et al. [10] or directly from the cornea to the cartridge maintaining the architecture of the membrane. The membrane was pulled inside the funnel using a Grieshaber Revolution DSP 25 Ga + endgrasping forceps (Alcon, Texas, USA) from the funnel opening (figure 1 bottom left). A small amount of TM (<0.5 mL) was used to fill the funnel of the IOL cartridge for preservation of the DMEK membrane from its rear end (figure 1 bottom middle). The IOL cartridge was sealed with a rubber plug both at the funnel and the rear exit [Supplementary video 2]. The entire unit was sealed with an in-house modified plastic clamp. The entire system was preserved in a sterile flask with TM for 4 days at room temperature (figure 1 right). The plug was removed and the tissues were released out from the funnel pore using the microincision forceps and analyzed post preservation.

Endothelial cell survival

The membranes were stained with trypan blue for 20 seconds and washed with PBS. The endothelium was checked using an inverted microscope [Primovert; Zeiss, Jena, Germany] for endothelial cell survival and tissue integrity. The cells were counted using a 10X10 eye piece reticule and the images were captured at 100X magnification.

Glucose uptake

Glucose uptake was determined in the preservation media in which the tissues were preserved for 4 days. The metabolic activity of the endothelial cells was checked using this technique. D-Glucose HK kit (Megazyme International Ireland Ltd, Bray Business Park, Bray, Co. Wicklow, Ireland) was used for quantitative analysis post preservation [8].

Results

Endothelial cells survive after preserving pre-loaded DMEK grafts [n=20]

All the final twenty experimental tissues were stripped and loaded successfully (100% cases). Average stripping and loading time was recorded at 20 and 4.5 minutes respectively. Average endothelial cell density after stripping the tissues was $2070(\pm 374.31)$ cells/mm², which did not differ from the initial count. However, the mortality increased to $5.08(\pm 12.61)\%$. There were visible uncovered areas in the tissues post stripping with an average of $0.73(\pm 1.89)\%$ [calculated manually at a magnification of 100x using a 10 X 10 calibrated reticule mounted in the ocular of the microscope – fixed frame technique] (figure 2 left). Average endothelial cell density post preservation was found to be $1980(\pm 278.34)$ cells/mm² with mortality of $3.55(\pm 5.79)\%$ and $7.8(\pm 14.13)\%$ uncovered areas (area on the tissue without endothelial cells) (Figure 2 middle). Endothelial cell loss (ECL) after preservation was 4.35%. Localized uncovered areas were observed in some parts (Figure 2 middle). Apart from the areas where the endgrasping forceps get in contact with the endothelium for pulling the graft inside the funnel (approximately 0.25-0.5 mm²), other areas of the periphery did not show any cell loss or mortality (figure 2 right). It was also observed that if the tissues are kept moist and folded just to orient the graft then minimal to no mortality can be observed.

During the learning curve, mortality was observed on the folds (figure 3 left). The tissues must be handled gently as if grabbed rigorously using endgrasping forceps, the tissues may tear near the periphery (figure 3 middle). Less uncovered areas were recorded after learning the method using more than twenty corneas (figure 3 right). The tissues should be handled gently to optimize results and the technique requires a learning curve.

Pre-loaded grafts show active metabolism [n=20]

The average glucose uptake by the endothelial cells in the preservation chamber for 4 days at room temperature was $0.55(\pm 0.26)$ mg/mL (Minimum – 0.10 mg/mL and Maximum – 0.882 mg/mL) which is half the total amount of glucose present in the media (1mg/mL). Glucose uptake was higher as compared to the previously shown uptake from pre-loaded DSAEK membrane [8].

Discussion

DMEK requires high surgical skills both for the preparation and transplantation of the tissues. If eye banks can provide ready and validated DMEK tissues, surgeons do not have to engage with this time consuming phase of the procedure, thus saving time, eliminating possible tissue waste and facilitating surgery.

It has already been determined that the cell loss in dextran based media is higher than it has been found without dextran for PK [11-12]. However, we have observed that corneal-scleral rims obtained from the dextran based medium allow excising a regular DMEK graft with minimal endothelial cell loss. Dextran based medium helps to keep the endothelial cells adhered to the DM and maintains the flexibility required

for the tissues for unfolding it (unpublished data). Moreover, we have also obtained 100% successful peeling cases when the tissues were obtained from TM as compared to 76% successful peeling cases when the tissues were collected from TCM. Therefore we selected an inclusion criteria of the tissues prepared and preserved in dextran based medium.

Mortality was observed near the folds or when the tissues were treated rigorously by making the folds tighter and stronger to maintain the orientation, which was later realized as not so important. A small drop of liquid that keeps the tissue moist and without any tight folds can be served as the best option. Majority of the uncovered areas were found near the periphery of the tissue where the endgrasping forceps touch the endothelium to pull the graft inside the funnel. In one of the cases, a peripheral tear was generated with high mortality and uncovered area, whereas, in other case, only uncovered areas were observed on the peripheral tissue without any mortality. If the graft is gently pulled in with minimal manipulations, then the forceps generated uncovered areas and mortality decreases to the level of acceptance for grafting as described by Busin et al [10].

Most of the cases showed the correct orientation and the architecture of the graft same as before preservation however, one case during the learning curve showed an 'S' shaped fold where half of the corneal endothelium was exposed to the cartridge (figure 4 left) and the cells were completely detached from that area (figure 4 right) showing once again the importance of avoiding possible contact between endothelium and cartridge wall. A contact lens could be employed or the graft should be pulled gently inside the preservation chamber and the funnel area [10]. It was also observed that due to the thickness of the IOL cartridge (2.2 pore opening), the tissue does not get a chance to open up and unfold itself to endothelium out. The tissues open up to its maximum with endothelium-in and stay in the same fashion without any further opening. The 'S' shape was observed due to manual error while pulling the tissue inside the cartridge. If the tissue is properly inserted then they stay without any further damage or de-orientation.

There are two transplantation strategies for DMEK, a) the injection method which is widely used around the world due to its simplicity and natural rolling of the graft and b) pull-through technique that is contemporarily used for DSAEK surgery, but has been also introduced recently for DMEK [10]. Due to the presence of serum in the preservation medium, it is not advisable to inject the tissue directly in the recipient eye as the medium will be injected as well. Therefore, a pull through technique should be preferred for a successful surgery. The preserved tissue can be released out of the cartridge using a microincision forceps and inserted into the recipient eye using bimanual pull-through technique. As the endothelium is flapped-in, it reduces a direct contact or friction of the endothelial cells with the wall of the cartridge.

The DMEK membrane in its natural tendency rolls with the endothelium-out when in contact with liquid and therefore if they are manually flapped-in (forced against the nature), once inside the eye, they open up easily and try to retain its natural formation inside the recipient's eye. Therefore, this may serve as an additional advantage over the traditional DMEK surgical technique. Moreover, the tissue preparation and loading time (approximately 25 minutes) can be saved in the surgery if the tissue is pre-loaded in an eye bank. Simultaneously, if the injection method is

supposed to be used then the TM from the funnel must be removed out using a cannula and filled with balanced salt solution (BSS) and the tissue can be injected in the eye. However, for both methods, the tissue can be stained inside the funnel using trypan blue for better visibility during the surgery [Supplementary video 2]. We have also observed that the tissue opens easily with either methods but only when the endothelium is flapped inwards. The tissue can be easily washed using BSS to aspirate the TM out however this procedure should be carried out gently to avoid any de-orientation of the graft inside the funnel. Alternatively, the TM can be removed using a 1 mL syringe and the tissue can be washed with BSS. We have found that using the BSS directly to remove the TM has been the best option as it avoids the unscrolling and de-orienting the graft. Removing the TM may suck the tissue and grab it on the needle of the syringe making it difficult to keep the orientation with endo-in.

It has already been proposed that the DMEK donor tissues preserved up to 2 days at 4°C does not show any significant endothelial cell loss difference [13]. However, the results described in this paper suggest that the DMEK tissues can be preserved in the IOL cartridges filled with transport media for up to 4 days at RT without a high cell loss and active metabolism. The surgical outcome further needs to be evaluated. The tissues used in this study were obtained from relatively older donor corneas and therefore they did not unscroll to its natural tendency of endo-out. However, the tissues should be preserved around 2 mm away from the funnel pore to keep the tissue as tight as possible and avoid any de-orientation of the graft. DM-endothelium grafts for transplantation in DMEK procedures can be prepared from TM and preserved in TM for the best outcome. The tissues should be transplanted using a pull-through technique to reduce the possibility of injecting the serum inside the recipient eye, although an injection method could also be used if the tissue is washed inside the funnel. Injection method will reduce the chances of peripheral tears and uncovered areas. Pre-loading DMEK membrane will reduce surgical time, tissue wastage and costs. In addition, it will provide a validated tissue for transplantation. The study presented here is a 'proof of concept' and has not undergone any clinical evaluation therefore the complications need to be identified before undergoing any surgery.

Acknowledgements

Funding/Support: This study was supported by the Eye Bank Association of America (EBAA) 2014 Richard Lindstrom Research Grant and a grant from Società Oftalmologica Italiana (SOI) to Dr. Ponzin.

Financial Disclosures: MB gets travel reimbursements from Moria. The authors from FBOV are employed by the eye bank and have potential financial conflicts.

Other Acknowledgements: The authors thank Mrs. Jaini Parekh for the illustration of figure 4 left.

ACCEPTED MANUSCRIPT

References

1. Price FW Jr, Price MO. Descemet's stripping with endothelial keratoplasty in 50 eyes: a refractive neutral corneal transplant. *J Refract Surg* 2005;21(4):339–345.
2. Price FW Jr, Price MO. Descemet's stripping with endothelial keratoplasty in 200 eyes: early challenges and techniques to enhance donor adherence. *J Cataract Refract Surg* 2006;32(3):411–418.
3. Melles GR, Ong TS, Ververs B, van der Wees J. Descemet membrane endothelial keratoplasty (DMEK). *Cornea* 2006; 25(8):987–990.
4. Melles GR. Posterior lamellar keratoplasty: DLEK to DSEK to DMEK. *Cornea* 2006;25(8):879–881.
5. Terry MA, Straiko MD, Veldman PB, et al. Standardized DMEK Technique: Reducing Complications Using Prestripped Tissue, Novel Glass Injector, and Sulfur Hexafluoride (SF6) Gas. *Cornea* 2015;34(8):845-852.
6. Deng SX, Sanchez PJ, Chen L. Clinical outcomes of Descemet membrane endothelial keratoplasty using eye bank-prepared tissues. *Am J Ophthalmol* 2015;159(3):590-596.
7. Kobayashi A, Murata N, Yokogawa H, et al. Evaluation of internationally shipped prestripped donor tissue for descemet membrane endothelial keratoplasty by vital dye staining. *Cornea* 2015;34(2):225-227.
8. Ruzza A, Parekh M, Ferrari S, et al. Preloaded donor corneal membrane in a new validated 3D printed smart storage glide for Descemet stripping automated endothelial keratoplasty. *Br J Ophthalmol* 2015;99(10):1388-1395.
9. Parekh M, Ferrari S and Ponzin D. Eye Banking: An Overview. In: Parekh M, Ferrari S and Ponzin D, editors. *Eye Banking - Changing Face of Corneal Transplantation*. New York: Nova Science Publishers, 2015:1-18.
10. Busin M, Leon P, Scordia V, Ponzin D. Contact Lens-Assisted Pull-Through Technique for Delivery of Tri-Folded (Endothelium in) DMEK Grafts Minimizes Surgical Time and Cell Loss. *Ophthalmology* 2016;123(3):476-483.
11. Borderie VM Baudrimont M Lopez M Carvajal S Laroche L. Evaluation of the deswelling period in dextran-containing medium after corneal organ culture. *Cornea* 1997;16(2):215–223.
12. Thuret G, Manissolle C, Campos-Guyotat L, Guyotat D, Gain P. Animal compound-free medium and poloxamer for human corneal organ culture and deswelling. *Invest Ophthalmol Vis Sci* 2005;46(3):816–822.
13. Feng MT, Burkhart ZN, Price FW Jr, Price MO. Effect of donor preparation-to-use times on Descemet membrane endothelial keratoplasty outcomes. *Cornea* 2013;32(8):1080-1082.

Figure Legends

Figure 1: Pre-loaded Descemet Membrane Endothelial Keratoplasty preparation technique.

Top left- using acute forceps on the Descemet side, the tissue is tri-folded with endothelium flapped in position with a small drop of tissue culture medium supplemented with dextran to keep the tissue moist. The graft should be folded half-way through from both the ends to make a tri-fold maintaining the correct orientation;
top middle- the graft can be directly transferred from the corneal base to the intra ocular lens cartridge preservation chamber using acute forceps which should only touch the periphery of the graft;
bottom left- using an endgrasping forceps, the graft is gently pulled inside the funnel (pre-filled with transport media) [the over-flaps should be visible on the top end and the Descemet Membrane should be touching the cartridge], the graft is secured in the funnel area;
bottom middle- the cartridge is filled with the transport media from the back and closed using rubber stopper to preserve the membrane and its orientation inside the funnel;
right- the funnel is closed using a sterile rubber stopper and the graft is preserved using transport media in a 2.2 intra ocular lens cartridge fixed using two rubber stoppers at each end and a clamp on the top, the entire unit is preserved in 50 mL transport media to avoid any leakage and shipped.

Figure 2: Determination of the endothelial cell density, mortality and uncovered areas of the preserved grafts at 100x magnification.

left- the endothelial status post stripping with minimal mortality and uncovered areas,
middle- small uncovered areas as marked in the figures and
right- peripheral endothelium without any mortality or uncovered areas (this peripheral area is different than the one where the endgrasping forceps touch the endothelium)

Figure 3: Determination of the endothelial cell density, mortality and uncovered areas of the preserved grafts at 100X magnification during the learning curve.

left- uncovered areas and trypan blue stained cells were observed if the tissues are rigorously handled while transferring them on the intra ocular lens (IOL) cartridge from the cornea base and preserved for 4 days at room temperature in transport media;
middle- a tear was observed in the periphery if the microincision forceps are touched tightly and when the tissue is not moved in the funnel gently;
right- relatively lesser mortality and uncovered areas were observed with increased learning techniques.

Figure 4: De-oriented graft showing 'S' shape orientation.


Left- graphical representation of the tissue showing 'S' shape orientation with one flap exposed to the wall of the cartridge and;
right- the tissue showing >90% loss of the endothelial cells (uncovered areas) on the exposed flap.

Video Legends

Supplementary video 1: The video shows the tri-folding technique with the endothelium flapped inwards.

Supplementary video 2: The video shows pre-loading of the Descemet Membrane Endothelial Keratoplasty graft inside an intra ocular lens cartridge.

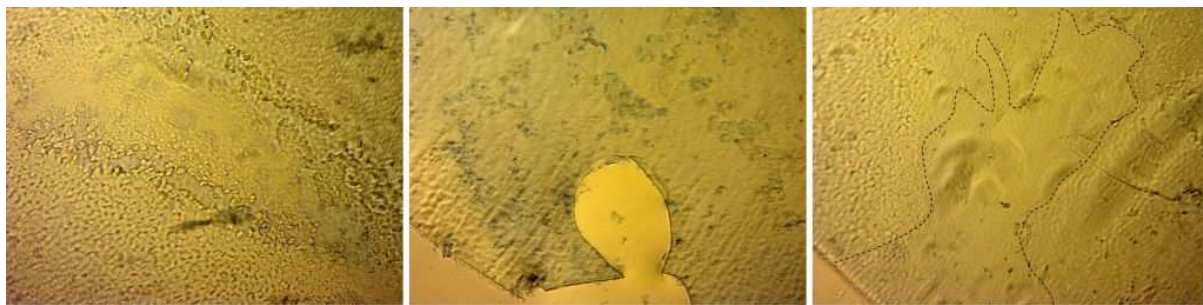ACCEPTED MANUSCRIPT



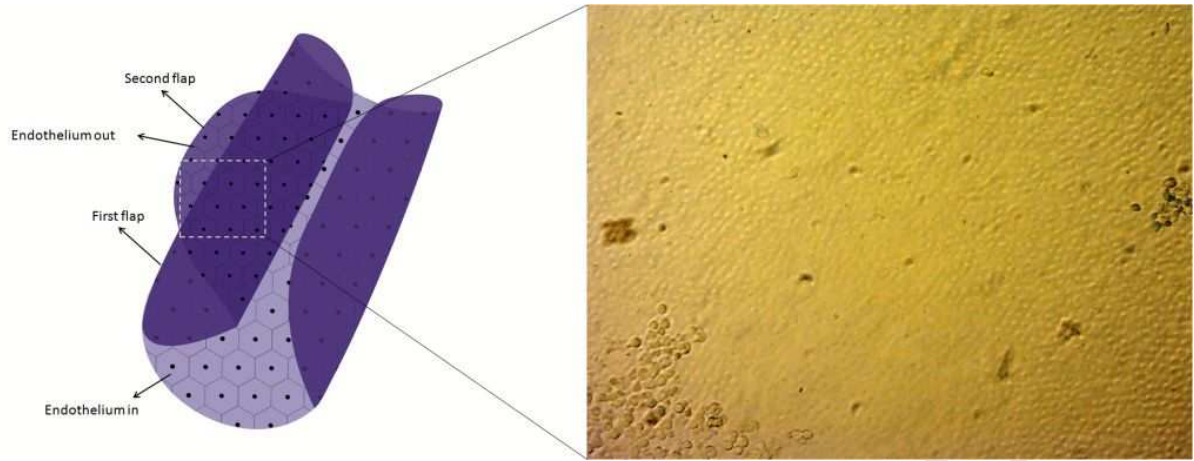
ACCEPTED MANUSCRIPT



ACCEPTED MANUSCRIPT



ACCEPTED MANUSCRIPT



ACCEPTED MANUSCRIPT